

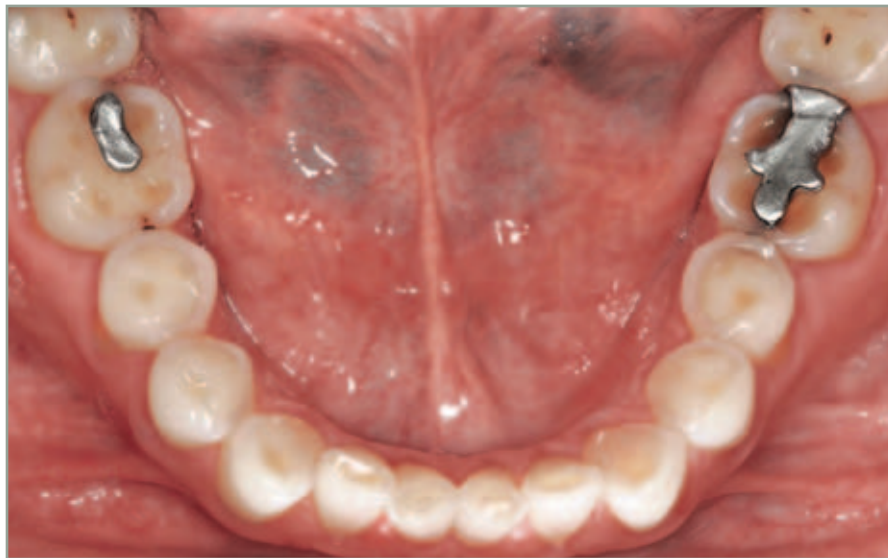

Full-Mouth Adhesive Rehabilitation of a Severely Eroded Dentition: The Three-Step Technique. Part 2.

Francesca Vailati, MD, DMD, MSc

Senior Lecturer, Dept of Fixed Prosthodontics and Occlusion
School of Dental Medicine, University of Geneva
Switzerland

Urs Christoph Belser, DMD, Prof Dr med dent

Chairman, Dept of Fixed Prosthodontics and Occlusion
School of Dental Medicine, University of Geneva
Switzerland



Correspondence to: Dr Francesca Vailati

University of Geneva, Dept of Fixed Prosthodontics and Occlusion, Rue Bathelemy-Menn 19, 1203 Geneva, Switzerland;
e-mail: Francesca.vailati@medecine.unige.ch.



Abstract

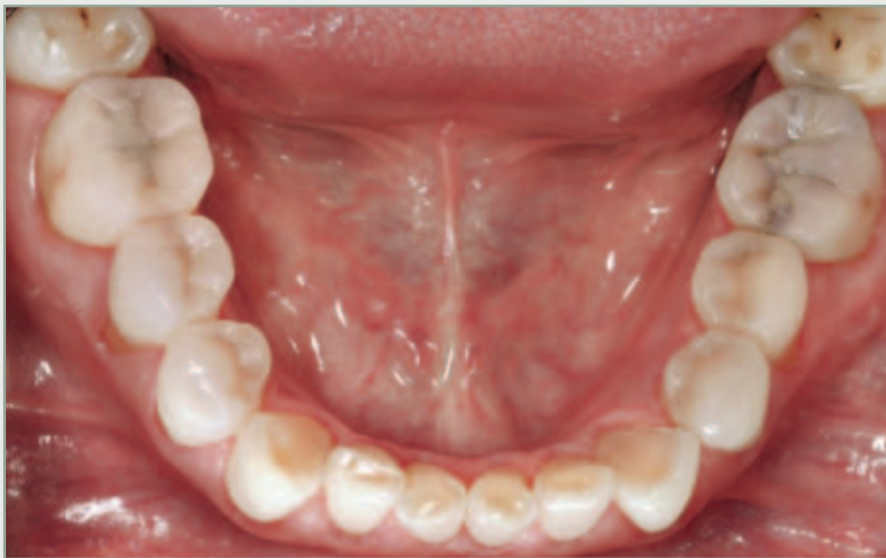Traditionally, a full-mouth rehabilitation based on full-crown coverage has been recommended treatment for patients affected by severe dental erosion. Nowadays, thanks to improved adhesive techniques, the indications for crowns have decreased and a more conservative approach may be proposed.

Even though adhesive treatments simplify both the clinical and laboratory procedures, restoring such patients still remains a challenge due to the great amount of tooth destruction. To facilitate the clinician's task during the planning and execution of a full-mouth adhesive rehabilitation, an innovative concept has been developed: the three-step technique. Three laboratory steps are alternated with three clinical steps, allowing the clinician and the laboratory technician to constantly interact to

achieve the most predictable esthetic and functional outcome. During the first step, an esthetic evaluation is performed to establish the position of the plane of occlusion. In the second step, the patient's posterior quadrants are restored at an increased vertical dimension. Finally, the third step reestablishes the anterior guidance. Using the three-step technique, the clinician can transform a full-mouth rehabilitation into a rehabilitation for individual quadrants.

The present article focuses on the second step, explaining all the laboratory and clinical steps necessary to restore the posterior quadrants with a defined occlusal scheme at an increased vertical dimension. A brief summary of the first step is also included.

(Eur J Esthet Dent 2008;3:128–146.)



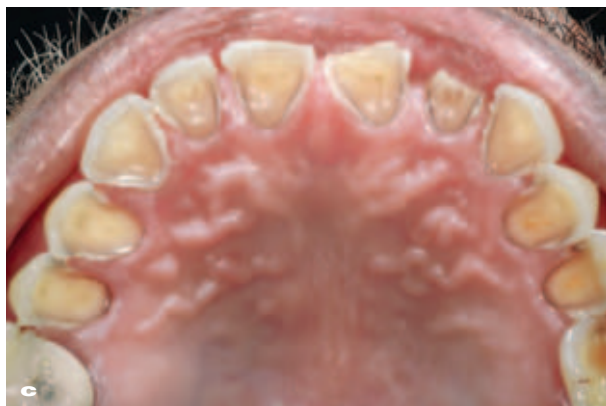
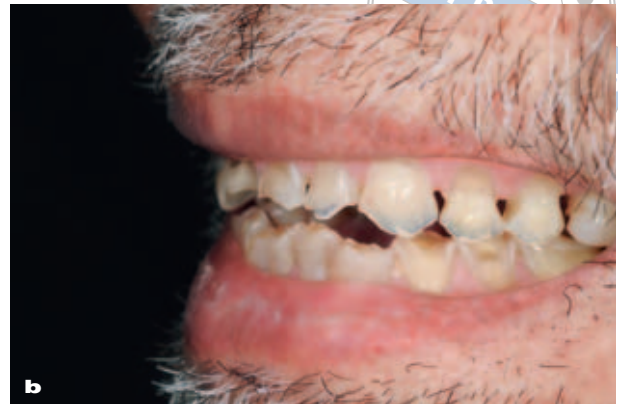
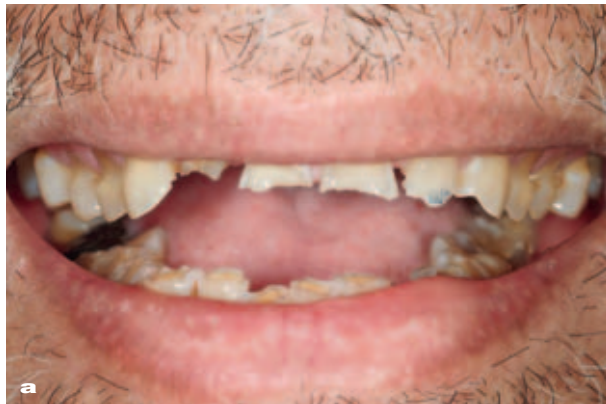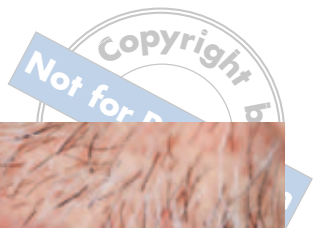Fig 1 (a to c) Clinical views of a 60-year-old patient affected by generalized dental erosion. For years the patient suffered from gastric esophageal reflux. At this late stage a full-mouth rehabilitation is inevitable. Despite the advanced loss of tooth structure, all teeth are still vital.

Traditionally, a full-mouth rehabilitation has been the recommended treatment for patients affected by generalized severe dental erosion. However, a restorative concept comprising full-crown coverage of almost all teeth and extensive elective root canal treatment may be too aggressive for this generally very young population of patients.¹⁻³ With current improved adhesive techniques, the indications for crowns have decreased and a more conservative approach may be proposed, to preserve tooth structure and to postpone more invasive treatments until the patient is older.⁴⁻⁸



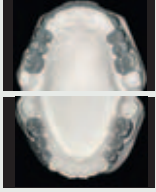



In order to test the hypothesis that such a concept can predictably reach the specific treatment objectives, a clinical trial testing a fully adhesive approach is underway at the

University of Geneva. All patients affected by generalized advanced dental erosion are systematically and exclusively treated with adhesive techniques, using onlays for the posterior region and a combination of facial bonded porcelain restorations (BPRs) and palatal composite restorations for the anterior maxillary region. The goal of this prospective clinical study is to evaluate the longevity of adhesive rehabilitations, before proposing this treatment option as the new standard of care.

Despite the tendency for adhesive modalities to rather simplify the involved clinical and laboratory procedures, treatment of such patients still remains a challenge because of the significant amount of tooth destruction (Fig 1).



Table 1 The three-step technique

Laboratory			Clinical	
	Maxillary vestibular waxup	Step 1: Esthetics	Assessment of occlusal plane	
	Posterior occlusal waxup	Step 2: Posterior support	Creation of posterior occlusion at an increased VDO	
	Maxillary anterior palatal onlays	Step 3: Anterior guidance	Reestablishment of final anterior guidance	

To facilitate the clinician’s task during the planning and execution of a full-mouth adhesive rehabilitation, a structured, innovative concept has been developed: the three-step technique (Table 1). Three laboratory steps are alternated by three distinct clinical steps, allowing the clinician and the laboratory technician to constantly interact and thus to achieve the most predictable esthetic and functional outcome.

The first step of the concept has been previously described in detail.⁹ The present article focuses on the second step, explaining all the laboratory and clinical steps necessary to restore the posterior quadrants with a defined occlusal scheme at an increased vertical dimension. A brief summary of the first step is also included.

Full-mouth waxup: a crucial or arbitrary tool in the determination of the plane of occlusion?

Patients affected by severe dental erosion often present with an extremely damaged dentition, not infrequently making clinicians hesitate to undertake such an ex-

tended rehabilitation. Traditionally, one of the first steps consists of providing the laboratory technician with diagnostic casts, and requesting a full-mouth waxup. A full-mouth waxup should guide the clinician in planning the treatment so that the most esthetic and functional result is achieved by respecting the principle of minimal invasiveness, ie, minimal tooth preparation. Clinicians should realize, however, that technicians will often arbitrarily decide on numerous important dental parameters (eg, occlusal plane, incisal edge position) without seeing the patients, and with an often misleading lack of reference points (eg, adjacent teeth). The fact that the resulting final rehabilitations often do not reflect the initial full-mouth waxups confirms this statement.

In the authors’ opinion, the most misjudged parameter in a full-mouth waxup is the position of the occlusal plane. In case of a full-mouth rehabilitation at an increased vertical dimension of occlusion (VDO), the gained interocclusal space is generally shared equally between the



mandibular and the maxillary posterior teeth, to minimize tooth preparation in both arches. However, such a decision is completely arbitrary, and the repositioning of the occlusal plane at a lower level than the original may lead to a compromised esthetic result. In order to achieve an optimal esthetic outcome, both the maxillary incisal edges and the occlusal plane should be in harmony. In a frontal, smiling view, the vestibular cusps of the maxillary posterior teeth should follow the lower lip and be located more cervically than the incisal edges of the anterior dentition. Otherwise, an unpleasant, “reverse” smile is generated. Thus, to determine the correct distribution of the interocclusal space gained by the increase of VDO, it is mandatory to determine first the optimal position of the maxillary incisal edges of the planned final restorations.

In patients where the maxillary anterior teeth cannot be lengthened sufficiently on their incisal aspect to compensate for an excessively low occlusal plane, all the space obtained has to be used exclusively for the restoration of the mandibular posterior teeth, which in turn will require a more aggressive tooth preparation of the maxillary posterior teeth.

Advanced generalized dental erosion frequently leads to supraeruption of both the maxillary posterior sextants and the mandibular anterior segment, causing a so-called reverse smile (Fig 2). Logically, in these patients, the position of the occlusal plane cannot be further lowered, unless there is certitude that the incisal edges of the maxillary anterior teeth will be sufficiently lengthened to correct the reverse smile. An additional problem inherent to this particular type of patient is that they are used to perceiving themselves with “smaller”

teeth. As a consequence, not all of them will readily accept having their anterior teeth restored with added incisal volume. Hence communication with the patient becomes of paramount importance to avoid esthetic misunderstandings.

Before starting the full-mouth rehabilitation, it is recommended to determine to what extent the patient will accept a lengthening of the anterior maxillary teeth, so that the final esthetic outcome will be well defined and the required amount of preparation of the maxillary posterior teeth can be accurately planned.

Step 1: Laboratory and clinic

The first step of the three-step technique is conceived to guarantee that both the clinician’s and the laboratory technician’s vision of the planned restoration is a reflection of the patient’s true desires. With the introduction of the first clinical step, the technician will not complete a potentially incorrect full-mouth waxup. In fact, the first laboratory step proposes to wax up only the vestibular surfaces of the maxillary teeth. At this stage, where much of the relevant information is still missing, it is not advisable to invest time in a more comprehensive waxup.

Subsequently, the information represented by the maxillary vestibular waxup will be picked up by means of a precise silicone key (Fig 3).

The patient is then scheduled for a clinical appointment where a maxillary vestibular mockup is directly fabricated in the mouth (first clinical step). The clinician will load the silicone key with a tooth-colored autopolymerizing resin composite material and position in the patient’s mouth. After its removal, all vestibular surfaces of the maxillary teeth will be covered by a thin layer of

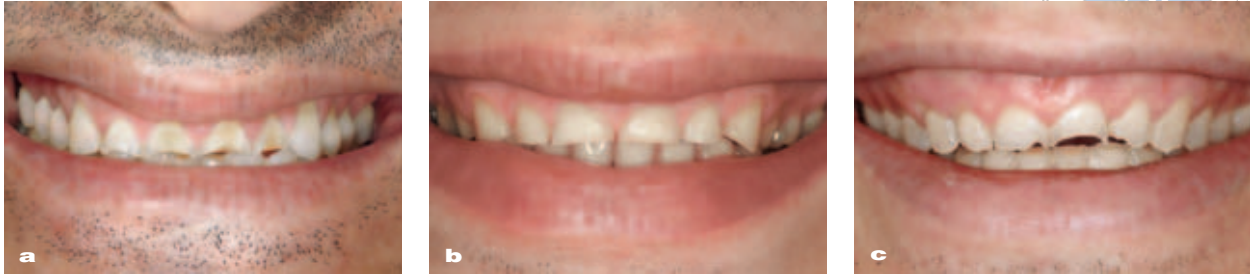
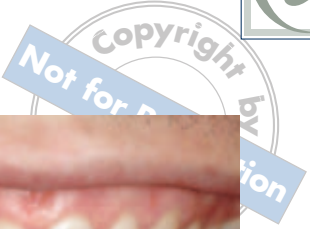
Fig 2 (a to c) An unpleasant reverse smile is present when the position of the incisal edges of the maxillary anterior dentition is more cervical than the occlusal plane, as apparent in these three patients affected by severe dental erosion.

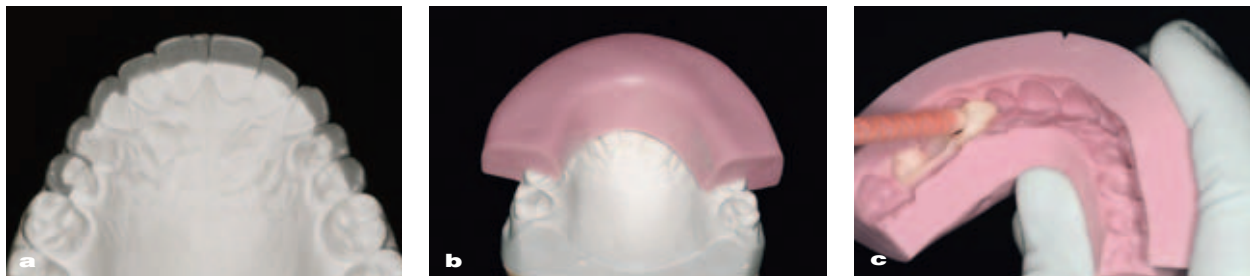

Fig 3 (a to c) *First laboratory step:* Maxillary vestibular waxup. The technician is instructed to wax up only the vestibular aspect of the maxillary teeth. Neither the cingula nor the palatal cusps of the maxillary posterior teeth are included at this stage. A silicone key is then fabricated and will subsequently be loaded with tooth-colored resin composite material and repositioned in the patient's mouth for the fabrication of a maxillary mockup.

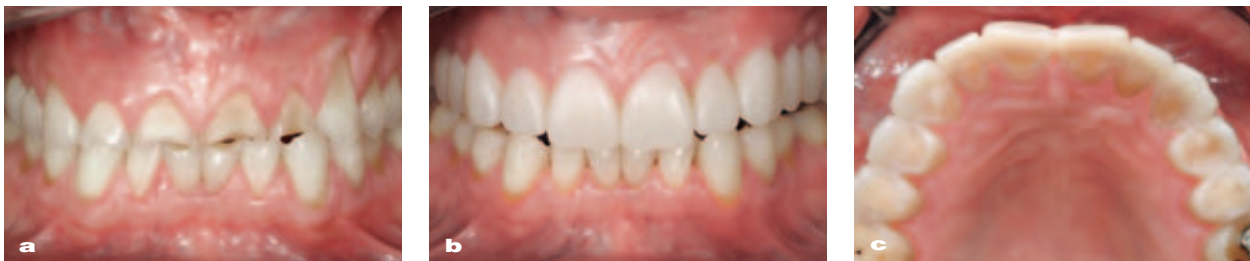

Fig 4 *First clinical step:* Maxillary vestibular mockup. Clinical views before **(a)** and after **(b and c)** completion of the diagnostic mockup. Mucogingival surgery was performed to cover the marked gingival recessions on the maxillary left canine and premolars. Note that the mockup covers only the incisal edges and the vestibular cusps of the maxillary teeth.

composite, reproducing the shape defined for the future restorations by the laboratory technician.

The described, fully reversible reconstruction of the vestibular cusps of the maxillary posterior teeth and the incisal edges of the anterior teeth allows visualization of

the future plane of occlusion. Additional information is also obtained, as explained in a previous article,⁹ most importantly the patient's consensus regarding the planned final esthetic outcome (Figs 4 and 5).

After completion of the first step, either formal acceptance by the patient is ob-

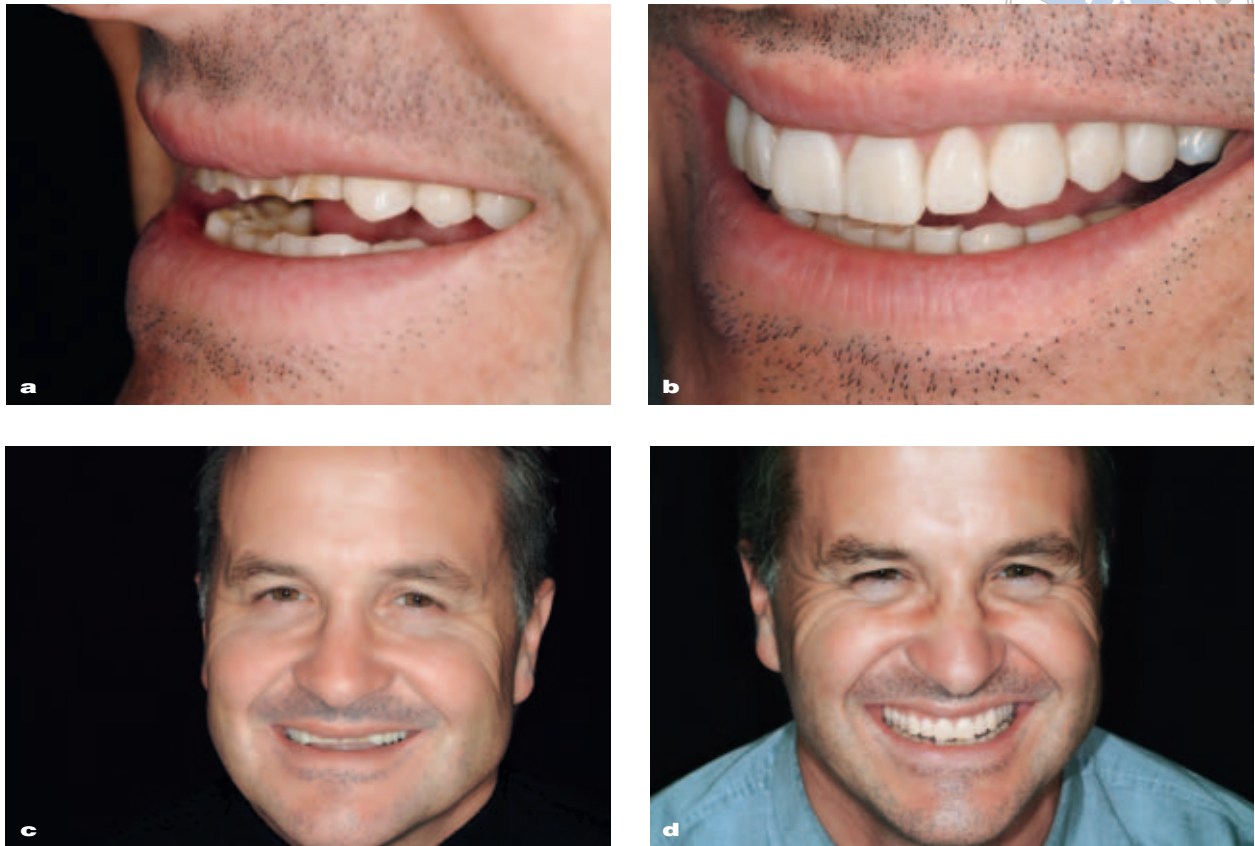

Fig 5 (a to d) These photographs present the same patient as shown in Fig 4. Owing to the maxillary vestibular mockup (b), the orientation of the future occlusal plane can be visualized, and the esthetic direction taken by the technician agreed with the patient. Generally, patients appreciate the planned treatment objective being presented to them so clearly at an early stage and before any irreversible measures have been taken.

tained, or new guidelines for changes are forwarded to the technician, who can then progress with the complete waxup of the posterior quadrants. Before continuing any further with the three-step technique, it is important to address two topics specifically, which in the case of a full-mouth rehabilitation are still controversial: centric relation and vertical dimension of occlusion.

Centric relation: centric occlusion dilemma

In the presence of generalized advanced dental erosion, which often significantly affects occlusal morphology in the posterior

segments of the dentition as well as anterior guidance, the clinician faces the dilemma whether to restore the patient in centric relation (CR) or in maximum intercuspation position (MIP). According to numerous classic articles published in the field of Gnathology,¹⁰⁻¹² CR is recommended as the only acceptable position when it comes to full-mouth rehabilitations, since it is considered the only reproducible one. This concept was developed for conventional full-mouth rehabilitations, when all the teeth were going to be restored by means of full coverage (crowns or fixed dental prostheses) and when working ex-

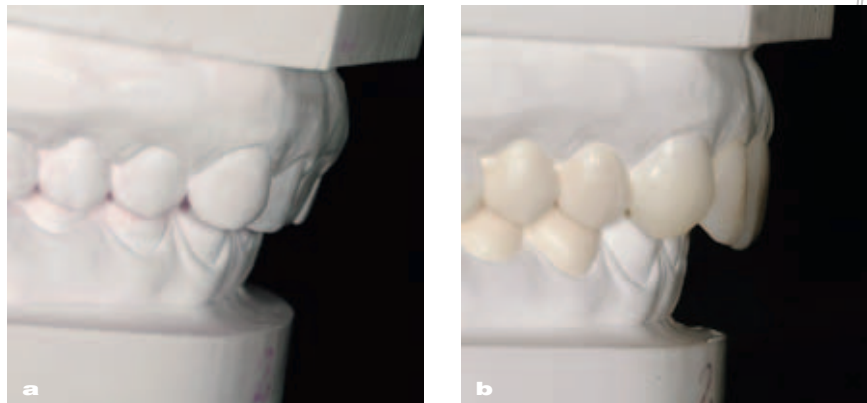


Fig 6 Mounted study casts of a same patient articulated in MIP **(a)** and in CR **(b)**, after a complete full mouth waxup. While the CR position can be desirable in patients with class III molar occlusion, in patients with a class II, as for this particular patient, it poses an occlusal dilemma. The future restorations on the anterior teeth would never be in contact (no anterior guidance) unless unnatural oversized cingula were created. Note the excessive horizontal overlap **(b)** generated by the combination of the CR position and the increase of VDO.

tensively on both arches at the same time had an elevated risk of losing all intermaxillary reference points. An additional argument for CR was that patients treated under extended local anesthesia were unable to collaborate during the occlusal adjustments.

Currently, there is an increasing trend towards minimizing the necessity for complicated, time-consuming clinical procedures on the one hand, and reducing the number of full crown restorations on the other hand, particularly when treating young patients. Consequently, the new clinical approach (full-mouth adhesive rehabilitation) for the treatment of advanced generalized erosion consists exclusively of posterior onlays and anterior BPRs, and is strategically planned in a way that allows rehabilitation of patients quadrant-wise instead of by restoring both dental arches simultaneously.

In a dynamic rehabilitation process, where two key parameters of a functional

occlusion, ie, VDO and interarch relation, are constantly maintained by the contralateral side of the mouth, using CR as a landmark reference of occlusion may not be so crucial. Furthermore, in cases of severe dental erosion, the palatal aspect of the maxillary teeth is often compromised; after the enamel is lost, the exposed dentin is subject to accelerated wear, which leads to a pronounced concave morphology and not infrequently to weakening and fracture of the incisal edges.

To stop the progression of the described tooth destruction (erosion and attrition), the exposed remaining dentin should be efficiently protected. Due to the supraeruption of the anterior quadrants, an increase of VDO is mandatory to restore the original tooth form. However, in patients with class II molar occlusion, the combination of increased VDO and CR position may set the anterior teeth significantly apart and this can lead to an absence of anterior guidance.



Since it is not recommended to substantially increase the incisal length of the mandibular anterior teeth (generally supererupted in cases of advanced generalized dental erosion), anterior contacts can logically only be re-established by increasing the size of the maxillary cingula. In fact, several of the patients affected by severe generalized erosion treated at our clinic presented a class II molar occlusion with a major discrepancy between MIP and CR. Thus it was preferred to restore their occlusion in MIP and to establish anterior contacts without the necessity of creating oversized maxillary cingula (Fig 6).

Furthermore, to evaluate if under the previously described conditions and strictly following the three-step technique the use of CR as the interarch relationship of reference is not a prerequisite, the decision was made to restore all the patients affected by severe erosion in MIP. From the preliminary data collected so far, no significant adverse effects have been encountered that would question the choice of using MIP.

The “increased VDO” dilemma: how much and how to test?

In patients affected by severe generalized erosion, the question of whether VDO has eventually decreased during this pathological process is difficult to answer, as several compensatory mechanisms, eg, supereruption of the alveolar process, may have occurred. It is also clinically quite irrelevant.

An increase of VDO is always mandatory, in order to reduce the need for substantial tooth preparation and to avoid the necessity of elective endodontic treatments. However, any increase of VDO should be minimal so it is tolerated by the patient, and guarantees at the end of the rehabilitation the preservation or re-establishment of

functional anterior interarch contacts required for anterior guidance. Furthermore, the new VDO should always be tested clinically, before irreversible treatments begin, since it is selected arbitrarily on the articulator.

In this context, a traditional and fully reversible approach consists of the use of an occlusal guard, which requires compliance of the patient. However, considering the active lifestyle of most people, it is rather naïve to expect that patients will wear such an occlusal guard 24 hours a day for several months. A more realistic approach may be the use of interim restorations. In the case of adhesive rehabilitation, the dental technician could fabricate provisional composite onlays, which would subsequently be bonded to the teeth, including the palatal aspects of the maxillary anterior dentition. There are several disadvantages to this method, such as the associated additional lab fees. Furthermore, it may in many instances not be a truly reversible approach, since it could require some tooth preparation to assure minimal thickness of the onlays.

The third possibility for clinical testing of the feasibility of an arbitrarily chosen increase of VDO is the use of direct composites. However, free-hand direct composites are very time consuming, particularly if the clinician aims to duplicate exactly the occlusal scheme determined by waxup on the mounted study casts.

It should be repeated that not only the posterior, but also the anterior teeth should be involved in the treatment in order to increase the VDO and to recreate adequate anterior guidance. The respective result may be disappointing, especially if the clinician expects to position the mandible in CR and to establish simultaneously stable

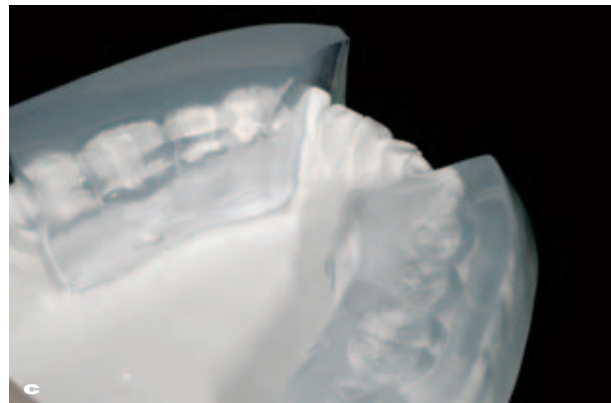
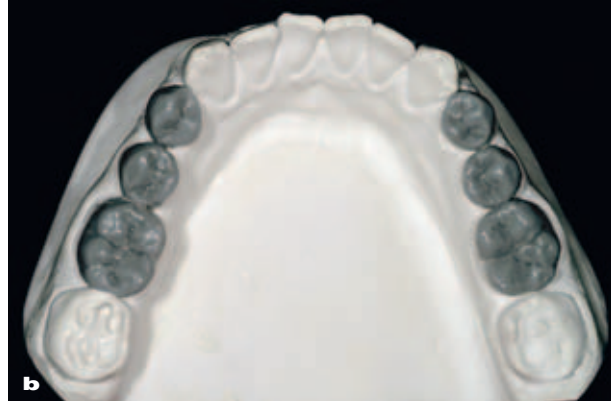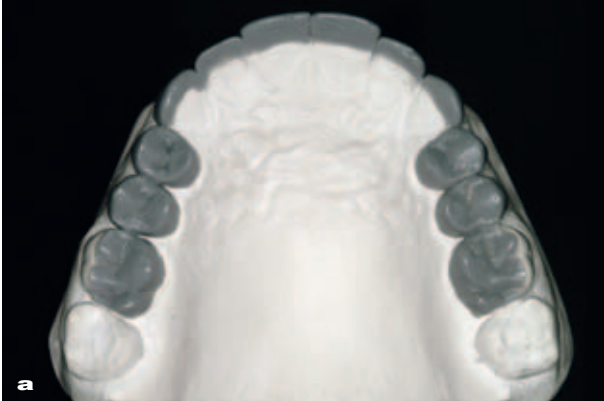


Fig 7 (a to c) *Second laboratory step: Posterior occlusal waxup.* The laboratory technician waxes only the occlusal surfaces of the premolars and the first molars in each posterior quadrant of the maxillary and mandibular casts. Based on this waxup, four independent translucent silicone keys will be fabricated.

occlusal contacts at the identical VDO that had been previously selected on the articulator, a task that is generally considered almost impossible.

All the three of the above techniques that have been proposed to test an increase of VDO have some major drawbacks. The dilemma of how to transfer efficiently and correctly the new occlusion defined with the waxup remains. As a consequence, the second step of the three-step technique proposes an easy and reversible approach to establish a new posterior support and to test the adaptation of the patient to this new VDO. This approach, combining the advantages of the abovementioned techniques, allows fabrication of a “fixed” occlusal guard, made of

splinted composite onlays, directly fabricated in the mouth.

Step 2: Laboratory – posterior occlusal waxup

At the beginning of the treatment, the two maxillary and mandibular casts are mounted on a semi-adjustable articulator with a facebow in MIP. During the first step, the technician performed a vestibular waxup on the maxillary cast, and the position of the plane of occlusion was subsequently validated clinically.

For each patient, the new VDO is decided arbitrarily on the articulator, taking into consideration the posterior teeth, where the maximum increase is desirable to maintain a maximum of mineralized tissue, and the

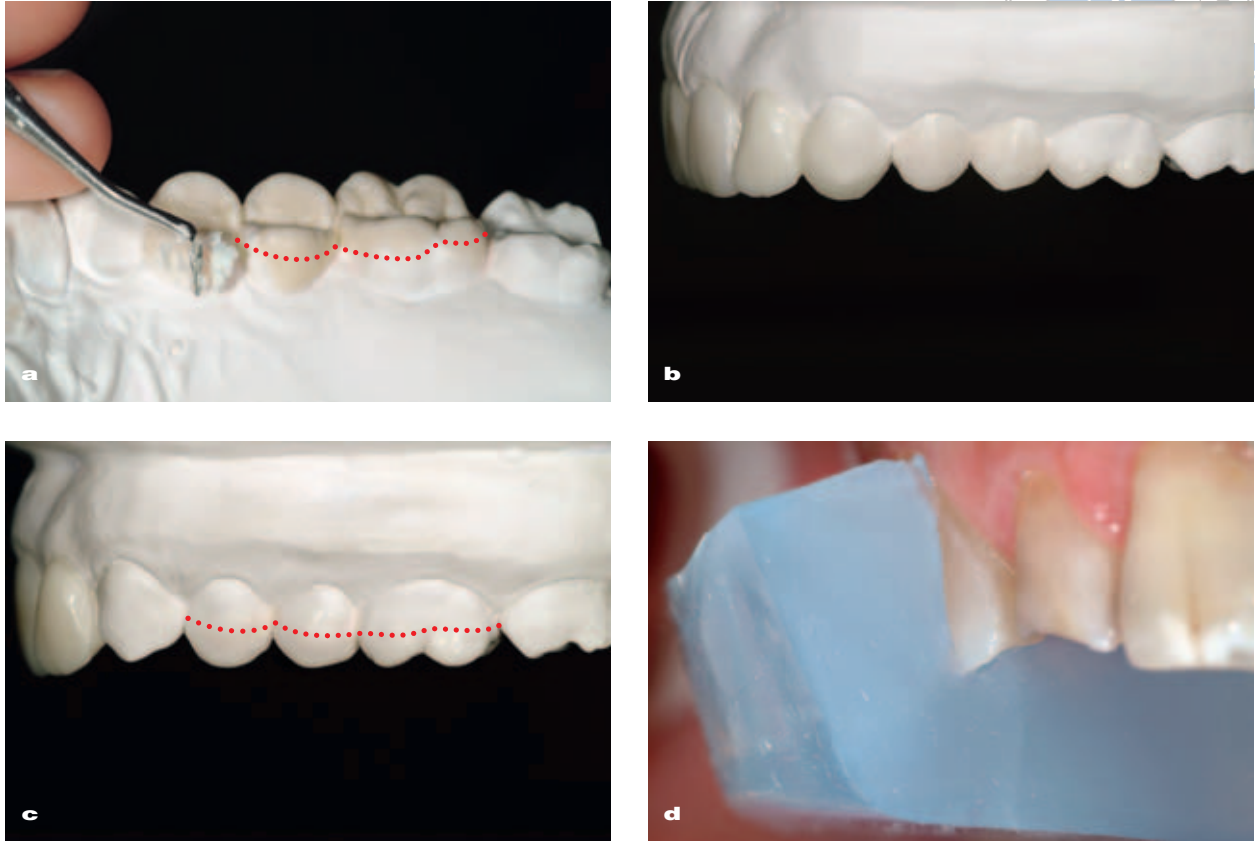


Fig 8 (a to d) Waxup modifications before the fabrication of the translucent silicone keys. It is necessary to remove the wax from the maxillary canines, so that the key will better be adapted in the patient's mouth (canine as a mesial stop).

anterior teeth, which should not be set too far apart to jeopardize the recreation of anterior contacts and the related anterior guidance. Once the increase of the VDO is established and the plane of occlusion validated, it is easy for the technician to wax up completely the occlusal surfaces of the posterior teeth.

The second laboratory step, however, proposes only to wax up the occlusal surfaces of the two premolars and the first molar in each sextant (Fig 7). The palatal aspect of the maxillary canines may also be waxed at this stage to better select the cusp shape and inclination in relation to the occlusal scheme selected (eg, canine guid-

ance or group function). In more complex cases (shallow future anterior guidance), the technician may be obligated to wax up all the cingula of the maxillary anterior teeth as well, to verify the disclusion of the posterior quadrants in protrusion. Generally, there is no need to wax up the mandibular anterior teeth, since they are often only minimally affected by the erosion.

At completion of the posterior occlusal waxup, the technician will fabricate for each quadrant one key, made of translucent silicone (Elite Transparent, Zhermack). These keys will be used in the second clinical step intraorally to fabricate direct composites, reproducing the waxup very closely.

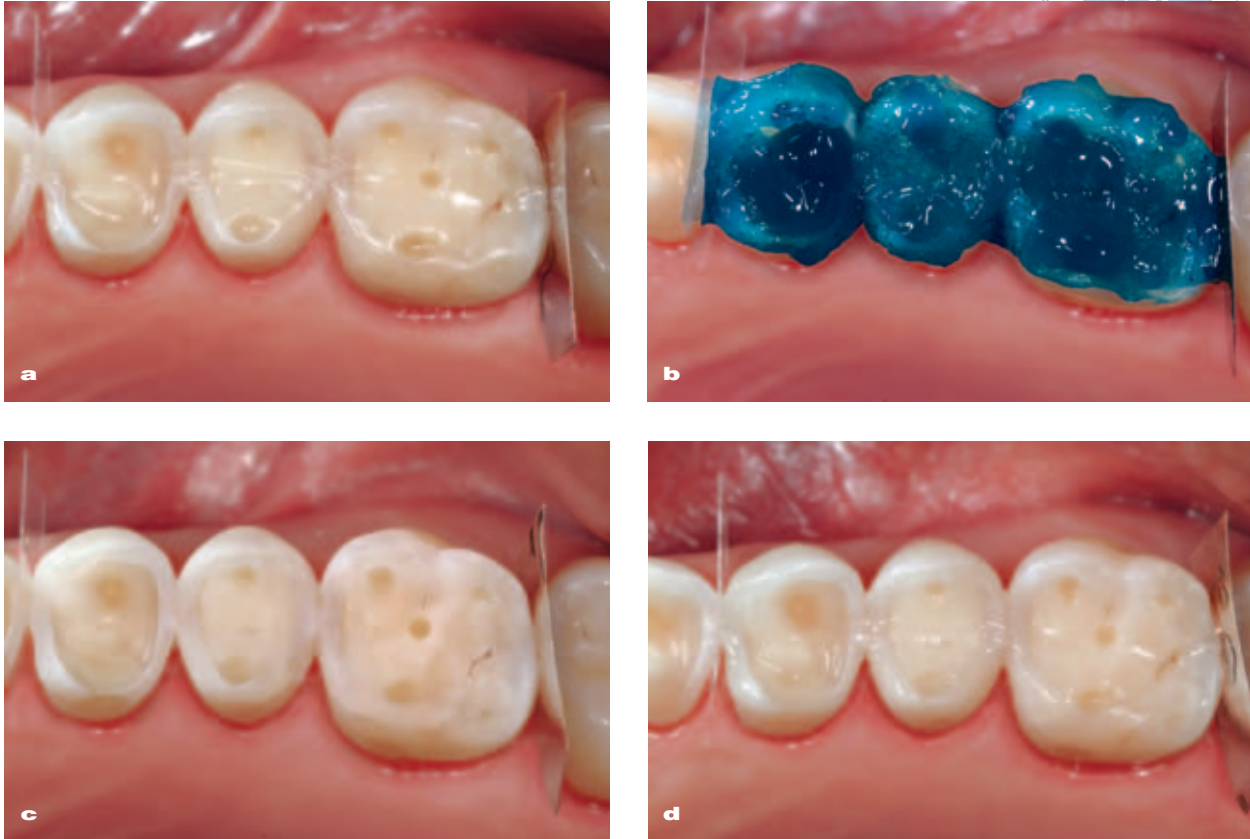
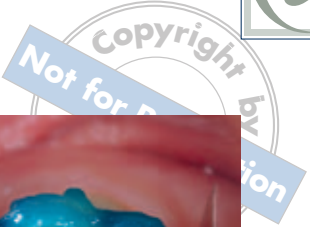
Fig 9 (a to d) Intraoral preparation of a posterior maxillary sextant for a direct bonding procedure: The two premolars and the first molars for each posterior quadrant are etched, and priming and bonding agents are applied. Care is taken to isolate the adjacent teeth with matrices.

Some modifications of the waxup are subsequently carried out to facilitate the next clinical step, before producing the keys (Fig 8):

- The wax is carefully removed from the buccal and the lingual surfaces of the posterior teeth of the casts, so that in turn each key will be in close contact to the cervical aspect of the teeth in the patient's mouth. As a consequence, less excess resin composite may flow into the gingival sulcus and fewer intraoral adjustments will be necessary.
- The wax should also be removed, if present, from the canines, since they will serve as a mesial stop to stabilize the key intraorally.

Step 2: Clinical – posterior interim composites

The second clinical step basically consists of the fabrication of posterior composite onlays, directly performed in the patient's mouth, thanks to the special transparent keys duplicating the occlusal waxup.

The two premolars and the first molars of each quadrant are acid-etched, followed by application of primer and bond (Opti-bond FL, Kerr) (Fig 9). In the authors' experience, even in cases of severe exposure of dentin, there is no need to anesthetize the patient before applying the etching agent.

The clinician will then load each translucent key with composite, position it in the

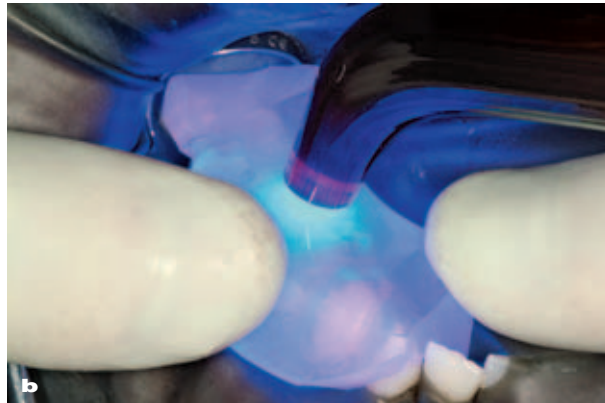
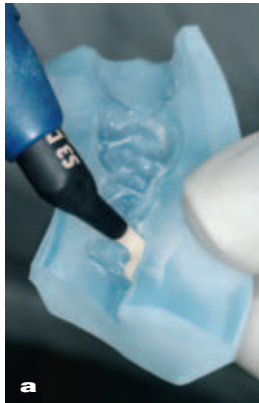
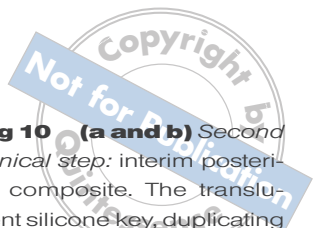
Fig 10 (a and b) Second clinical step: interim posterior composite. The translucent silicone key, duplicating the occlusal waxup, is loaded with resin composite and positioned in the mouth. The key is well stabilized by the canine and the second molar (mesial and distal stops). Owing to the translucency of the silicone, the composite can be polymerized through the key.

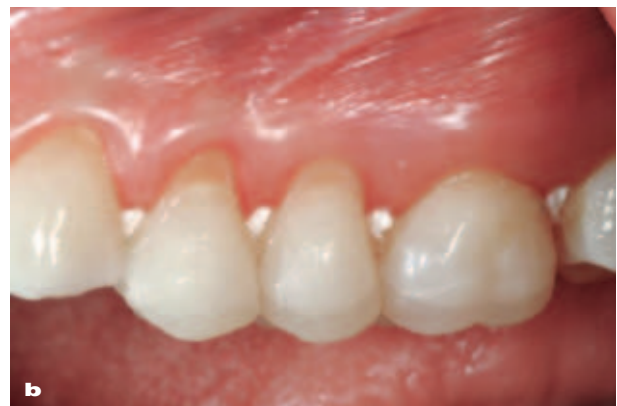
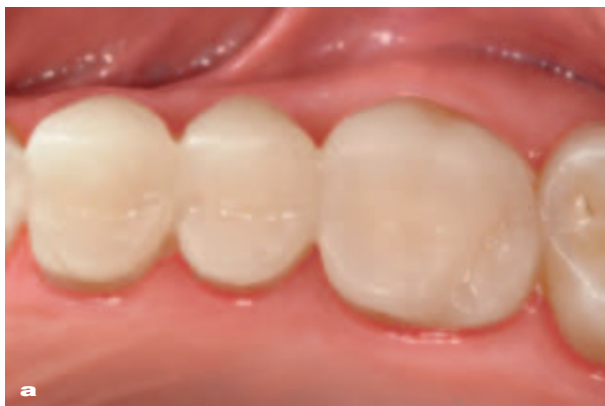
Fig 11 (a and b) The posterior provisional resin composite is easily and quickly fabricated, with minimal excess requiring removal. A composite shade that is slightly different from the remaining dentition should be selected to facilitate the future removal of these provisional restorations. Note that in this patient the clinician has filled the interproximal spaces with teflon to reduce excess resin composite in the embrasures.

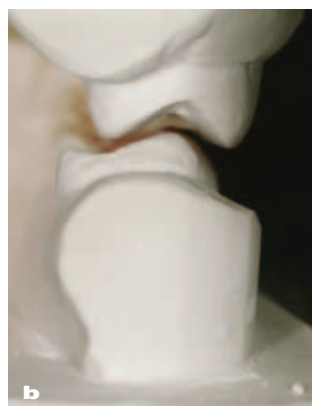
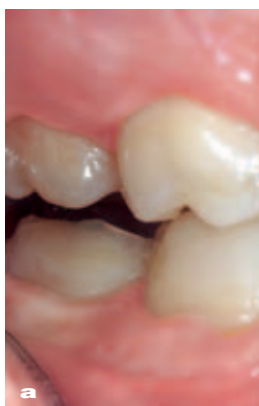
Fig 12 (a and b) Since the second molars are not restored with interim resin composite, they serve as valuable indication of the increase of VDO, once the respective casts are articulated.

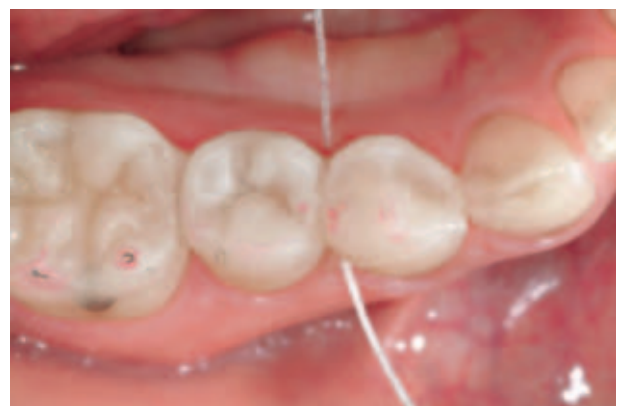

Fig 13 Even though the occlusal access to the interproximal areas is blocked by the splinted posterior interim composites, the gingival embrasures are still open to allow cleaning with Superfloss.



patient's mouth, and polymerize the composite through the key (Fig 10). Since the keys, made of translucent silicone, are not as rigid as desired, it is crucial not to use too viscous a resin composite (such as Tetric EvoCeram, Ivoclar Vivadent), or to load the key excessively. To avoid distortion, the composite should be pre-warmed, and a minimal quantity of material should be placed in the key, just enough for the new volume of the occlusal surfaces.

At this stage, the second molars are not included in the occlusal waxup, nor will they be restored with a provisional occlusal composite due to the following reasons (Fig 12):

- to assure the presence of a stable distal occlusal stop for accurate positioning of the translucent keys during the fabrication of the posterior interim composites
- to acknowledge the fact that three posterior teeth are considered sufficient to establish stable posterior support in each sextant
- to have a reference indicating the amount of increase of VDO.

Implementation of this technique includes splinting the three posterior teeth involved, thus blocking the occlusal access of two interproximal contacts areas and preventing the use of dental floss. Adequate oral hygiene, however, is possible since the gingival embrasures are kept open and Superfloss can be used with a lateral path of insertion (Fig 13).

As stated above, the original models of the patient are mounted in MIP and the increase in VDO is decided on the articulator. Despite the fact that the articulator's hinge axis is going to be different from the patient's, in our experience it does not generate sufficiently different occlusal contacts on the composite resin to require the mounting of the casts in CR.

Minor occlusal adjustments should be expected by implementing this technique, but normally, if the waxup is correctly performed, and the keys accurately fabricated and positioned in the mouth, the time required for the adjustment is limited (Fig 14). In addition, since there is normally no need to anesthetize the patient, control of the oc-

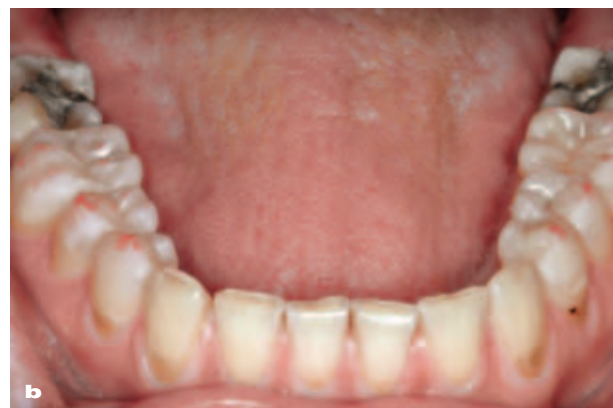
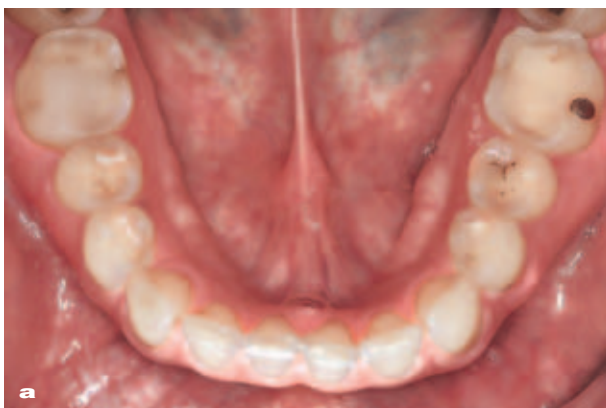
Fig 14 (a and b) A different patient, before and after the second step of the three-step technique. Minimal occlusal adjustments are expected if the previous steps are performed correctly (eg, posterior occlusal waxup, translucent key fabrication, loading of the keys). Note that the composites do not extend to the cervical third of the teeth, thanks to the respective modifications of the waxup before the key fabrication. The resulting visible transition step can be smoothed with a polishing rubber wheel.

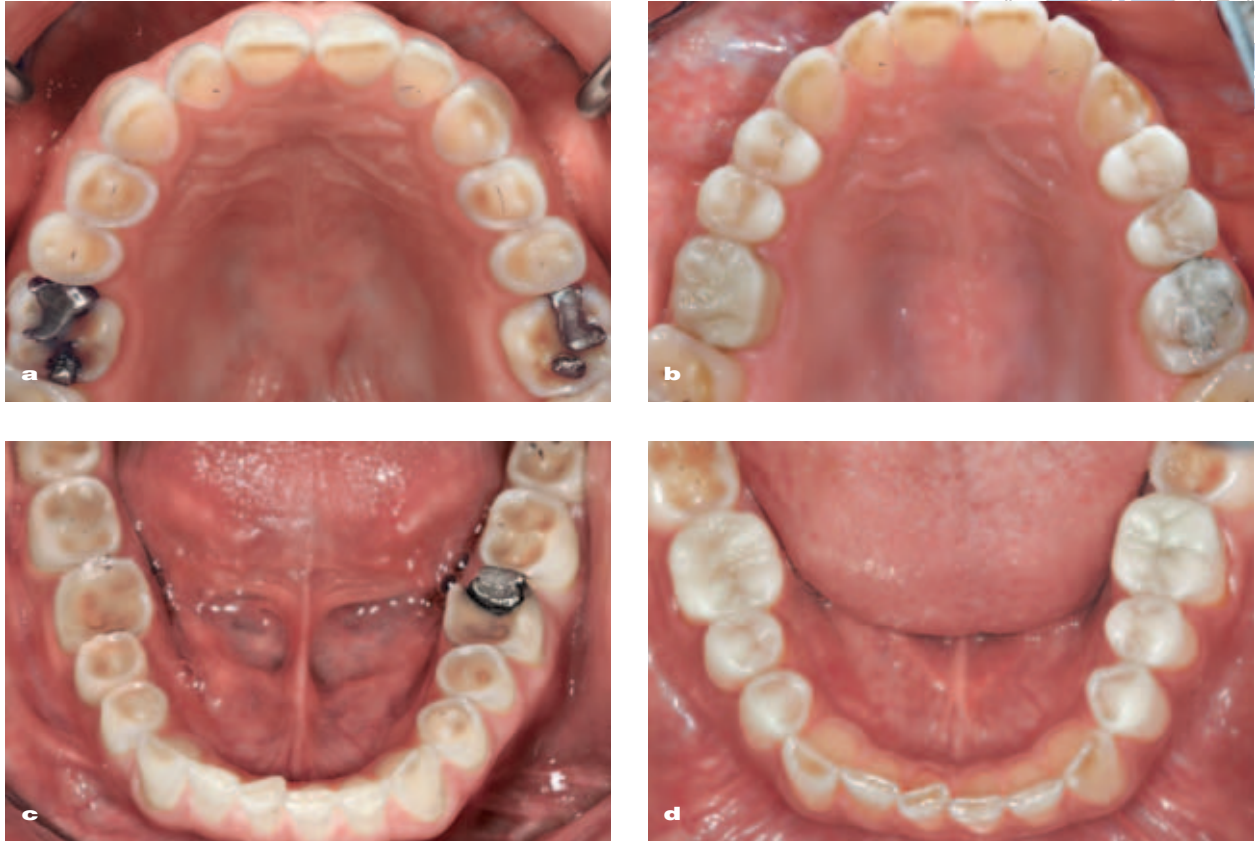
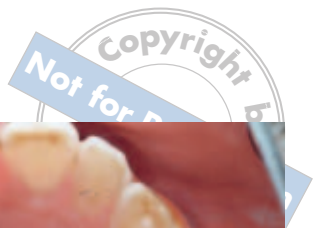

Fig 15 (a to d) A 29-year-old patient before and after the second clinical step of the three-step technique. Even in cases of extensive dentine exposure, dental anesthesia is not required during this step.

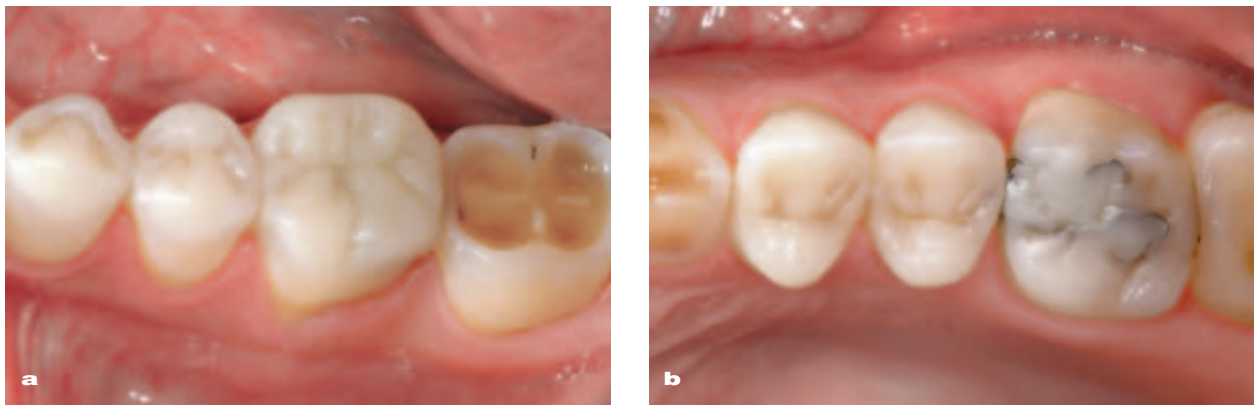


Fig 16 (a and b) Close-up view of the previous patient. Existing amalgam restorations can be removed (tooth 36) or left in place and covered with the interim resin composite (tooth 26).



clusion will be facilitated and consequently more accurate.

This “fixed” occlusal guard has the major advantage that the compliance of the patient is 100% in terms of testing the increased VDO. Since no tooth preparation is requested for the fabrication of the posterior occlusal composites, the treatment can be considered completely reversible; if signs and/or symptoms of temporomandibular dysfunction arise, the initial status could be re-established by grinding off the occlusal composites. These composite onlays are meant to be provisional, and they will be replaced (with final composite or ceramic onlays) after the anterior quadrants are definitely restored (step 3 of the three-step technique) (Fig 15). This is one of the reasons that the use of rubber dam is not vital during this particular step, and the removal of existing functioning restorations (eg, old amalgam restorations) is not strictly required.

Another advantage of these interim composites is their potential for modification. After, for example, completion of the restoration of the maxillary anterior teeth, it is still possible to adjust the position of the occlusal plane with respect to the new in-

isal edge position, by modifying the vestibular cusps of the posterior provisional composites. Finally, their presence will facilitate the occlusal adjustments of the final restorations placed in the opposite quadrant. The laboratory technician could decide to fabricate the latter to the perfect form and all the occlusal adjustments could be carried out on the opposite provisional posterior composites.

The second clinical step has been conceived to simplify the clinician’s work, without compromising the final outcome of the full mouth rehabilitation.

In this case, it was decided not to attempt to restore the anterior teeth with provisional resin composite. In the authors’ experience the increase of VDO is well tolerated (because minimal) by the patients even when an anterior open bite is created temporarily. Some speech impairments could be anticipated. However, patients informed before treatment usually deal very well with this problem (Figs 17 to 19).

Currently, there is no consensus of the time necessary to test the comfort of the patient with respect to a new, increased VDO, and each clinician appears to decide based on personal opinion rather than on

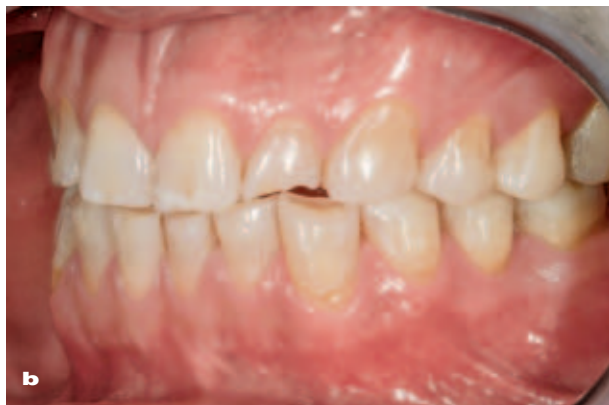
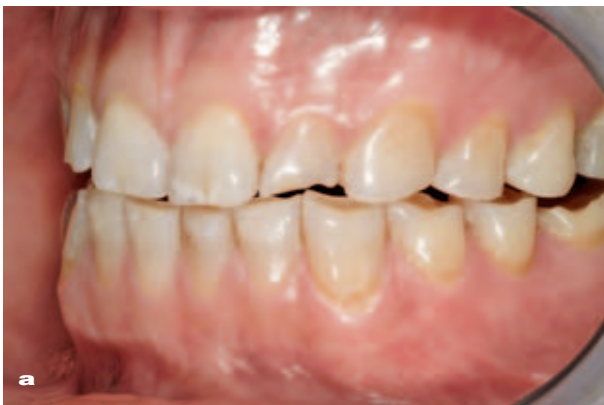
Fig 17 (a and b) Same patient as shown in Fig 12. After completion of the second clinical step the patient is restored at an increased VDO **(b)**. Note the slight anterior open bite that has been generated.

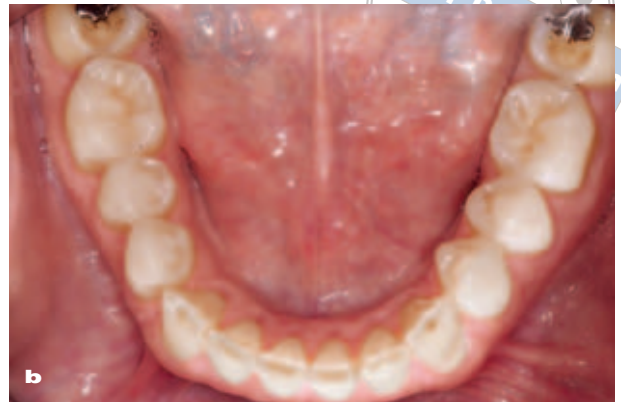
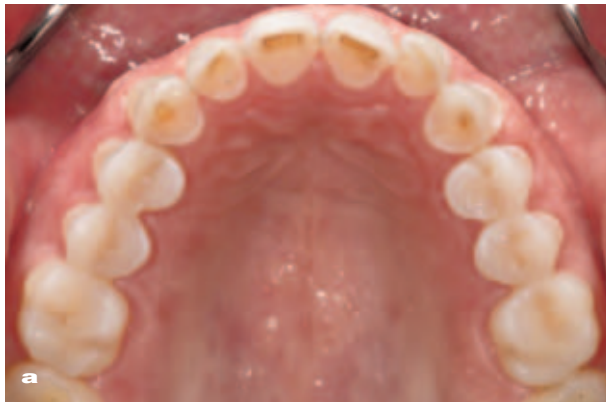
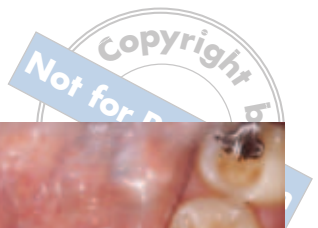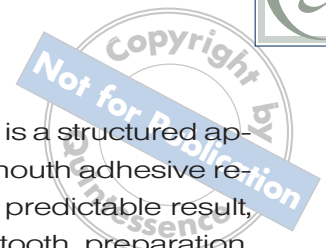
Fig 18 (a and b) Another example of a patient affected by severe dental erosion, restored according to the three-step technique. At this stage the posterior quadrants (except the second molars) were restored with interim posterior resin composite (second clinical step).

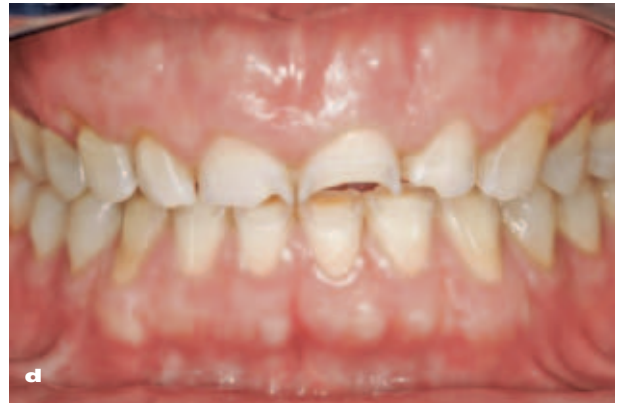
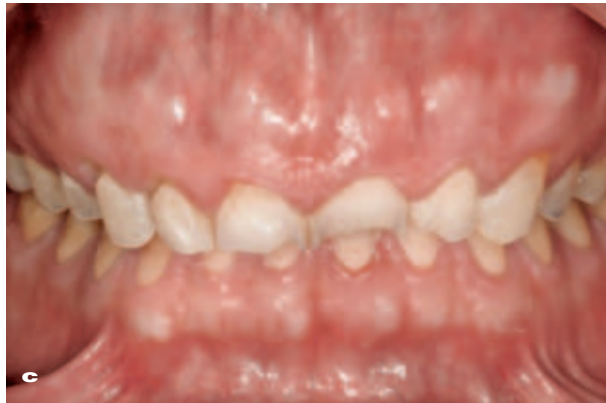
Fig 18 (c and d) Frontal view at the new vertical dimension of occlusion shown in Fig 18b. Normally, patients who were informed beforehand deal well with the resulting anterior open bite.

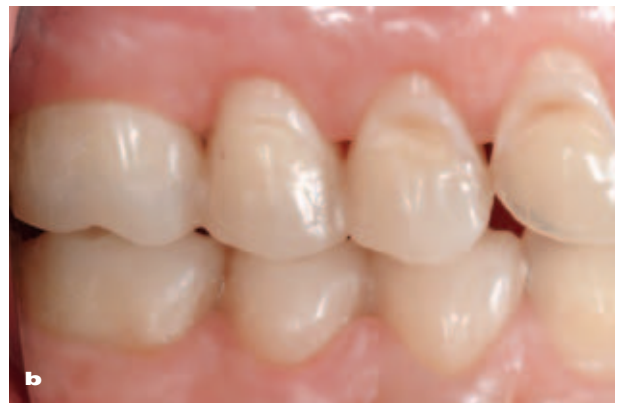
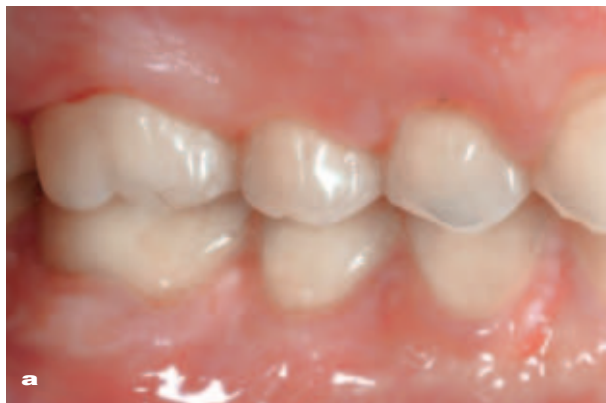
Fig 19 Close-up view of the previous patient's right side. Initial status **(a)** and after the second clinical step **(b)**. The patient underwent mucogingival surgery, which revealed distinct class V lesions, previously located slightly subgingivally.



scientific evidence. At the University of Geneva, the protocol suggests waiting one month. This is a completely arbitrary and experimental choice. Once the patient feels comfortable and neither signs nor symptoms of temporomandibular dysfunction appear, the acceptance of the new VDO can be confirmed, and the third step (the creation of the anterior guidance) can be undertaken.

If the clinician is concerned about leaving the patient without anterior contacts and thus without a functional anterior guidance during the testing phase of the newly introduced, increased VDO, the third step could be initiated more rapidly.

Finally, the technician will concentrate on the anterior teeth. Based on the degree of destruction, the palatal aspect of the anterior teeth will be restored (direct or indirect resin composites), representing the third and last clinical step of the three-step technique.

At this point the patient will be stable from a point of view of occlusion. The only definitive restorations are the palatal reconstructions. The vestibular/incisal aspects of the anterior maxillary teeth, as well as the remainder of the posterior teeth, still need to be treated by means of permanent restorations.

Conclusions

The restorative therapy of dental erosion should be based on a minimally invasive approach, even in the case of extensive loss of tooth structure. Adhesive techniques can help the clinician in rehabilitating this type of patient in the most conservative manner.

The three-step technique is a structured approach to achieve a full-mouth adhesive rehabilitation with the most predictable result, the minimal amount of tooth preparation, and the highest level of patient acceptance. The goal of this technique is to temporarily restore a compromised dentition at a new VDO, implementing directly bonded posterior composite restorations. With a stable posterior support, the anterior teeth can subsequently be restored easily, again using exclusively adhesive techniques. Once the anterior contacts and an anterior guidance are re-established, the replacement of the posterior provisional resin composites can begin. Owing to the presence of the provisional posterior composites, the full-mouth rehabilitation can be planned according to a quadrant-wise approach. Restoring a patient by quadrants has enormous practical advantages for both patient and clinician, since fewer appointments are necessary. Neither multiple anesthetic injections nor difficult full mouth impressions are required. Since the contralateral part of the mouth guarantees a stable occlusion, patients feel comfortable throughout the whole active treatment phase up to the delivery of the final restorations.

In this article, the second step of the three-step technique has been discussed in detail, including the fabrication of the directly bonded provisional posterior composites.

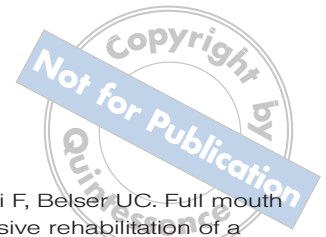
Acknowledgments

The authors would like to thank the laboratory technicians and ceramists Alwin Schönenberger, Patrick Schnider and Sylvain Carciofo for their enthusiastic collaboration and meticulous execution of the laboratory work presented in this article.



References

1. Kavoura V, Kourtis SG, Zoidis P, Andritsakis DP, Doukoudakis A. Full-mouth rehabilitation of a patient with bulimia nervosa. A case report. *Quintessence Int* 2005;36:501–510.
2. Van Roekel NB. Gastroesophageal reflux disease, tooth erosion, and prosthodontic rehabilitation: A clinical report. *J Prosthodont* 2003;12:255–259.
3. Bonilla ED, Luna O. Oral rehabilitation of a bulimic patient: a case report. *Quintessence Int* 2001;32:469–475.
4. Hayashi M, Shimizu K, Takeshige F, Ebisu S. Restoration of erosion associated with gastroesophageal reflux caused by anorexia nervosa using ceramic laminate veneers: a case report. *Oper Dent* 2007;32:306–310.
5. Aziz K, Ziebert AJ, Cobb D. Restoring erosion associated with gastroesophageal reflux using direct resins: case report. *Oper Dent* 2005;30:395–401.
6. Lussi A, Jaeggi T, Schaffner M. Prevention and minimally invasive treatment of erosions. *Oral Health Prev Dent* 2004;2(Suppl 1):321–325.
7. Sundaram G, Bartlett D, Watson T. Bonding to and protecting worn palatal surfaces of teeth with dentine bonding agents. *J Oral Rehabil* 2004;31:505–509.
8. Hastings JH. Conservative restoration of function and aesthetics in a bulimic patient: a case report. *Pract Periodontics Aesthet Dent* 1996;8:729–736.
9. Vailati F, Belser UC. Full mouth adhesive rehabilitation of a severely eroded dentition: the three step technique. Part I. *Eur J Esthet Dent* 2008;1:58–72.
10. Stuart CE, Golden IB. The History of Gnathology. CE Stuart Gnatological Instruments. 1981;13–32,113.
11. Granger ER. *Practical Procedures in Oral Rehabilitation*. Philadelphia: Lippincott, 1962:66–74.
12. McCollum BB. *Fundamentals involved in prescribing restorative dental remedies*. Dental Items Interest, 1939.



Copyright of European Journal of Esthetic Dentistry is the property of Quintessence Publishing Company Inc. and its content may not be copied or emailed to multiple sites or posted to a listserv without the copyright holder's express written permission. However, users may print, download, or email articles for individual use.