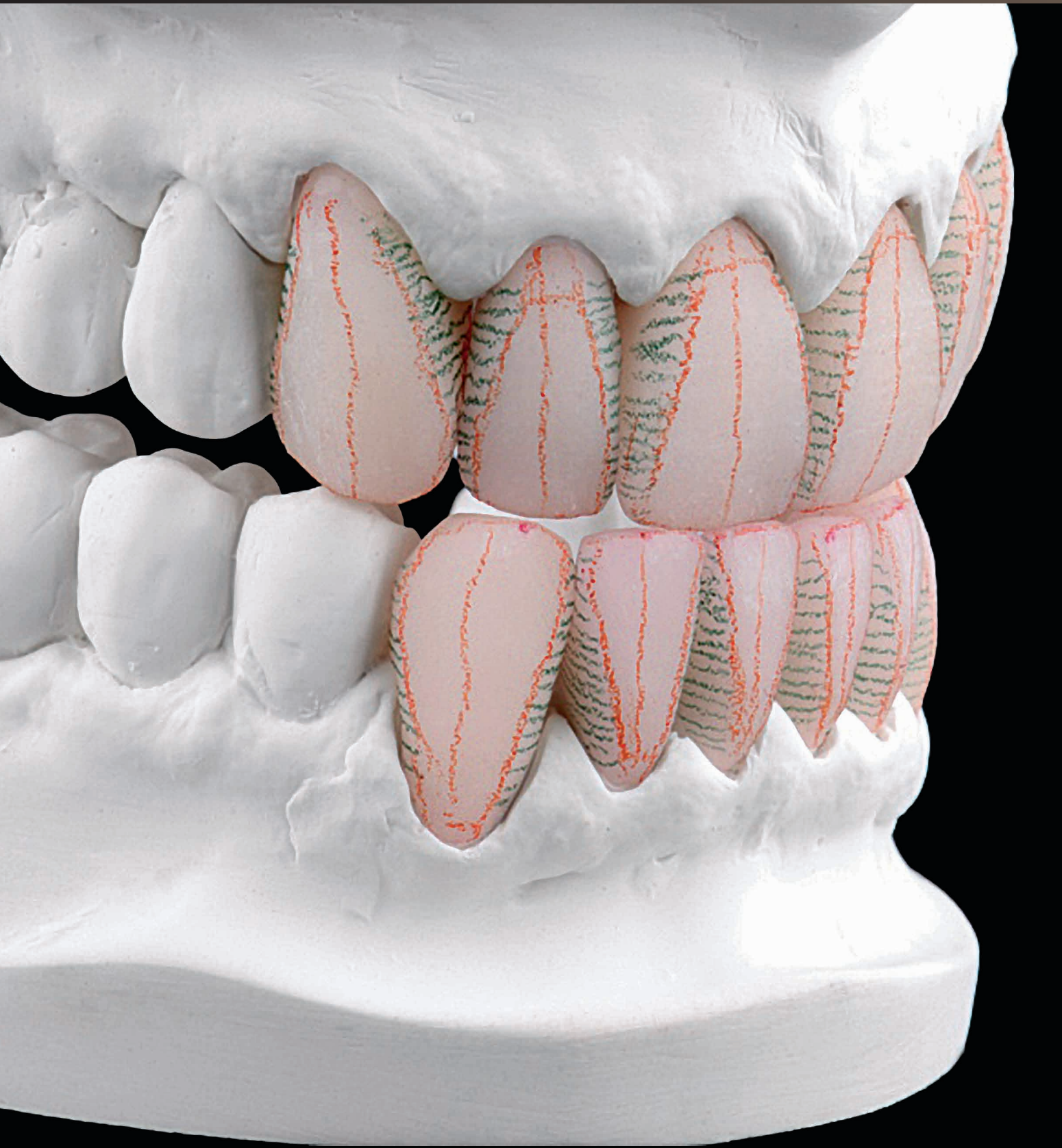



Sergio R. Arias, DDS, MS¹
Aram Torosian, MDC, CDT²
Somkiat Aimplee, DDS, MS¹
Jimmy Londono, DDS³
Gerard Chiche, DDS⁴



State of the Art

Mastering Esthetic and Functional Rehabilitation of the Severely Worn Dentition



¹Esthetic and Implant Fellow, Ronald Goldstein Center for Esthetic and Implant Dentistry, Georgia Regents University, College of Dental Medicine, Augusta, Georgia, USA.

²Master Dental Ceramist, Ronald Goldstein Center for Esthetic and Implant Dentistry, Georgia Regents University, College of Dental Medicine, Augusta, Georgia, USA.

³Assistant Professor, Ronald Goldstein Center for Esthetic and Implant Dentistry, Georgia Regents University, College of Dental Medicine, Augusta, Georgia, USA.

⁴Director, Ronald Goldstein Center for Esthetic and Implant Dentistry, Georgia Regents University, College of Dental Medicine, Augusta, Georgia, USA.

Correspondence to: Dr Sergio R. Arias, College of Dental Medicine, Georgia Regents University Augusta, 1430 John Wesley Gilbert Dr, Augusta, GA 30912. Email: drarias@gmail.com

With advances in all-ceramic systems, adhesive resin cements, implant dentistry, and computer-aided design/computer-assisted manufacture (CAD/CAM) technology, numerous treatment options are available for the fixed prosthetic rehabilitation. These alternatives increase the quality and predictability of dental treatment. A systematic and organized approach is essential in order to evaluate, diagnose, and resolve esthetic and functional problems predictably in a complex restorative case.¹

The following case is presented to illustrate the use of these treatment options in the management of a patient with a severely worn dentition.

CASE PRESENTATION

A 70-year-old male patient presented for treatment at the Ronald Goldstein Center for Esthetic and Implant Dentistry at Georgia Regents University, College of Dental Medicine. The patient was in good general health, and his medical history was noncontributory. His main concern was "My front teeth are getting thin and keep chipping. They don't look natural." The clinical extraoral evaluation revealed a deviated facial midline, a slanted incisal plane, and a retrusive maxillary incisal profile (Fig 1).

Intraoral evaluation revealed significant generalized incisal wear caused by parafunction and erosion, with loss of posterior support and excessive anterior vertical overlap.² In addition, the patient had multiple failing restorations with poor marginal adaptation, and there was an occlusal plane discrepancy caused by supraeruption of maxillary first and second molars into the mandibular edentulous sites. Finally, the central incisors had a narrow tapered appearance and inadequate proportions due to gingival recession and their irregular gingival outlines (Fig 2).

The patient traveled approximately 4½ hours for appointments; therefore, he preferred a treatment plan that would require a minimal number of visits. For this reason, the patient declined orthodontic treatment and requested to have as few surgical procedures as possible.

Based on the compromised esthetic and functional situation of the case, full-mouth rehabilitation was prescribed to (1) correct the occlusal plane discrepancy,

(2) decrease the vertical overlap after achieving proper tooth length, (3) correct the incisal edge position, (4) harmonize the anterior guidance, and (4) improve the esthetic appearance. A diagnostic occlusal splint was fabricated to enable muscular relaxation and to allow the condyles to seat in centric relation (CR), to protect the teeth from further wear, and to evaluate the patient's tolerance of an increase in vertical dimension of occlusion (VDO).³


Esthetic Analysis

The treatment planning started with the esthetic evaluation and proceeded with function, structure, and biology.⁴ A seven-step esthetic analysis was performed as described by Chiche and Pinault, which allows for an early detection of "esthetic red flags."⁵ The first four steps of the analysis relate to the evaluation of the incisal edge position of the maxillary central incisors; their correct position is the foundation from which the smile is built. When the incisal edge position is set correctly, it serves to determine proper tooth proportion and gingival levels.¹

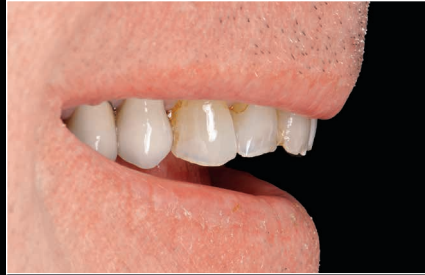Determination of Incisal Edge Position

To improve the incisal display at rest and the irregular incisal edges (see Figs 3a and 3b), a direct composite mock-up was made on the central incisors at the predetermined planned position (Fig 3c). This was done directly facing the patient to reestablish parallelism between the occlusal plane and the interpupillary line and to reestablish verticality of the dental midline (Fig 3d). The composite mock-up was preserved and transferred to the diagnostic stone cast (Fig 3e). The mock-up resembled an inverted "T" effect that followed the interpupillary line perpendicular to the facial midline; it also served as the reference for the diagnostic wax-up (Fig 3f).

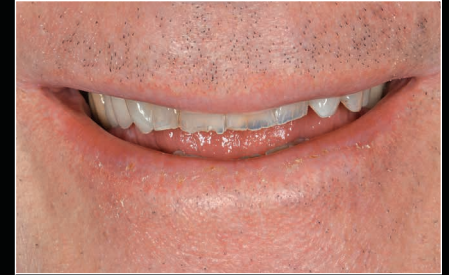A polyvinyl siloxane (PVS) matrix was made of the mock-up seated on the stone cast to record the new incisal edge position (Fig 3g). The matrix was marked and trimmed to outline the incisal edges (Figs 3h and 3i). The matrix was reseated on the cast without the composite resin mock-up, and the space was filled with wax to reproduce the incisal edge position and



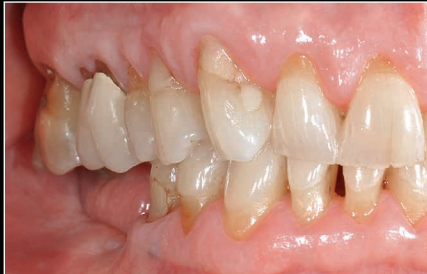1a



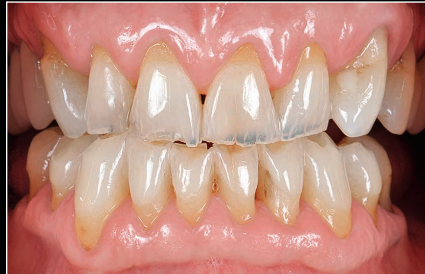1b



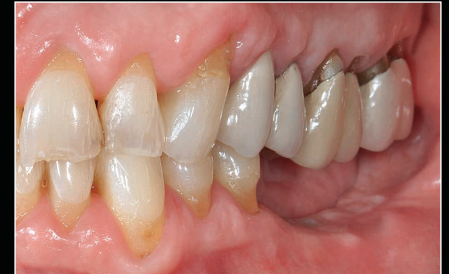1c



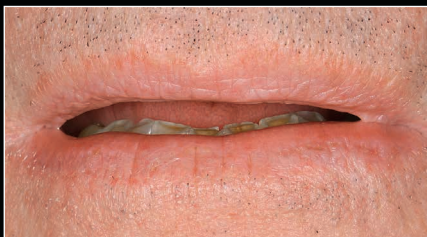2a



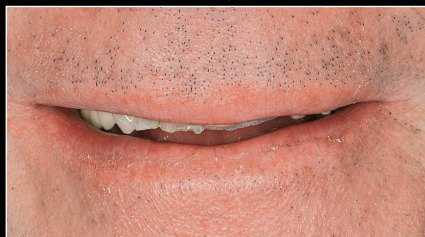2b



2c



3a



3b



3c

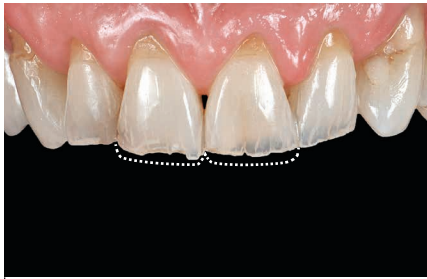
Figs 1a to 1c Preoperative extraoral views.

Figs 2a to 2c Preoperative intraoral views.

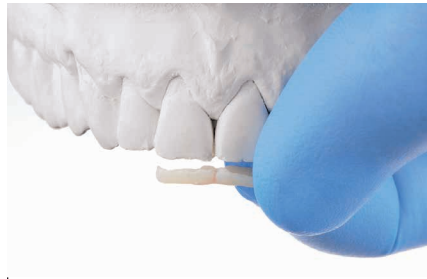Fig 3a Extraoral frontal view of facial lower third at rest.

Fig 3b Moderate smile showing abrasion phenomena on incisal edges of maxillary anterior teeth.

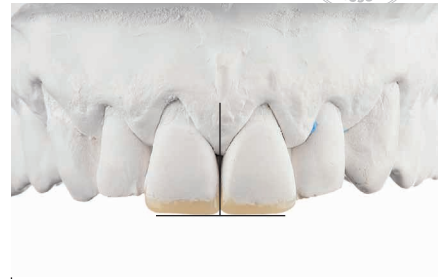Fig 3c Direct mock-up was performed with composite resin.



3d



3e

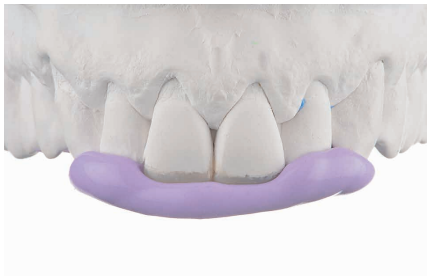

3f

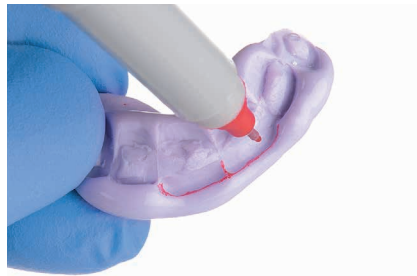Fig 3d New incisal edge position demarcated by reference line.

Fig 3e Composite mock-up transferred to diagnostic stone cast.

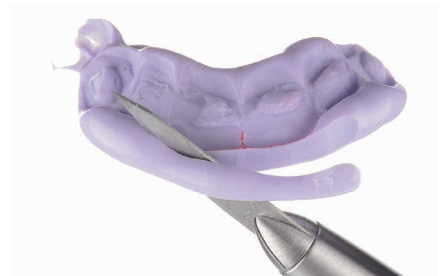Fig 3f Vertical and horizontal reference lines established with the composite mock-up on the cast.



3g



3h

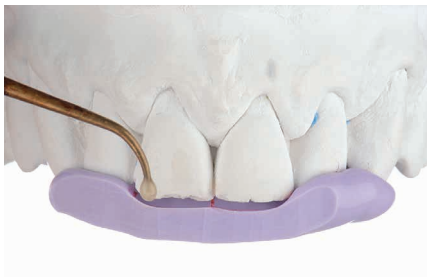

3i

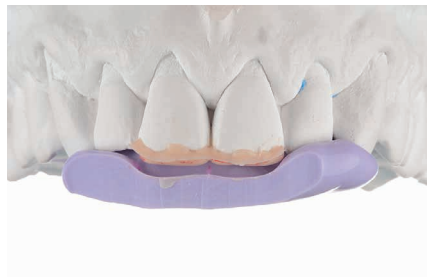Fig 3g A silicone material is used to record the new incisal edge position.

Fig 3h Silicone matrix is marked for trimming.

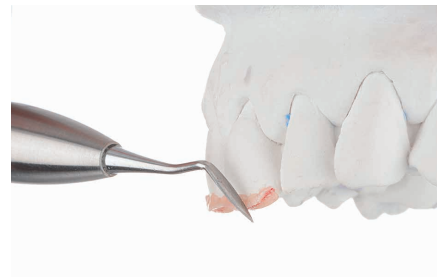Fig 3i Silicone matrix is trimmed at marked level to create space for wax.



3j



3k

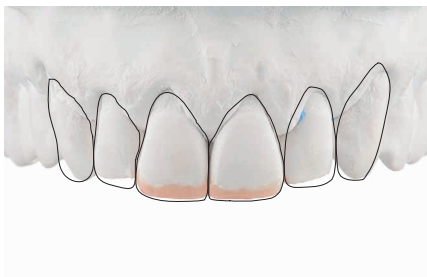

3l

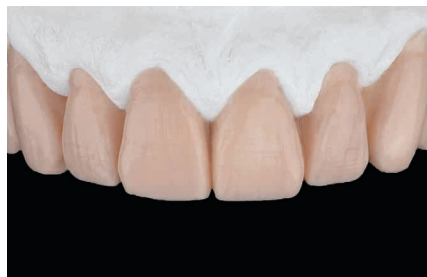Fig 3j Silicone matrix is filled with wax to transfer the new incisal edge position.

Fig 3k Silicone matrix is removed.

Fig 3l Wax excess is removed.




3m



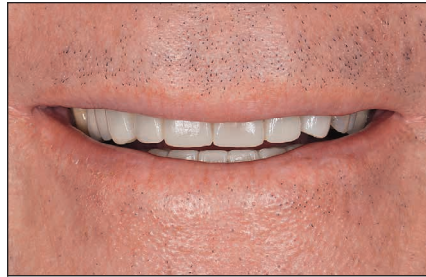3n

Fig 3m New incisal edge position in wax.

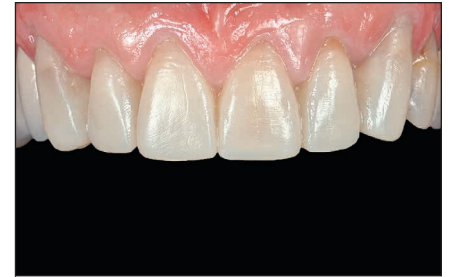Fig 3n Diagnostic wax-up of maxillary six anterior teeth, completed at the new incisal edge position.



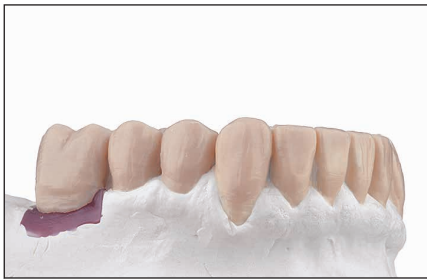4a



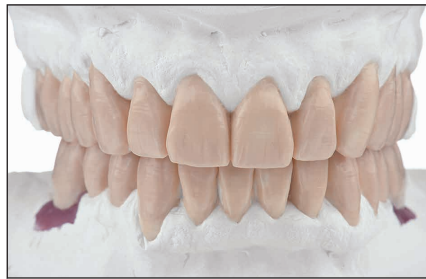4b



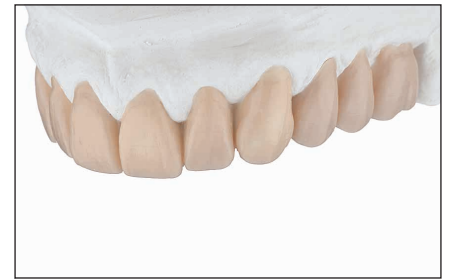4c



5a



5b



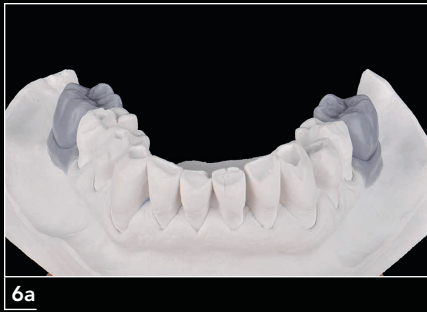5c

Figs 4a to 4c Intraoral and extraoral views of the esthetic indirect mock-up.
Figs 5a to 5c Full-mouth esthetic wax-up.

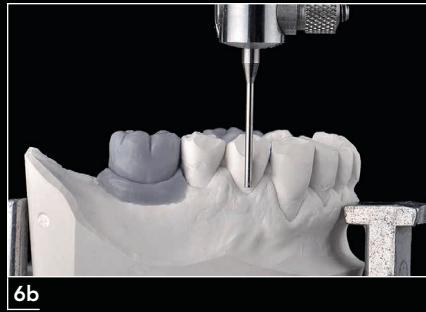midline (Figs 3j and 3k). The flash wax excess was removed with a wax-carving instrument (Fig 3l). The esthetic smile design was planned using the new incisal edge position, creating proper tooth proportions, tooth-to-tooth proportions, and gingival outlines, and fulfilled with the esthetic wax-up⁵ (Figs 3m and 3n).

The new esthetic smile design was transferred to the mouth with an indirect mock-up so that it could be

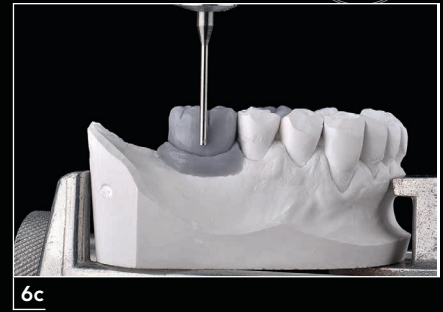reviewed with the patient, and the patient and clinician could get a preview of the new smile (Fig 4). Following the patient's approval, a full-mouth diagnostic wax-up was made that incorporated the following: an increase in VDO to reduce vertical overlap, anterior disocclusion, and a leveled plane of occlusion (Fig 5).



6a



6b



6c

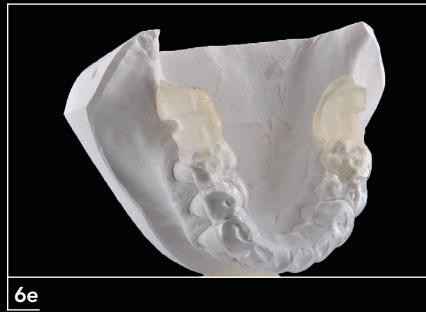Fig 6a Stone cast with wax-up at future implant sites, mandibular right and left first molars.

Fig 6b Surveyor is aligned with axis of adjacent teeth.

Fig 6c Planned mesiodistal position for right first molar implant.



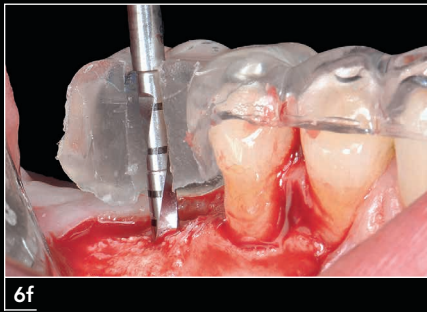
6d



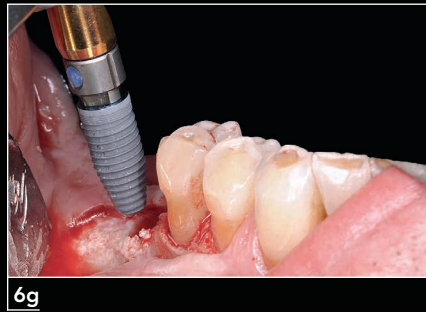
6e

Fig 6d Wax prototype for surgical guide.

Fig 6e Surgical guide generated from the wax-up utilizing a vacuum-formed thermoplastic template and orthodontic acrylic resin.



6f



6g

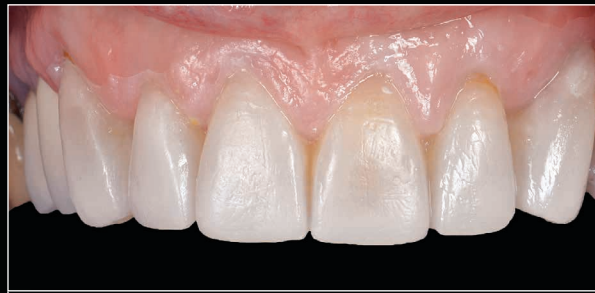Fig 6f Osteotomy preparation using the surgical guide.

Fig 6g Implant placement.

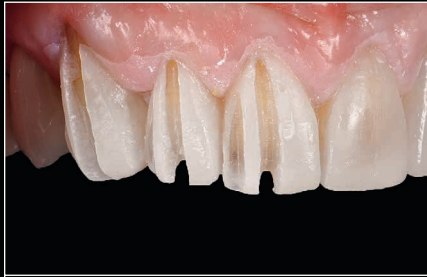Surgical Guide Fabrication and Implant Placement

The correct three-dimensional (3D) implant placement into an adequately prepared site is imperative to achieve an optimal esthetic and functional implant restoration. There are three recommended 3D parameters: (1) apicocoronal: the implant position should be 2 to 4 mm apical to the expected gingival margin position; (2) faciolingual: 2 mm of facial bone is recommended to prevent the loss of facial tissue; and (3) mesiodistal: there should be 2 mm between an implant and adjacent teeth and 3 mm between im-

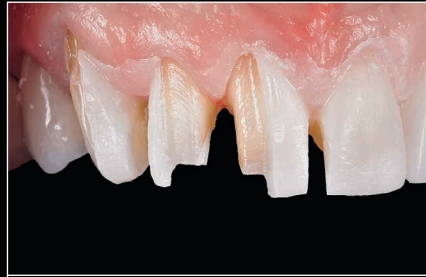plants.⁶⁻⁸ Following these recommendations a diagnostic wax-up was made for planning future implant placement in the positions of the mandibular right and left first molars (Fig 6a). The diagnostic cast with wax-up was mounted in a surveyor for planning implant angulations and positions (Figs 6b to 6d). A surgical guide was generated from the wax-up utilizing a vacuum-formed thermoplastic template and orthodontic acrylic resin (Fig 6e). The surgical guide was seated during osseous preparation, and two 5 × 11-mm implants were placed in the first molar sites (Nobel Replace Tapered, Nobel Biocare) (Figs 6f and 6g).



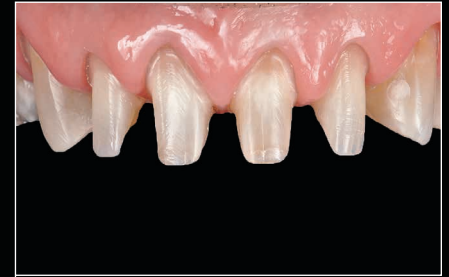7a



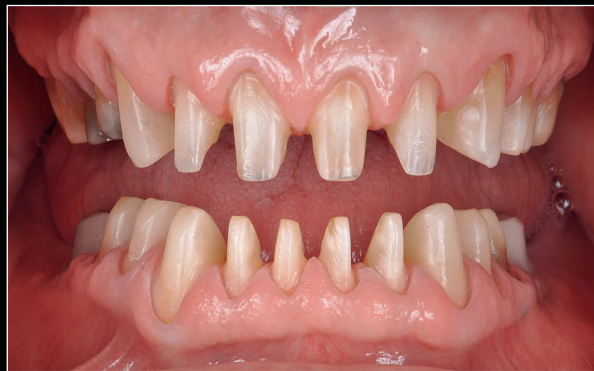7b



7c



7d



7e

Fig 7a Indirect mock-up used as a tooth-reduction guide.

Fig 7b Calibrated depth cuts.

Fig 7c Adjacent teeth used as preparation references.

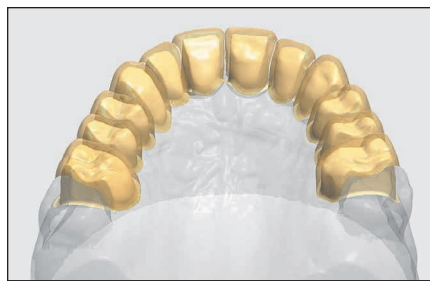Fig 7d Maxillary anterior preparations completed.

Fig 7e Full-mouth preparations completed.

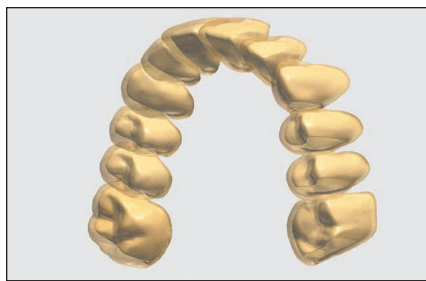
Tooth Preparation Sequence

The mock-up was made again and used as a reduction guide for tooth preservation, a technique that has been described for laminate porcelain veneer preparation by Gürel⁹ (Fig 7a). Calibrated vertical and inci-

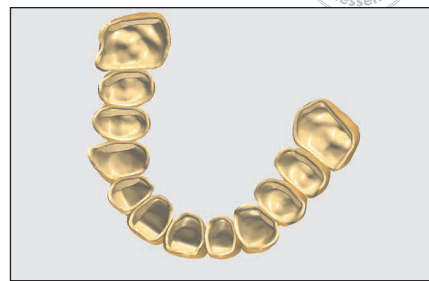sal depth cuts were made and connected by preparing half of the tooth on adjacent teeth; this helped to maintain the correct axis and orientation between preparations (Figs 7b and 7c). Final anterior and full-mouth preparations were completed (Figs 7d and 7e).



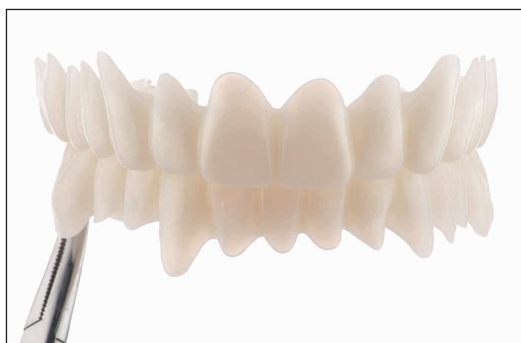8a



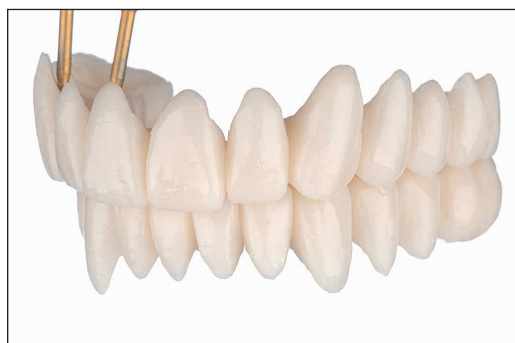8b



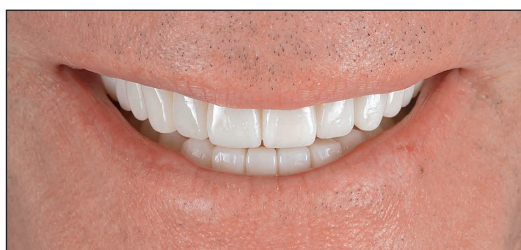8c



8d



8e



8f

Figs 8a to 8c CAD/CAM provisional shell designs.
Fig 8d Maxillary and mandibular CAD/CAM shells.
Fig 8e Provisionals after relining and polishing.
Fig 8f Smile view with provisionals.

CAD/CAM Provisional Restorations

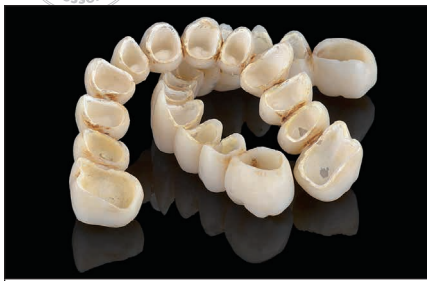The interim restoration plays an essential role in the process of full-mouth rehabilitations. It is considered the blueprint for fabrication of the definitive restoration and should be identical in all respects except for the materials from which it is fabricated.^{10,11} For this patient, a CAD/CAM provisional was fabricated using the shell technique. There are several advantages of this treatment modality: (1) high strength due to less porosity, (2) the material is long lasting, and (3) chairside time is devoted to relining, reducing, and polishing the cervical areas with minimal occlusal adjustment.¹²

The full-mouth wax-up was scanned for fabrication of CAD/CAM shells (Figs 8a to 8c). Note the accuracy of the maxillary shell in occlusion against the mandibular

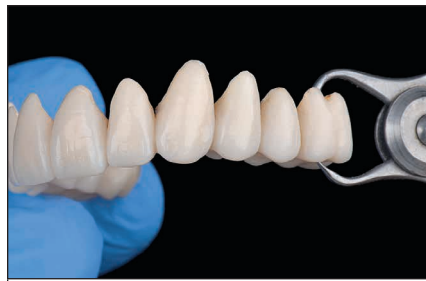shell (Fig 8d). Provisional restorations were relined, finished, polished, and delivered (Figs 8e and 8f).

Evaluation of Provisionals

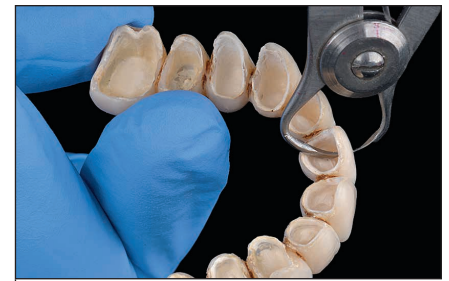
The patient tolerated the provisional restorations well over a period of approximately 8 weeks. During this time the occlusion was checked and adjusted to match the planned occlusal scheme of the diagnostic waxing. Prior to final impressions, the provisionals were measured at the occlusal, incisal, and middle thirds with the temporary cement still in place. This allowed the clinician to determine if the teeth had been sufficiently reduced during preparation (Figs 9a to 9c).



9a



9b

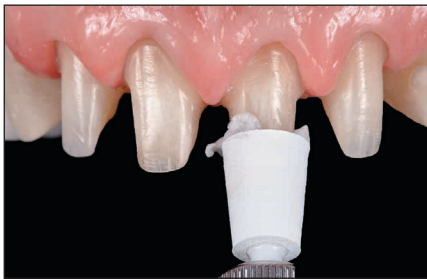

9c

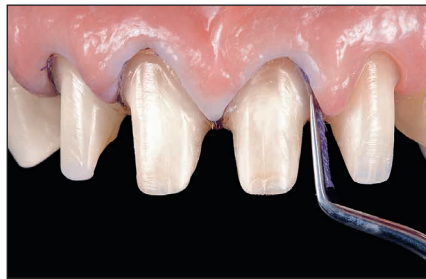Fig 9a Provisionals with retained temporary cement.

Fig 9b Measuring occlusal thickness.

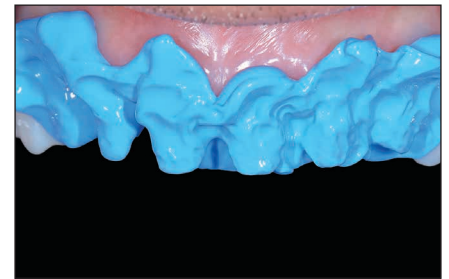
Fig 9c Measuring facial thickness.



10a



10b



10c

Fig 10a Preparations are cleaned with pumice.

Fig 10b Retraction cord is packed.

Fig 10c PVS impression is made.

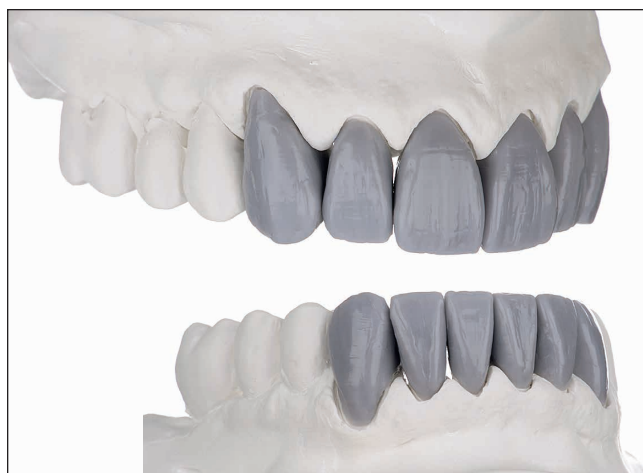Final Impressions

Preparations were cleaned and pumiced, retraction cord was placed, and final impressions were made with a PVS material (Fig 10).

Wax-up and Processing of Pressed Ceramics

Figure 11a shows the wax design of the definitive restorations on the master cast. Wax separator was applied, the margins were sealed with inlay/onlay wax

(Schuler-Dental), and the Ivan Ronald Huanca waxing tool was used to finish the margins and to create a pleasing and natural emergence profile (Figs 11b to 11d). Surface texture, irregularities, and unique characteristics were verified to mimic natural morphology (Figs 11e and 11f). The 3-mm wax sprues were attached in the direction of the ceramic flow at the thickest part of the wax-up to allow the smooth flow of the viscous ceramic during pressing (Fig 11g). The anterior segment was pressed utilizing a lithium disilicate glass ceramic ingot in Value 3 (IPS e.max Press, Ivoclar Vivadent). A delicate divesting process was carried out using fine glass beads (Renfert).



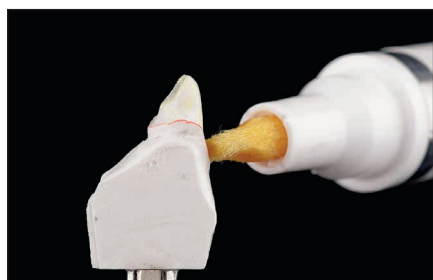11a

Fig 11a Final wax-up of anterior teeth.

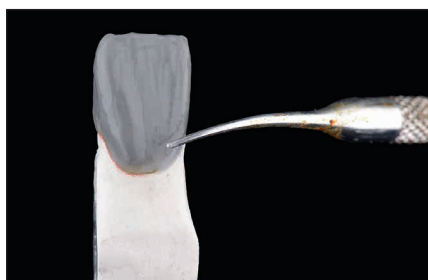
Fig 11b Application of separator.

Fig 11c Sealing the margin.

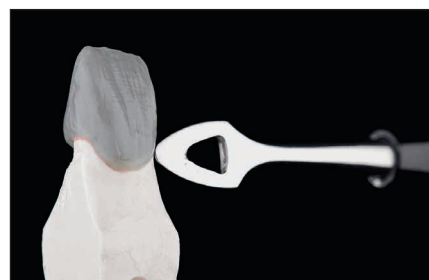Fig 11d Finishing the wax margin and completing the emergence profile.



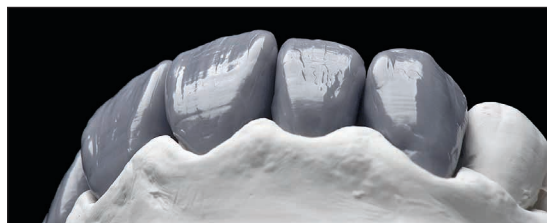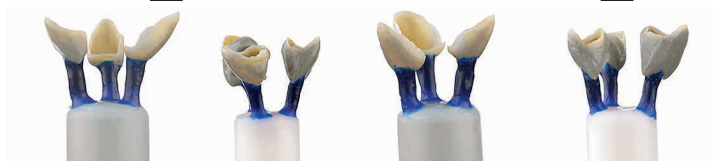11b



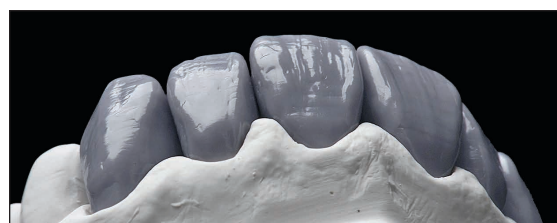
11c



11d



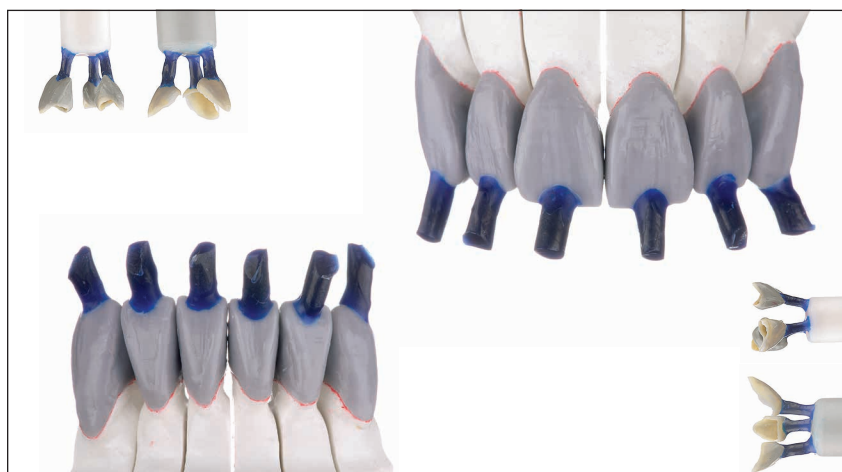
11e



11f

Figs 11e and 11f Texture verification.

Fig 11g Maxillary and mandibular wax-ups with sprues.



11g

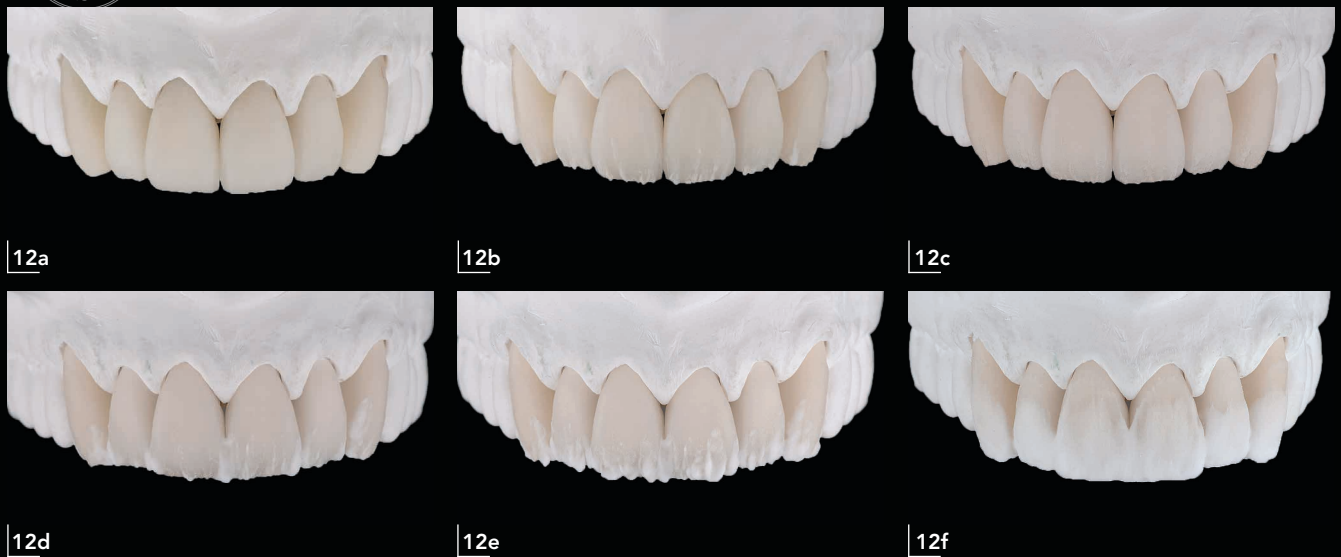


Fig 12a Pressed IPS e.max restorations on cast, minimally cut back at facial third.

Fig 12b First bake: Application of the stain and powder for a bonding layer as well as some internal mamelon-structure effects.

Fig 12c Assessment of wash bake for color and effects.

Fig 12d Second bake: Opal Effect (OE) 1 Ceram material in the interproximal areas.

Fig 12e Segmental ceramic stratification of opalescent and enamel powders, OE 1 on corners, OE 2, OE 3, Bleach incisal, BL4 dentin, and mamelon powders to create contrasts and high- and low-value areas.

Fig 12f Initial ceramic stratification covered by a thin layer of mixed OE 1 and T1.

Ceramic Layering Procedures

The crowns were seated on the master solid cast. The crowns were airborne-particle abraded in the laboratory with glass beads to improve the bond between the pressed and the veneering ceramics. An initial wash firing using a combination of Essence stains and opalescent and mamelon powders was used to enhance the bond between the lithium disilicate and veneering ceramic (IPS e.max Ceram, Ivoclar Vivadent) (Figs 12a to 12c). In the second bake, a combination of Opal Effect 1, Opal Effect 2, Opal Effect 3, BL4 dentin, B1 dentin, and mamelon powders were used segmentally to create subtle contrasts, translucency, and mamelon effects mimicking a natural tooth. The entire build-up was covered with a thin layer of Opal Effect 1/Bleach Incisal to filter the internal structure while maintaining opalescence (Figs 12d to 12f).

Morphologic Contouring Procedures

After fitting the crowns to the master dies, the contacts must be verified and perfected on the solid cast in a systematic manner starting from the mesial of the central incisors and moving to the distal of the canines. Articulating paper was used to disclose interproximal contact interferences for each and every tooth. Larger interference marks were adjusted first (Fig 13). The morphology of each tooth was outlined in the facial, cervical, and interproximal areas. This provides an overall preview of the final proportions and form of the teeth. It is during this stage that fine adjustments were made to visualize the changes while using the marked outlines as guides to make the necessary morphologic modifications (Fig 14a).

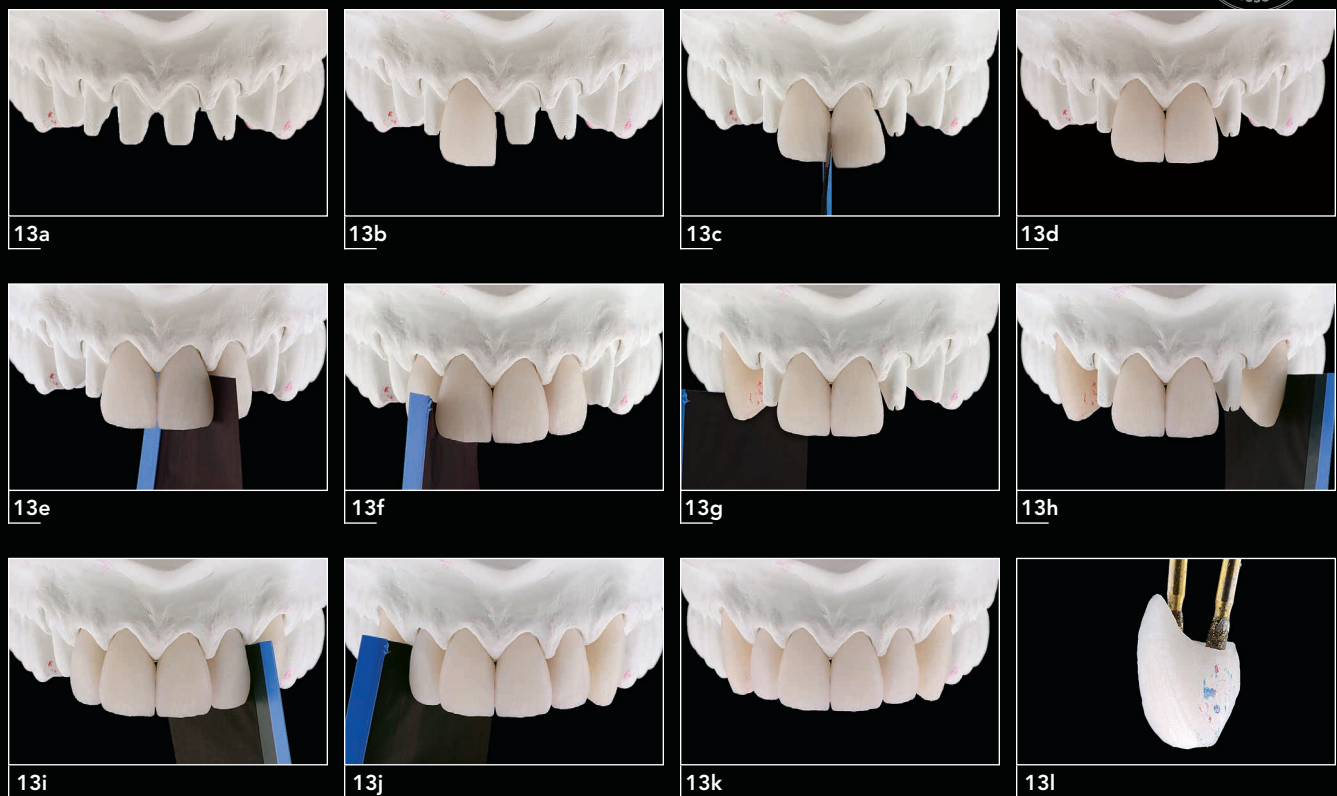


Fig 13a Solid cast.

Fig 13b Start with central incisors when adjusting interproximal contacts.

Fig 13c Identify the interproximal contact interference with articulating paper between the two central incisors.

Fig 13d Tight contact between proximal surfaces.

Figs 13e to 13j Steps in adjustment of the interproximal contacts.

Fig 13k Proper interproximal contacts.

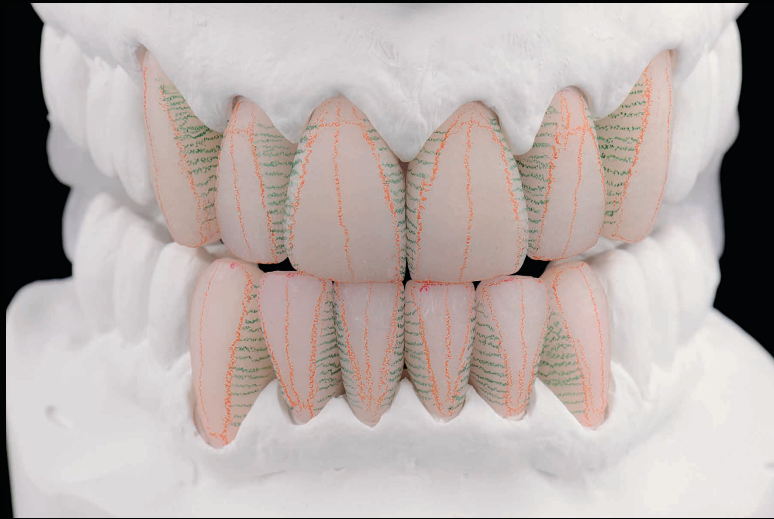Fig 13l It is important to adjust interferences that cause larger marks.

Staining and Finishing


To achieve a lifelike characteristic with the ceramic, subtle external stain was used on the surface prior to glazing. A simple staining approach was utilized to achieve this look: blue stain in the incisal area, white stain mixed with a cervical shade for the mamelons, and cervical color for the basic hue of the target shade. Pure white should be applied in the incisal area but in specific spots using different intensities. After staining the effects, a fixation firing is carried out to freeze all the stains in place, followed by glaze paste application and hand polishing with silicone wheels and fine pumice. Morphology and surface characteristics are shown in Figs 14b to 14d, and definitive anterior restorations on the solid cast in Fig 14e.

Posterior Segment Finishing Procedures

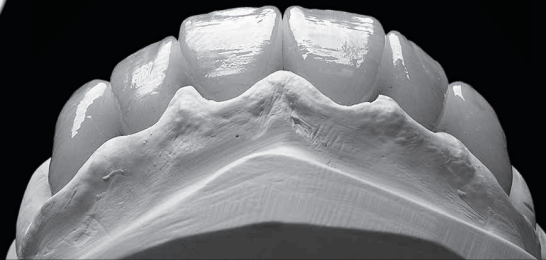
Figure 15 shows the wax designs of the restorations in the posterior segments. Completed lithium disilicate and monolithic screw-retained zirconia crowns were placed on the solid casts (Fig 16). The milled monolithic zirconia implant crown was cemented to the NT Trading Titanium Base (Custom Automated Prosthetics) using a dual-curing resin cement (Panavia SA, Kuraray). The titanium base was airborne-particle abraded with aluminum oxide to prepare the surface and to enhance the bond to the zirconia. The screw channel was blocked with wax to prevent residual cement from blocking the screw head. The crown was airborne-particle abraded with aluminum oxide, coated with ceramic primer, and loaded with the resin cement.



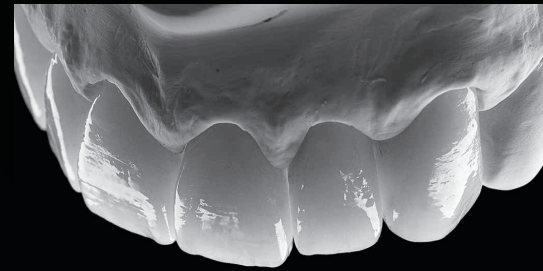
14a



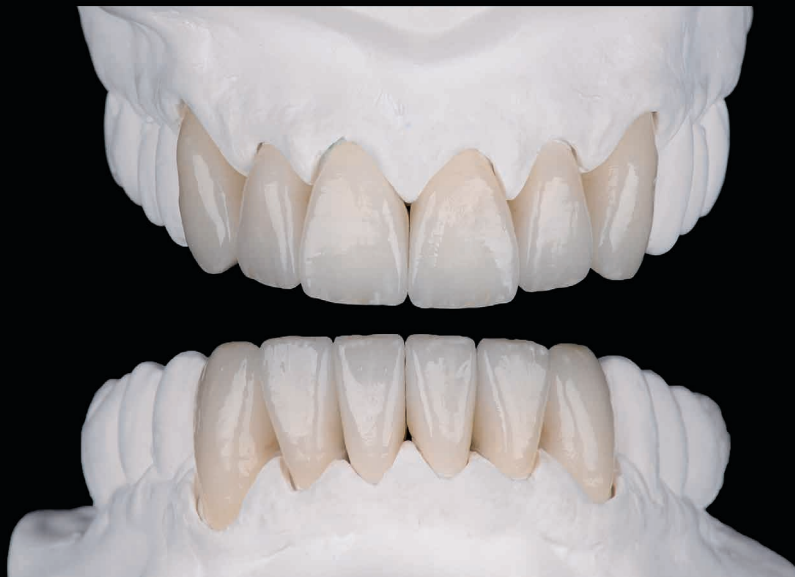14b



14c

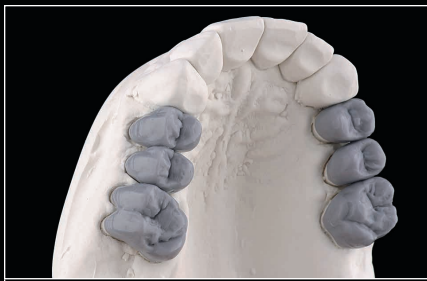

14d

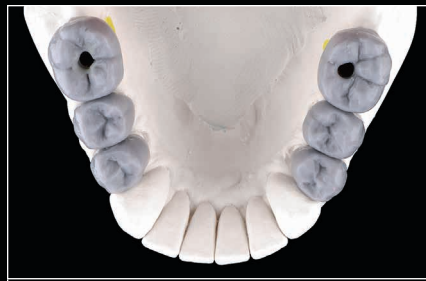

14e

Fig 14a Outline of morphology and surface characteristics to replicate natural teeth.
Figs 14b to 14d Morphology and surface characteristics.
Fig 14e Completed all-ceramic restorations on solid casts.



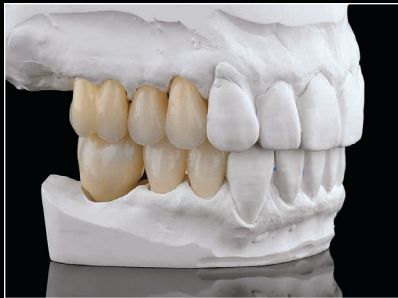15a



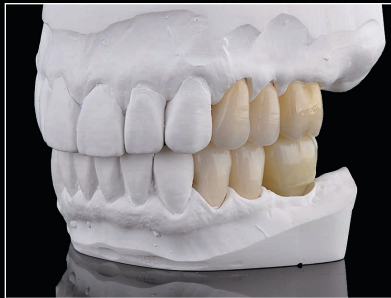15b

Fig 15a Maxillary wax-up.

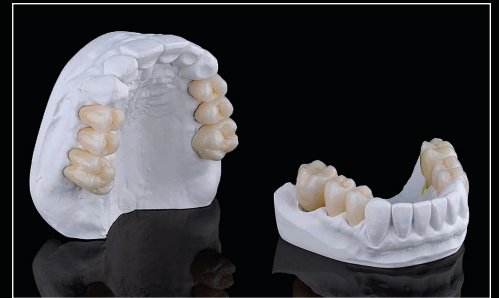Fig 15b Mandibular wax-up.



16a



16b



16c

Figs 16a to 16c Completed all-ceramic and screw-retained crowns on solid casts.



17a



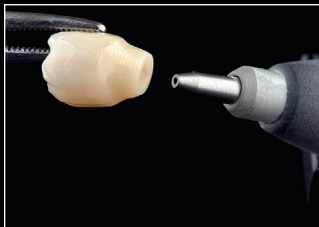
17b



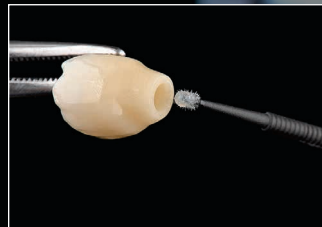17c



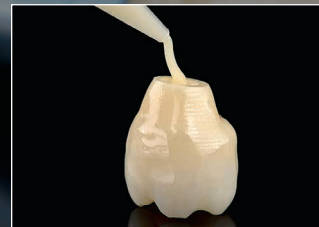17d



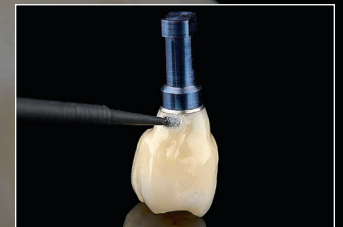17e



17f



17g



17h

Fig 17a NT Trading Titanium Base and screw for the screw-retained monolithic crown.

Fig 17b Titanium base on implant analog.

Fig 17c Airborne-particle abrasion at 2 bar pressure with aluminum oxide.

Fig 17d Wax added to the access hole to protect the screw.

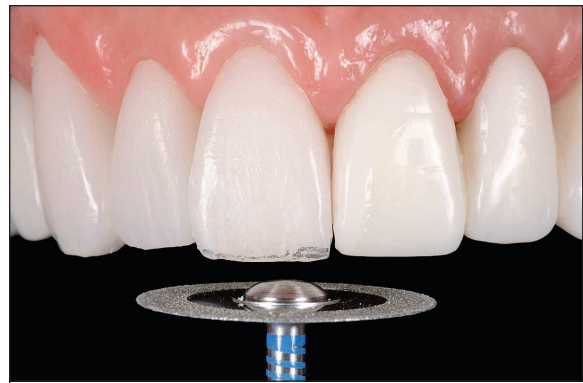Fig 17e Airborne-particle abrasion of inside the zirconia crown at 2 bar pressure to prepare the surface.

Fig 17f Application of Clearfil ceramic primer (Kuraray).

Fig 17g Application of Panavia SA resin cement (Kuraray).

Fig 17h Removing excess cement.

Fig 18 Try-in of definitive restorations against provision-als: adjusting the length of definitive restoration.

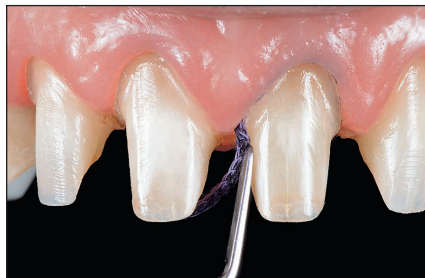

18

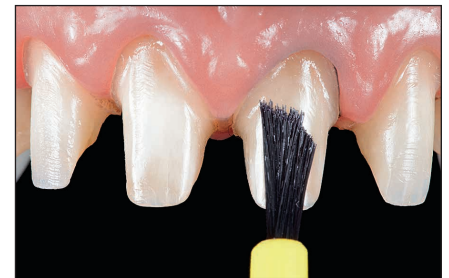Fig 19a Retraction cord is placed to control cement flow.

Fig 19b Adhesive is applied to the prepared tooth.

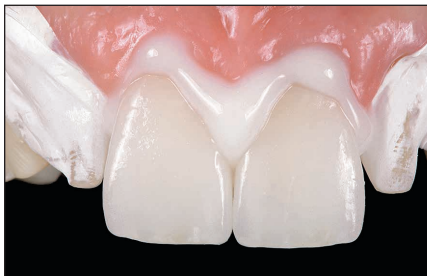Figs 19c to 19e Excess cement cleaned and retraction cords removed.



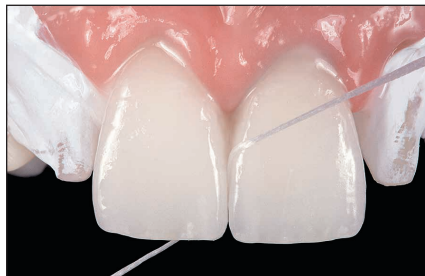19a



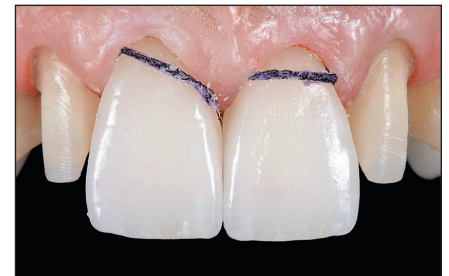19b



19c



19d



19e

The crown was seated on the titanium base, and excess cement was removed with a microbrush prior to light curing (Fig 17).

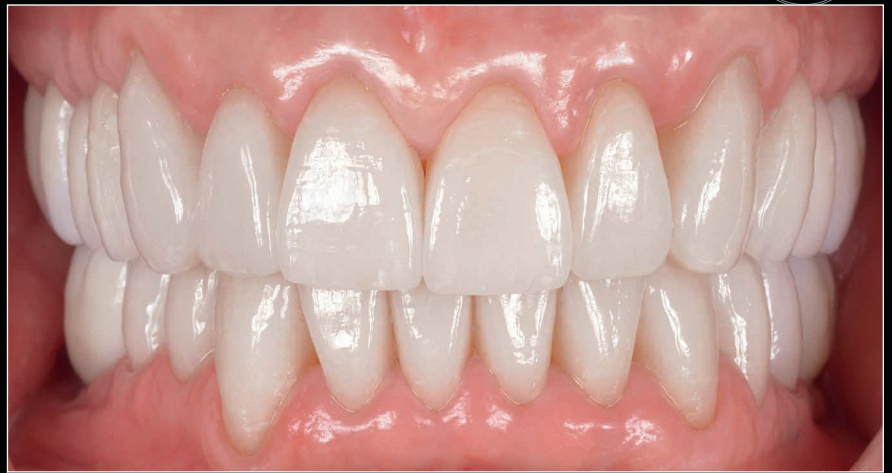Try-In and Bonding of All-Ceramic Definitive Restorations

The all-ceramic materials selected for the case were monolithic zirconia crowns, stained and glazed, for the maxillary first molars; monolithic zirconia screw-retained implant crowns, stained and glazed, for the mandibular first molars; and pressed monolithic lithium disilicate crowns, stained and glazed, for the anterior teeth and premolars. The completed restorations

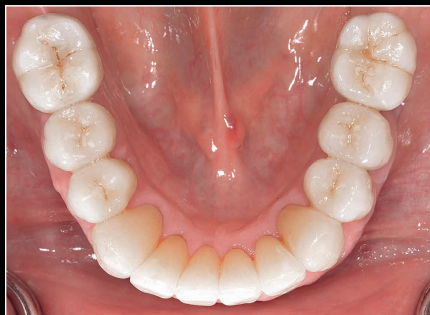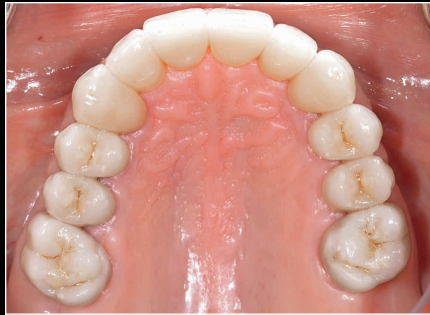were examined for accuracy of contacts, fit, contour, and esthetics. Anterior restorations were seated and compared to adjacent provisional restorations to evaluate length and anterior guidance. Adjustments were made as necessary (Fig 18).

The crowns were prepared for bonding, prepared teeth were cleaned, retraction cord was placed (Ultra-dent), and adhesive was applied (Scotch Bond Universal, 3M ESPE). The crowns were loaded with dual-curing resin cement and seated (RelyX Ultimate, 3M ESPE), and excess cement was removed with a brush and floss. After light curing for 40 seconds per surface, a no. 12 scalpel blade was used to remove excess cement, and the retraction cords were removed (Fig 19).

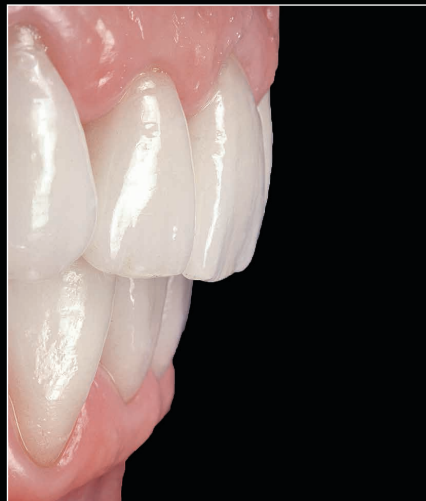Figs 20a to 20i Postdelivery intraoral views of definitive restorations.



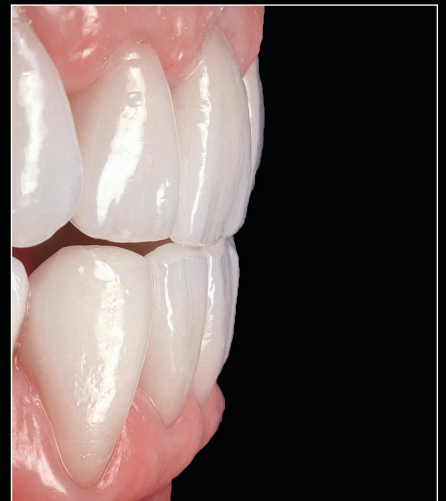20a



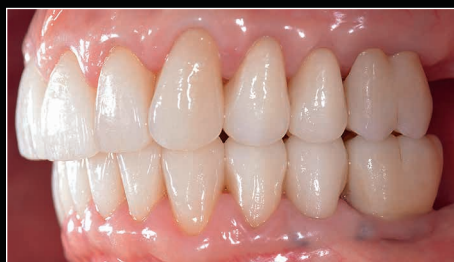20b, c



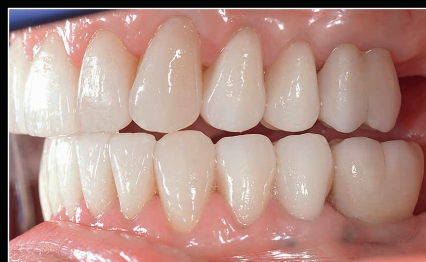20d



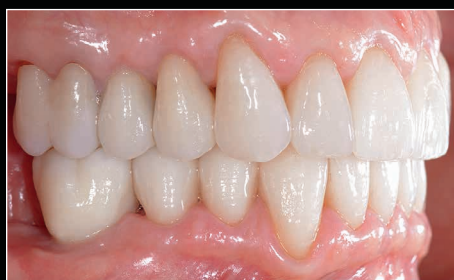20e



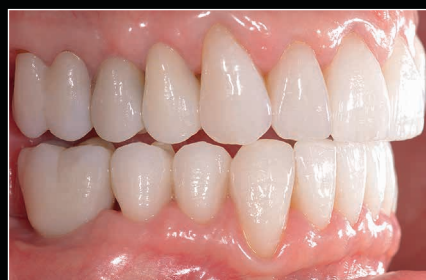20f



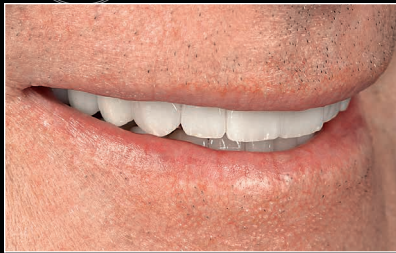20g



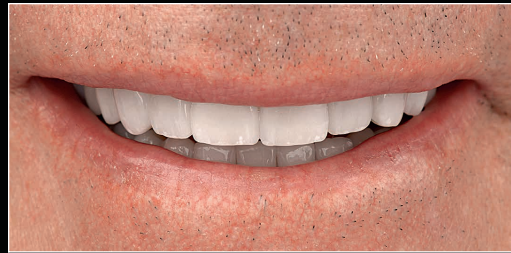20h



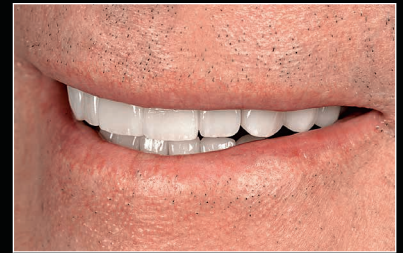20i



21a



21b



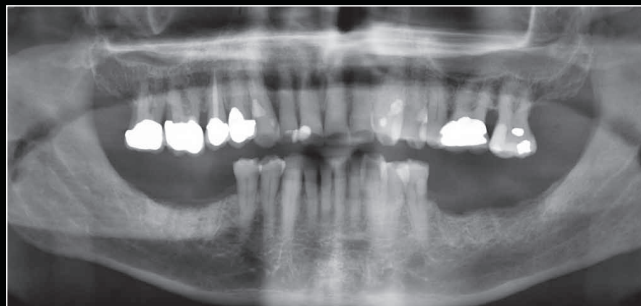
21c

Figs 21a to 21c Extraoral lower-third views.

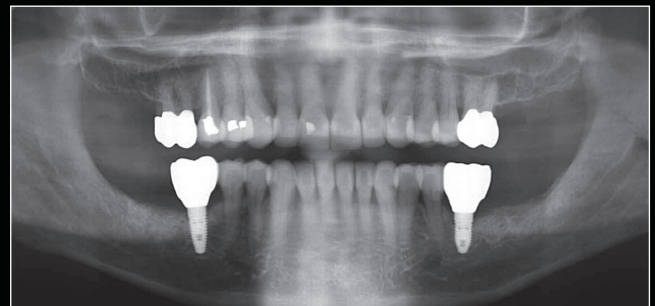
Fig 21d Portrait frontal view.



21d



22a



22b

Figs 22a and 22b Initial and posttreatment panoramic radiographs.

CONCLUSIONS

The procedure described in this article is a full-mouth rehabilitation completed with all-ceramic systems, which restored the patient to an excellent esthetic

outcome as well as a stable and functional occlusion (Fig 20). Close-up views of the smile and portrait views of the final restorations are shown in Fig 21. The initial and final panoramic radiographs showed a stable bone condition (Fig 22).

ACKNOWLEDGMENTS

The authors thank Nobel Biocare and The Georgia Regents University Center for Excellence for their support in this case. Dr Jae Seon Kim is also thanked for his assistance in sharing his unique expertise with the treatment of the patient.

REFERENCES

1. Chiche G, Pinault A. *Esthetics of Anterior Fixed Prosthodontics*. Chicago: Quintessence, 1993:202.
2. Carlsson GE, Egermark I, Magnusson T. Predictors of bruxism, other oral parafunctions, and tooth wear over a 20-year follow-up period. *J Orofac Pain* 2003;17:50–57.
3. Dylina TJ. A common-sense approach to splint therapy. *J Prosthet Dent* 2001;86:539–545.
4. Spear FM, Kokich VG. A multidisciplinary approach to esthetic dentistry. *Dent Clin North Am* 2007;51:487–505,X–XI.
5. Chiche G. Proportion, display, and length for successful esthetic planning. In: Cohen M (ed). *Interdisciplinary Treatment Planning: Principles, Design, Implementation*. Chicago: Quintessence, 2008.
6. Tarnow DP, Cho SC, Wallace SS. The effect of inter-implant distance on the height of inter-implant bone crest. *J Periodontol* 2000;71:546–549.
7. Salama H, Salama MA, Garber D, Adar P. The interproximal height of bone: A guidepost to predictable aesthetic strategies and soft tissue contours in anterior tooth replacement. *Pract Periodontics Aesthet Dent* 1998;10:1131–1141.
8. Davarpanah M, Martinez H, Tecucianu JF. Apical-coronal implant position: Recent surgical proposals. Technical note. *Int J Oral Maxillofac Implants* 2000;15:865–872.
9. Gürel G. Predictable, precise, and repeatable tooth preparation for porcelain laminate veneers. *Pract Proced Aesthet Dent* 2003;15:17–24.
10. Torosian A, Arias S. Provisionalization of dental implants in the esthetic zone: A Blueprint for Success. *Labline* 2013;3(1):116–123.
11. Higginbottom FL. Quality provisional restorations: A must for successful restorative dentistry. *Compend Contin Educ Dent* 1995;16:442, 444–447.
12. Chiche G. Improving marginal adaptation of provisional restorations. *Quintessence Int* 1990;21:325–329.