
Esthetics: The Orthodontic-Periodontic Restorative Connection

Vincent G. Kokich

As we complete the 20th and progress into the 21st century, orthodontists worldwide are experiencing a gradual but significant change in their practices. The number of adult patients has increased substantially. Although adults cooperate better than adolescents, they present a different set of challenges for the orthodontist. Adults may have worn or abraded teeth, uneven gingival margins, missing papillae, and periodontal bone loss, all of which can jeopardize the esthetic appearance of the teeth after bracket removal. This article will discuss the solutions for managing these challenging orthodontic-periodontic-restorative situations to produce a more ideal esthetic result. (Semin Orthod 1996;2:21-30.) Copyright © 1996 by W.B. Saunders Company

The objectives of orthodontic therapy are to establish a good occlusion, enhance the health of the periodontium, and improve dental and facial esthetics. Orthodontic literature, research, and training emphasize the importance of the final occlusal result following orthodontic treatment. In the past less emphasis has been placed on periodontal health and the esthetic appearance of the teeth after appliance removal. Although tooth contact is important, the interrelationship between orthodontics, periodontics, and esthetics, should not be de-emphasized.

In most adolescent patients who are not missing teeth, have a healthy periodontium, and have not worn or abraded their teeth, a well-fitting occlusion is esthetically pleasing when the patient smiles. However, orthodontists treat patients who do not have ideal tooth morphology and periodontal health. Poor oral hygiene, worn or abraded teeth, fibrotic tissue, missing papillae, and uneven crown lengths will jeopardize the esthetic appearance of the teeth and the smile after treatment. This article demonstrates the relationship between tooth position and

gingival esthetics, and delineates when tooth movement or periodontal surgery is the most appropriate to improve anterior dental esthetics.

This article will deal with three unesthetic situations that may develop during orthodontic treatment: the "gummy" smile, gingival margin discrepancies, and the "missing papilla." In some of these situations, alteration of tooth position is preferred to correct the esthetic problem. In other patients gingival surgery is the optimal treatment plan for enhancing the esthetic appearance of the teeth. This article will help the clinician choose the most appropriate treatment plan for each specific situation.

The "Gummy" Smile

During smiling, the upper lip moves apically to expose the anterior teeth. Ideally, the lip should rise to a level at or slightly apical to the gingival margins of the maxillary central incisors. In this situation, about 1 to 2 mm of gingiva will be apparent when the patient smiles.¹ However, some patients show more than 2 mm of gingival tissue. Although this situation does not produce any pathological sequelae, it may appear unesthetic. The "gummy" smile has three potential causes. It may be the result of excessive maxillary growth and occurs in patients with longer than normal facial heights, shorter than normal upper lips, and more than normal eruption of the maxillary teeth.² If all maxillary teeth have

From the Department of Orthodontics, School of Dentistry, University of Washington, Seattle, WA.

Address correspondence to Vincent G. Kokich, DDS, MSD, Department of Orthodontics, School of Dentistry, University of Washington, Seattle, WA 98195.

*Copyright © 1996 by W.B. Saunders Company
1073-8746/96/0201-0004\$5.00/0*

overerupted, treatment requires a combination of orthodontics and orthognathic surgery to move the entire maxilla apically. This problem, its ramifications and the effect on lip/gingival esthetics, have been described in several previous studies.³⁻⁵ Therefore, the correction of vertical maxillary excess will not be discussed in this article.

A second cause of the "gummy" smile is delayed apical migration of the gingival margin over the maxillary anterior teeth. Normally, as teeth erupt during childhood and adolescence, the gingival margin migrates apically until it reaches its normal adult position. In most adults, the gingival margin is positioned about 1 mm coronal to the cemento-enamel junction.^{6,7} Usually this level is reached during late adolescence. However, in some patients the gingival tissue may be thick and fibrotic. Thicker tissue tends to migrate more slowly than thin gingival tissue. If this situation exists during orthodontics, it is important to recommend the appropriate treatment in the correct sequence. If an adolescent patient shows excessive gingiva during smiling, the first step is to probe the gingival sulci of the maxillary anterior teeth (Fig 1). The sulcular depth should be about 1 mm, and the cemento-enamel junction should be located at the depth of the sulcus.⁸ If the sulcular depth is 3 to 4 mm, and the tissue is fibrotic, several years may elapse before the gingival margin migrates toward the cemento-enamel junction. This is especially true if the tissue is not inflamed. This type of patient could benefit from gingival surgery to move the gingival margin apically toward the cemento-enamel junction (Fig 1).

The timing for esthetic gingival surgery depends on the presence of wear at the incisal edges of the centrals and laterals. If the incisal edges are unworn and level with one another, the cemento-enamel junctions of the two central incisors should be at the same height. In this situation, gingival surgery may be delayed until after orthodontic appliances have been removed. However, if the incisal edges of the centrals have been abraded, the cemento-enamel junctions may be at different levels even though the incisal edges are aligned. In this situation, gingival surgery should be performed before orthodontic bands and brackets are removed.⁹ In this way, if any discrepancy exists between the gingival margins after surgery, the longer tooth

can be extruded slightly, and the incisal edge can be equilibrated to level the gingival margins.

The type of gingival surgery depends on the relationship between the crest of the alveolar bone and the cemento-enamel junction. In most adults, the alveolar crest is about 2 mm from the cemento-enamel junction.⁶ To determine the bone level, the surgeon pushes the periodontal probe past the bottom of the sulcus, through the epithelial attachment and connective tissue and stops at the bone level. If the bone level is 2 mm from the cemento-enamel junction, excisional surgery would be appropriate to apically position the gingival margins. However, if the bone level is within 0.5 mm of the cemento-enamel junction, an apically positioned flap with recontouring of the alveolar crestal bone may be the most appropriate surgery.¹⁰⁻¹³ These decisions are made at the time of the surgical procedure. In either case, moving the gingival margins apically to expose the complete crown length of the anterior teeth not only enhances the esthetic appearance of the incisors and canines, but reduces the display of gingiva when the patient smiles.

Occasionally, the "gummy" smile is caused by tooth malposition (Fig 2). In this situation, gingival surgery is inappropriate. The ideal plan is to move the tooth and its gingival margin to a more esthetic position. This is especially true in adult patients with deep anterior overbites. If a patient has a "gummy" smile, the clinician must identify whether it is apparent anteriorly, or anteriorly and posteriorly.¹⁴ If the problem only exists anteriorly, this may be caused by overeruption of the maxillary incisors with concomitant movement of the gingival margin coronally as the teeth erupt.

In this situation, the clinician must first probe the sulci of the centrals and laterals to determine if there is excess gingiva that can be excised. If the sulcular depth is 1 mm, gingival surgery would not be sufficient to improve the esthetics without adversely affecting the crown to root ratio. However, intrusion of the overerupted teeth would reposition the gingival margins to a more esthetic level (Fig 2). In this situation, either the lateral incisors or the maxillary canines serve as a guide for repositioning the gingival margins of the central incisors (Fig 2). Ideally, the central incisor gingival margins should be about 1 mm apical to the lateral incisors. The gingival margins of the canines and centrals

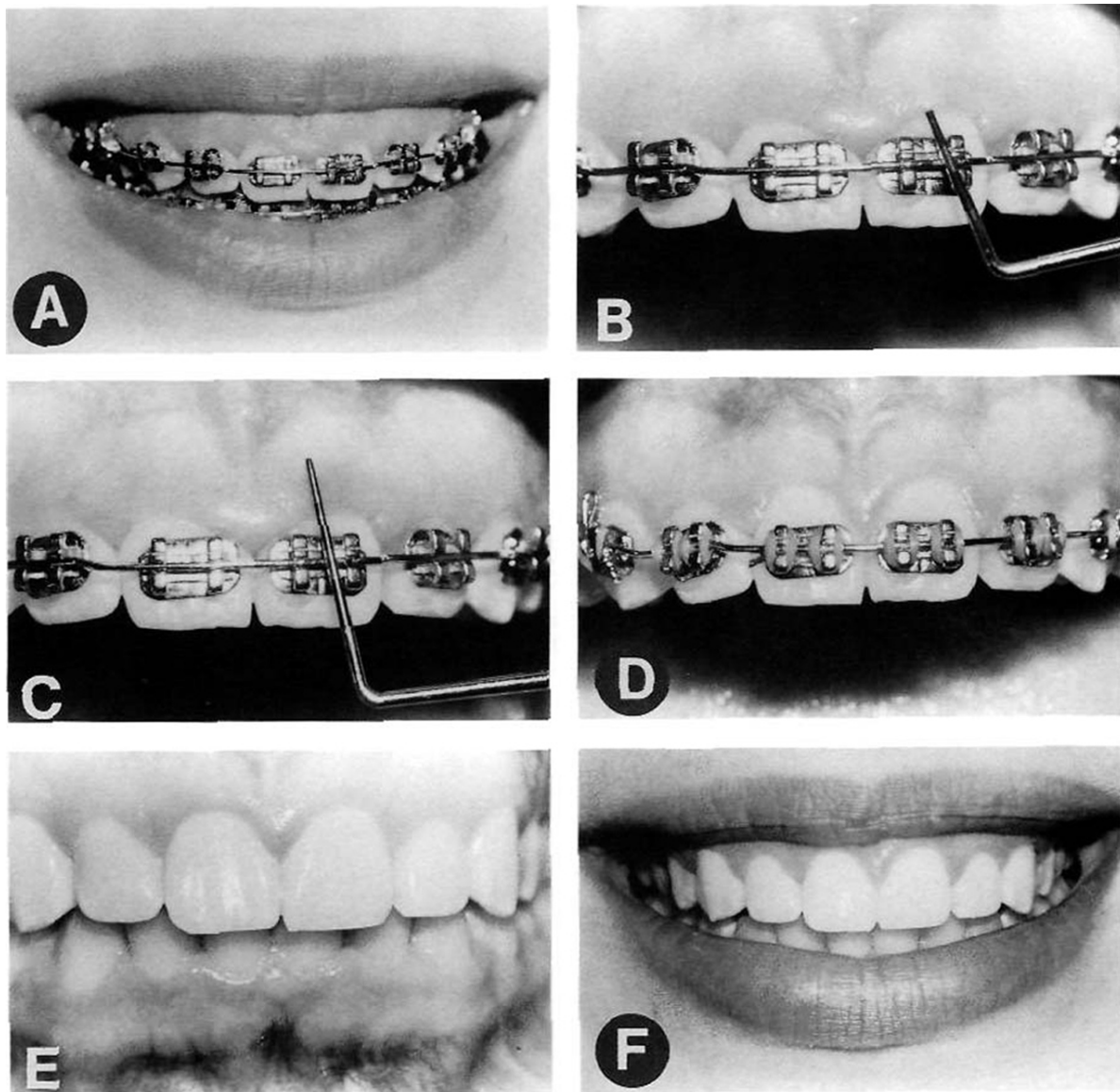


Figure 1. During the finishing stages of orthodontic treatment, this patient complained about her “gummy” smile (A). Probing of the sulci over the maxillary anterior teeth showed no bleeding (B), and the sulcular depths were excessive at about 4 mm (C). An excisional gingivectomy and frenectomy were performed to increase the clinical crown length (D, E), which resulted in a more esthetically pleasing smile after bracket removal (F).

should be at the same level.¹⁴ As the centrals are intruded, an incisal restoration may be necessary to restore original crown length if the centrals have been abraded at their incisal edge (Fig 2). Restoration should be delayed until after the gingival margin levels have been completely corrected. In the appropriate situation, tooth intrusion and restoration are the correct method for eliminating the “gummy” smile. The clinician must identify those patients who would benefit from gingival surgery and those who

would be more ideally treated with orthodontic leveling of the gingival margins.

Gingival Margin Discrepancies

The relationship of the gingival margins of the six maxillary anterior teeth plays an important role in the esthetic appearance of the crowns.¹⁵⁻¹⁷ Four characteristics contribute to ideal gingival form. First, the gingival margins of the two central incisors should be at the same level.

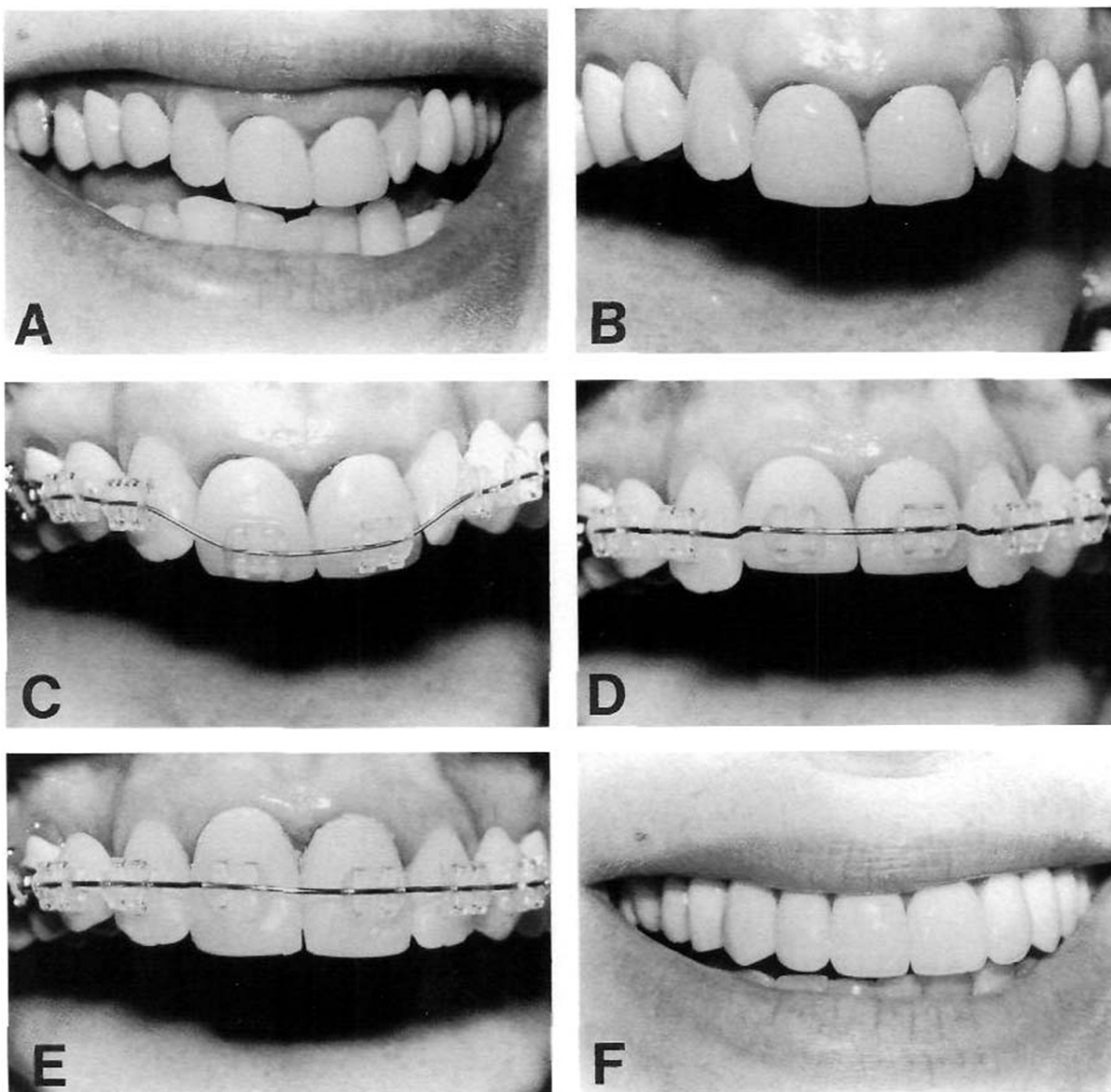


Figure 2. This adult patient was concerned about the unesthetic display of gingiva when she smiled (A). She was being treated orthodontically to improve tooth position before restorative treatment to replace bilateral missing maxillary canines (B). Because the gingival margin over the central incisors was positioned coronally relative to the lateral incisors (B), the central incisor brackets were placed near the incisal edge (C), to permit relative intrusion of the central incisors (D) during orthodontic alignment. As the centrals moved apically, the gingival margin discrepancy was corrected (D) and provisional restorations were constructed to correct the crown length and incisal edge position (E). Intrusion of the central incisors to move the gingival margins apically eliminated the "gummy" smile after maxillary restoration (F).

Second, the gingival margin of the central incisors should be positioned more apically than the lateral incisors and should be at the same level as the canines. Third, the contour of the labial gingival margins should mimic the cementoenamel junctions of the teeth. Last, there should be a papilla between each tooth, and the height of the tip of the papilla is usually halfway between

the incisal edge and the labial gingival height of contour over the center of each anterior tooth. Therefore, the gingival papilla occupies half of the interproximal contact, and the adjacent teeth form the other half of the contact. However, some patients have gingival margin discrepancies between adjacent teeth. These discrepancies may be caused by abrasion of the incisal

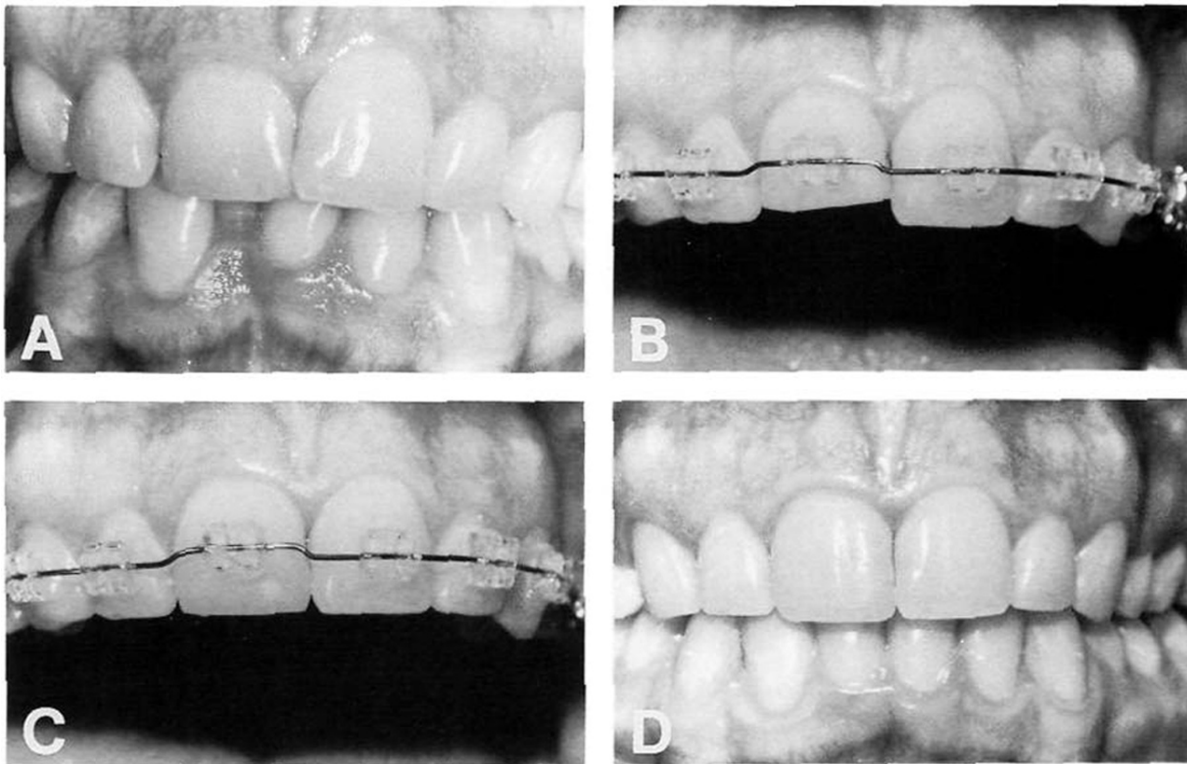


Figure 3. This patient had moderate crowding of the maxillary and mandibular incisors. In addition, the clinical crown length of the maxillary right central was shorter than the left central (A). Because the sulcular depths were normal, the crown lengths were corrected by intruding the right central (B) and restoring the incisal edge with composite (C). After debracketing, the esthetic appearance of the teeth has been improved by alignment and correction of the crown length discrepancy (D).

edge (Fig 3) or delayed migration of the gingival tissue (Fig 4). When gingival margin discrepancies are present, the clinician must determine the proper solution for the problem: orthodontic movement to reposition the gingival margin or surgical correction of gingival margin discrepancies.

To make the correct decision, it is necessary to evaluate four criteria.⁹ First of all, the relationship between the gingival margin of the maxillary central incisors and the patient's lip line should be assessed when the patient smiles. If a gingival margin discrepancy is present, but the patient's lip does not move upward to expose the discrepancy, it does not require correction. If the gingival margin discrepancy is apparent, the next step is to evaluate the labial sulcular depth over the two central incisors. If the shorter tooth has a deeper sulcus, excisional gingivectomy may be appropriate to move the gingival margin of the shorter tooth apically (Fig 4). However, if the sulcular depths of the short and long incisors are equivalent, gingival surgery will not help.

The next step is to evaluate the relationship between the shortest central incisor and the adjacent lateral incisors. If the shortest central is still longer than the lateral incisors, the other possibility is to extrude the longer central incisor and equilibrate the incisal edge. This will move the gingival margin coronally and eliminate the gingival margin discrepancy. However, if the shortest central incisor is shorter than the laterals, this technique would produce an unesthetic relationship between the gingival margins of the central and lateral incisors.

The fourth step is to determine if the incisal edges have been abraded. This is best appreciated by viewing the teeth from an incisal perspective. If one incisal edge is thicker labiolingually than the adjacent tooth, this may indicate that it has been abraded, and the tooth has overerupted. In this situation, the best method of correcting the gingival margin discrepancy is to intrude the short central incisor (Fig 3). This method will move the gingival margin apically, and permit restoration of the incisal edge.¹⁵⁻¹⁸ The intrusion

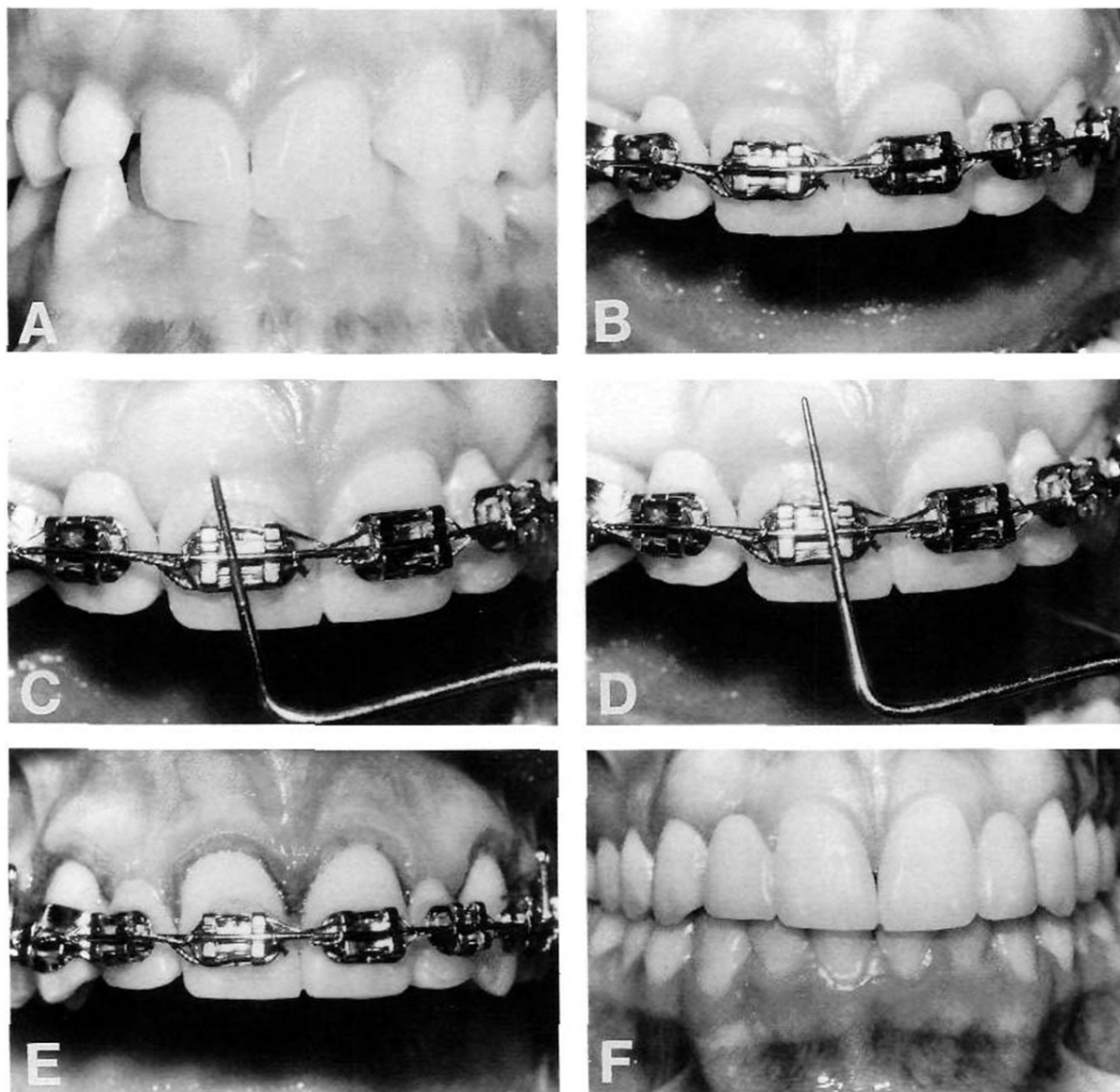


Figure 4. This patient was congenitally missing both maxillary lateral incisors, and the maxillary right canine was impacted palatally (A). The canine was moved out of the palate, and space was opened for two plastic pontics to replace the lateral incisors (B). The gingival esthetics in the maxillary anterior region was unacceptable (B). Probing of the sulcular depths (C) showed a 4 mm depth labial to the centrals (C, D). An excisional gingivectomy (E) was performed to improve the gingival margin relationship between the centrals, laterals and canines (E). Proper gingival margin relationships resulted in more esthetic final bridges (F).

should be accomplished at least 6 months before appliance removal. This will allow reorientation of the principle fibers of the periodontium and avoid re-extrusion of the central incisor after appliance removal.^{19,20}

The relationship between the gingival margins of adjacent teeth is even more important for patients who require restorations after orthodontic therapy (Fig 4). If patients are congenitally

missing maxillary lateral incisors, and space is opened for resin-bonded bridges, the orthodontist must position the centrals and canines appropriately so that an esthetic bridge may be placed (Fig 4). The gingival margin relationship between the central incisor, the lateral incisor pontic and the crown of the natural canine, must be correct. During the finishing stages of orthodontics, the orthodontist must evaluate this

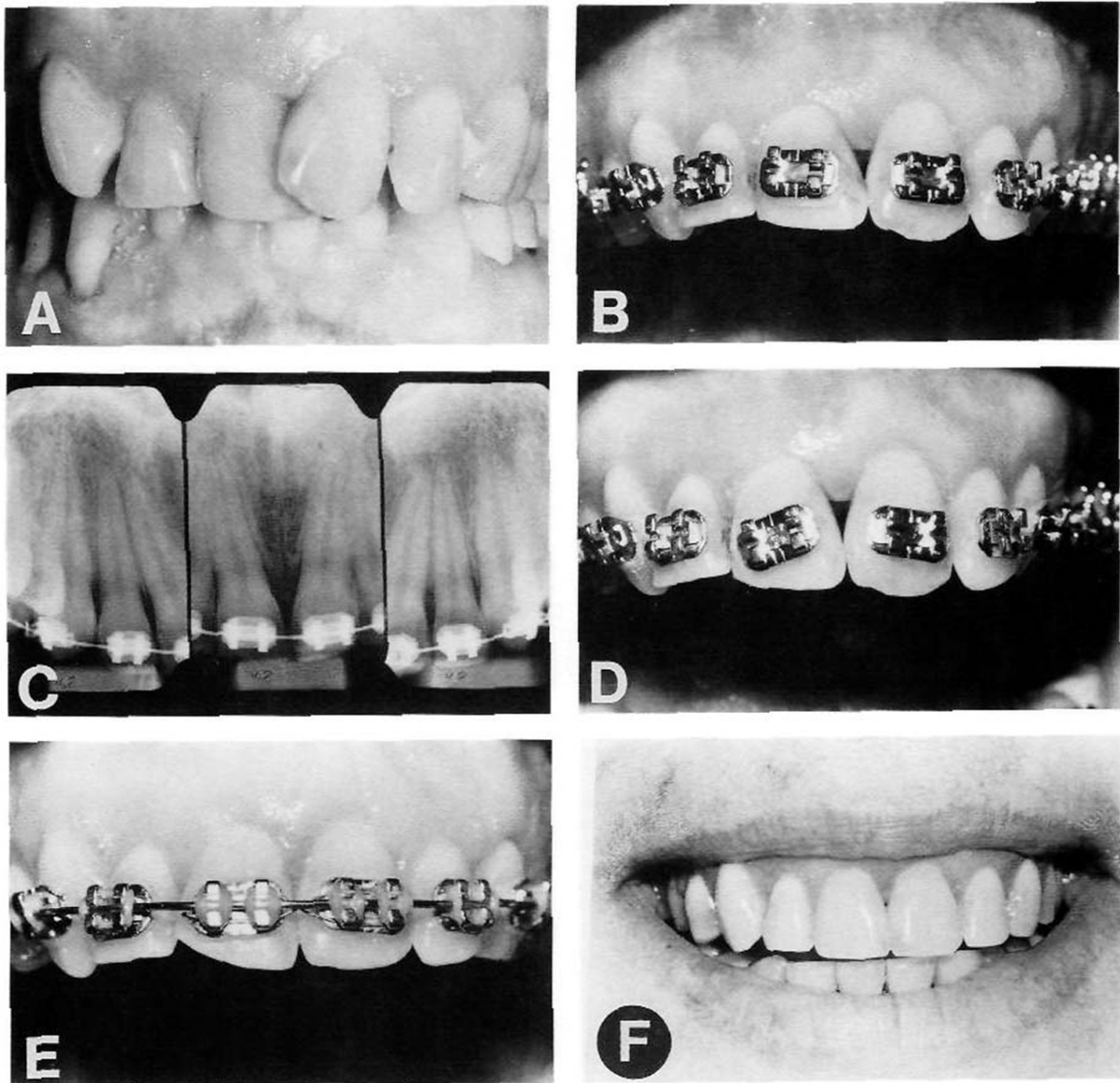


Figure 5. This patient had severe crowding and overlap of the maxillary central incisors (A). As the centrals were aligned, a space occurred between the contact and papilla (B). Although the incisal edges of the teeth were aligned (B), the roots of the centrals diverged (C), which produced the unesthetic gap above the papilla. To produce proper root alignment, the brackets on the centrals were repositioned (D) and the roots were tipped mesially. This tooth movement not only corrected root position, but eliminated the unesthetic space (E). The incisal edge discrepancy produced by uneven wear of the right central incisal edge (E) was restored to recreate normal incisal form (F).

relationship. If the crowns of the central incisors are too short, and the incisal edges have not been abraded, the gingival margins may require surgery (Fig 4). By probing the labial sulci of the incisors, the clinician can determine if the sulcular depth is excessive. If so, gingival surgery is recommended during orthodontic treatment, so

that the final position of the gingival margins of the two central incisors will be equivalent.

The "Missing Papilla"

Presence of a papilla between the maxillary central incisors is a key esthetic factor after

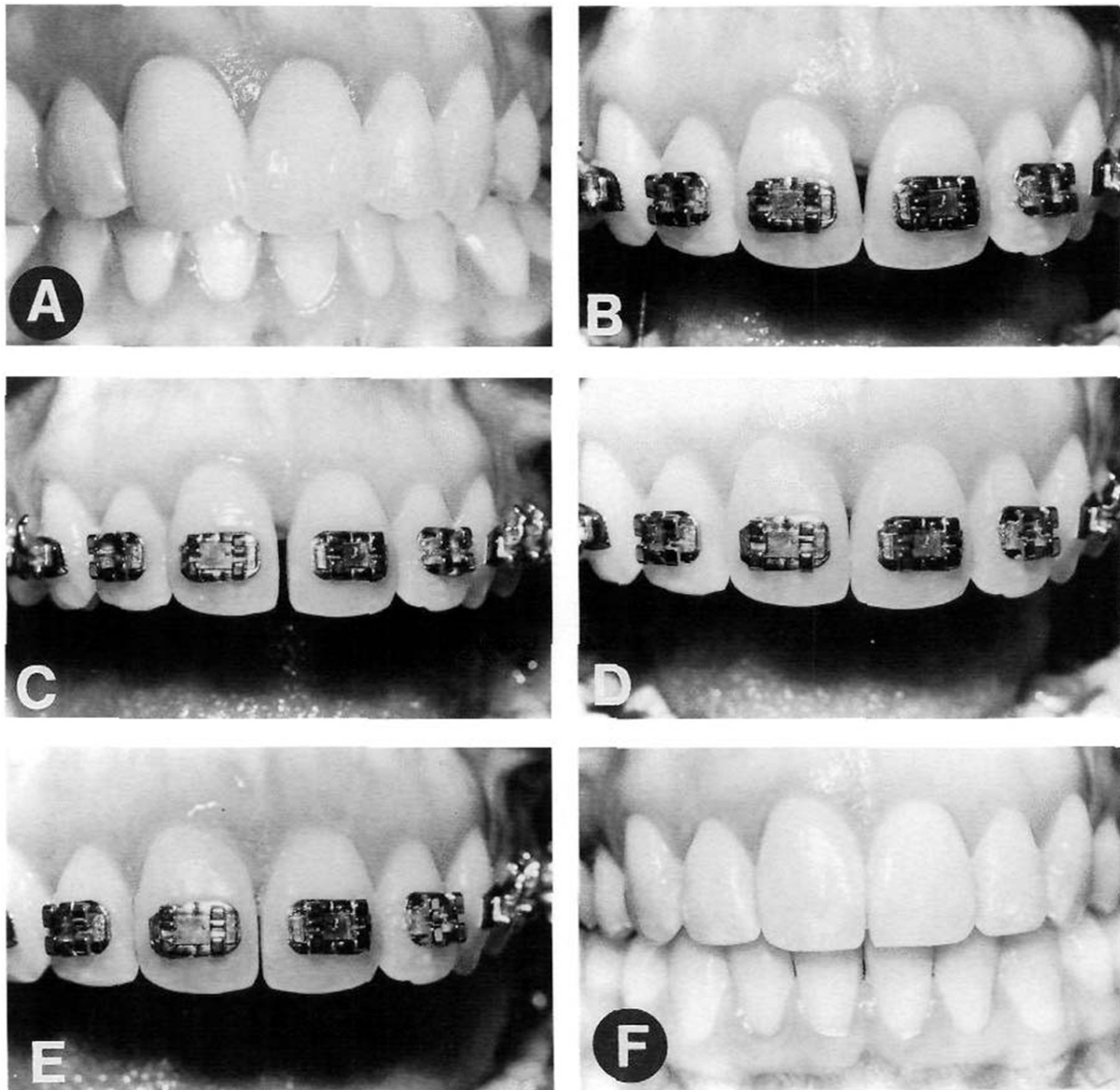


Figure 6. This patient had mild crowding and overlap of the maxillary central incisors (A). As her incisors were aligned, a space occurred between the central incisor papilla and contact (B). This gap was caused by “fan-shaped” morphology of the centrals which placed the interproximal contact near the incisal edge (B). To eliminate the unesthetic space, the mesial surfaces of the centrals were reshaped to lengthen the contact and move it toward the papilla (C, D, and E). By reshaping the mesial surfaces, the contact was lengthened, and the gap was eliminated, producing a more esthetic final result (F).

orthodontic treatment. However, in some patients, the papilla is absent. The presence of a space above the central incisor interproximal contact may be caused by one of three factors. The first possible cause is diverging roots of the maxillary central incisors (Fig 5). This is usually caused by improper bracket placement. In patients with overlapped and abraded maxillary central incisors, brackets may be placed inadver-

tently at an angle that is not perpendicular to the long axis of the central incisor. As the teeth are aligned (Fig 5B), the roots may diverge distally (Fig 5C). To identify this cause, the clinician should evaluate a periapical radiograph. If the roots diverge, the brackets should be removed and repositioned with the bracket slots perpendicular to the long axes of the roots (Fig 5D). As the roots align, the contact point lengthens and

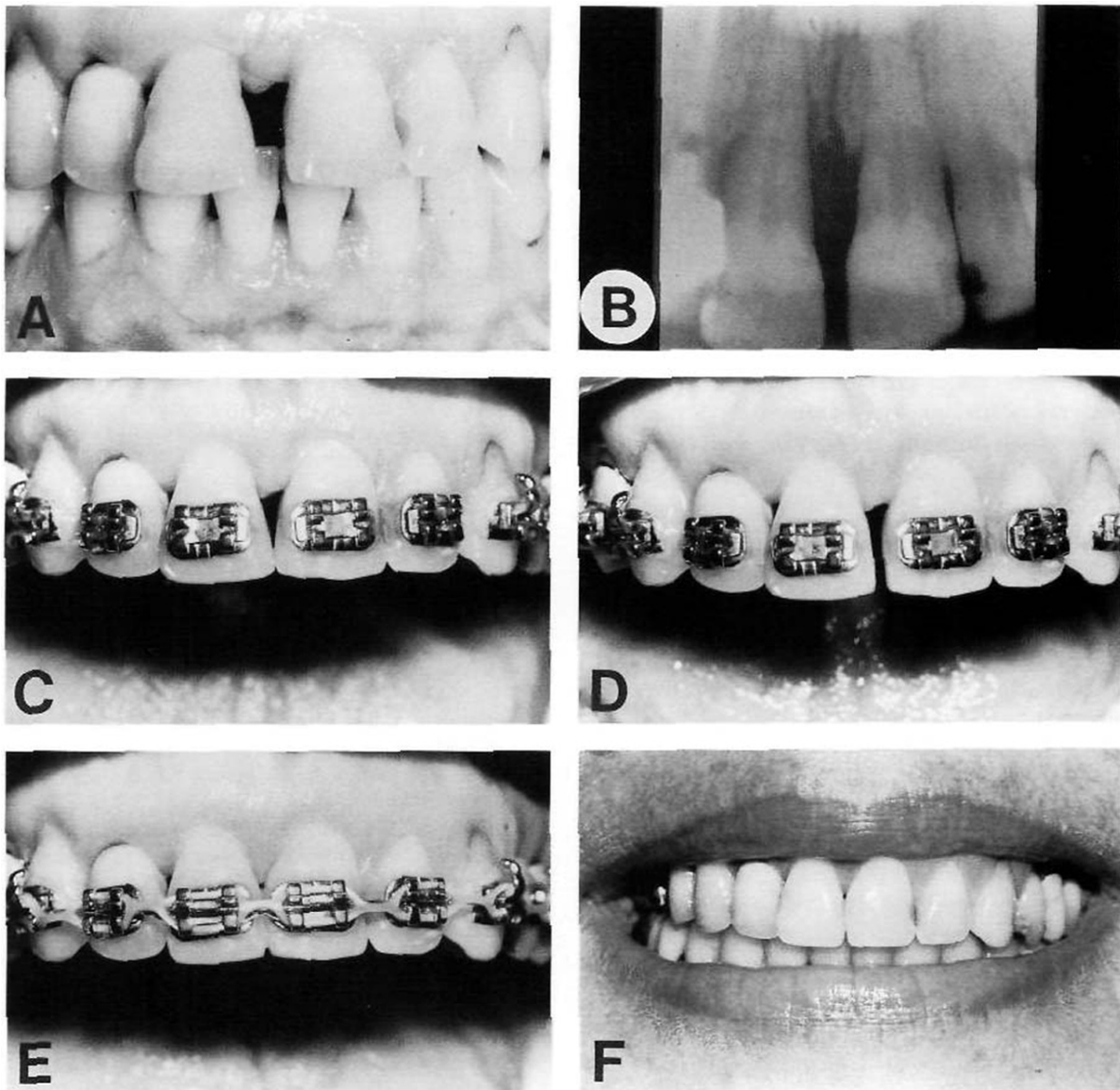


Figure 7. This patient had had significant periodontal disease resulting in interproximal bone loss and loss of the papilla between her maxillary central incisors (A, B). Although the diastema was closed, a space persisted between the central incisor papilla and contact (C). By reshaping the mesial surfaces of the centrals (D) and moving the teeth together (E), the papilla was “squeezed” into the contact area eliminating the unesthetic gap between the central incisors (F).

moves apically toward the papilla. Usually, the distal-incisal corners of the centrals also move apically (Fig 5E). This reflects the amount of incisal wear that had occurred before orthodontic treatment. These teeth usually require an incisal restoration to restore proper incisal contour.

A second possible cause of space above the interproximal contact of central incisors, is abnormal tooth shape (Fig 6). In some patients, the

crowns of the centrals are much wider at their incisal edge than at the cervical region. In these situations the contact between the incisors is located in the incisal 1 mm between the two centrals. This is an unusual contact relationship. Most contact areas between central incisors are 2 to 3 mm long. The best method of correcting this problem is to recontour the mesial surfaces of the central incisors (Fig 6C). The amount of enamel that must be removed from each tooth is

equal to half the distance between the mesial surfaces of the incisors at the level of the tip of the papilla. Usually this will be approximately 0.5 to 0.75 mm and does not penetrate into the dentin. After this diastema has been created, the space between the teeth is consolidated. As this occurs, the contact is lengthened and moved toward the papilla (Fig 6F).

In patients with advanced periodontal disease and destruction of the crestal bone between the central incisors, the papilla may be absent (Fig 7). This produces an unesthetic large gap after orthodontics. However, if the mesial surfaces of the central incisors are recontoured or flattened to lengthen the contact (Fig 7D), the contact will move apically toward the interproximal gingiva (Fig 7E). Although this may not eliminate the space completely, it may improve the situation substantially (Fig 7F).

Summary

This article has described three problems that adversely affect orthodontic esthetics and require interdisciplinary diagnosis and management by the orthodontist, periodontist, and often the restorative dentist. The key is to look for these unesthetic problems not only before orthodontic bracketing, but also during the finishing stages of treatment to determine if the solution will require additional tooth movement or periodontal surgery to achieve the most esthetic outcome.

References

1. Vig R, Brundo G. The kinetics of anterior tooth display. *J Prosthet Dent* 1978;39:502-504.
2. Willmar K. On LeFort I Osteotomy. *Scand J Plast Reconstr Surg* 1974;12:1-68.
3. Proffit W, Phillips C. Adaptations in lip posture and pressure following orthognathic surgery. *Am J Orthod Dentofac Orthop* 1988;93:294-302.
4. Rosen H. Lip-nasal aesthetics following LeFort I osteotomy. *Plast Reconstr Surg* 1988;81:171-179.
5. Sarver D, Weissman S. Long-term soft tissue response to LeFort I maxillary superior repositioning. *Angle Orthod* 1991;61:267-276.
6. Garguilo A, Wenz F, Orban B. Dimensions and relation at the dentogingival junction in humans. *J Periodontol* 1961;32:261-267.
7. Maynard J, Wilson R. Physiologic dimension of the periodontium fundamental to successful restorative dentistry. *J Periodontol* 1979;50:170-174.
8. Wilson R, Maynard J. Intracrevicular restorative dentistry. *Int J Periodont Restor Dent* 1981;4:35-50.
9. Kokich VG. Anterior dental esthetics: An orthodontic perspective. I. Crown Length. *J Esthet Dent* 1993;5:19-23.
10. Orban B. Indications, technique and postoperative management of gingivectomy in the treatment of periodontal disease. *J Periodontol* 1941;12:88-91.
11. Goldman H. The development of physiologic gingival contour by gingivoplasty. *Oral Surg* 1950;3:879.
12. Ramfjord S. Gingivectomy—its place in periodontol therapy. *J Periodontol* 1952;23:30-35.
13. Prichard J. Gingivectomy, gingivoplasty, and osseous surgery. *J Periodontol* 1961;32:257-262.
14. Kokich VG. Anterior dental esthetics: An orthodontic perspective. II Vertical relationships. *J Esthet Dent* 1993;5:174-178.
15. Kokich V, Nappen D, Shapiro P. Gingival contour and clinical crown length: Their effects on the esthetic appearance of maxillary anterior teeth. *Am J Orthod* 1984;86:89-94.
16. Kokich VG. Enhancing restorative, esthetic, and periodontal results with orthodontic therapy. In: Schlunger S, Youdelis R, Page R, Johnson R, editors. *Periodontal Therapy*. Philadelphia, PA: Lea and Febiger, 1990:433-460.
17. Chiche G, Kokich V, Caudill R. Diagnosis and treatment planning of esthetic problems. In: Pinault A, Chiche G, Esthetics in Fixed Prosthodontics. Quintessence, 1994:33-52.
18. Kokich VG. Anterior dental esthetics: An orthodontic perspective. III. Mediolateral relationships. *J Esthet Dent* 1993;5:200-207.
19. Reitan K. Tissue rearrangement during retention of orthodontically rotated teeth. *Angle Orthod* 1959;29:103-105.
20. Reitan K. Clinical and histologic observations on tooth movement during and after orthodontic treatment. *Am J Orthod* 1967;53:721-745.