

Improving aesthetics in CAD/CAM dentistry – anatomic shell technique

Authors Drs Nelson RFA Silva & Paulo Kano, Brazil, Dr Eric Van Dooren, Belgium, Dr Cristiano Xavier, Brazil, Dr Jonathan L. Ferencz, USA, Emerson Lacerda, Brazil

Figs. 1a–d The images show the frontal view of the clinical situation. Note the inadequate restoration on tooth 21 and the dark aspect of both tooth 11 and tooth 21 (a & b). Frontal view before and after the temporary restoration was fabricated for tooth 21 (c & d). The temporary crown was made with a lighter shade to create a more suitable substrate for the aesthetic evaluation after composite resin shells had been placed. Note the dark substrate of tooth 11.

_Abstract

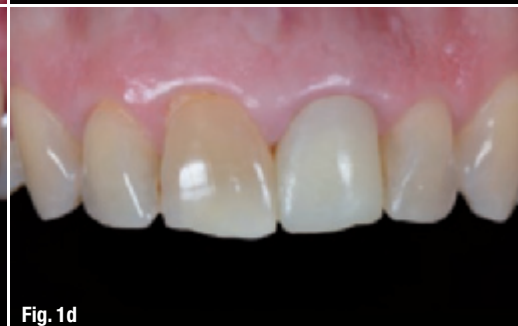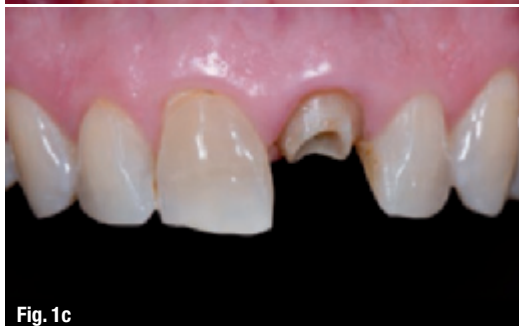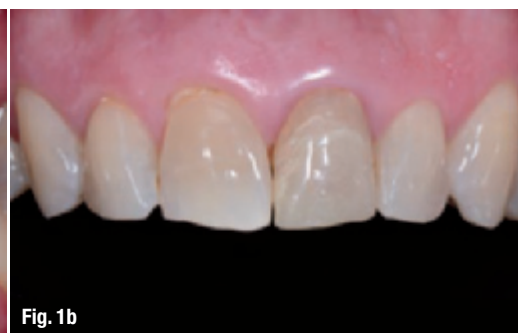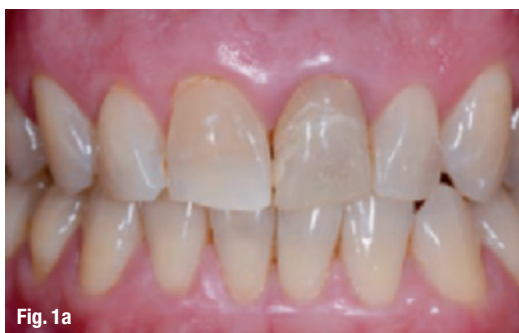Challenges in aesthetic dentistry frequently involve achieving natural and lifelike surface textures and ensuring the predictability of the final aesthetic results.

This article presents the anatomic shell technique (AST), which uses flowable composite resin shells as temporary veneers to guide the fabrication of the final restorations and to predict the aesthetic and morphological outcomes using CAD/CAM technology.

_Introduction

Lack of predictability regarding the final aesthetic outcome of CAD/CAM restorations is one of the major concerns among dental professionals, particularly in complex cases involving reconstruction using multiple units. Unfortunately, there is limited literature available on this topic. This article presents a technique in which light-cured flowable composite resin shells are used as temporary veneers prior to the final restoration to predict the aesthetic and morphological outcomes using CAD/CAM technology. A clinical case is used to describe and illustrate the clinical steps.¹

One of the challenges in aesthetic dentistry is achieving natural and lifelike surface textures.² Surface texture directly influences the colour value and saturation and the zones of light reflection and absorption. An anterior restoration that does not exhibit a surface texture and lustre that is comparable to the adjacent natural teeth will immediately appear to be out of place, particularly when the surface of the surrounding dentition is complex or heavily textured. The natural tooth surface is composed of horizontal and vertical concavities



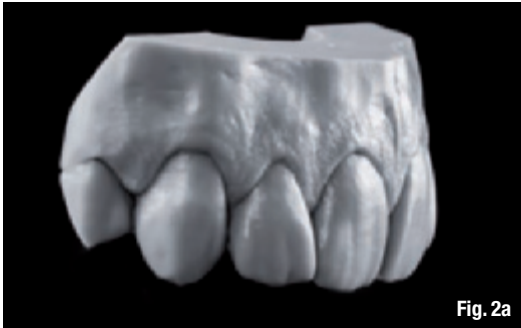

Fig. 2a



Fig. 2b

and convexities that vary in complexity and intensity from tooth to tooth. The ability to observe and replicate the surface texture and lustre to create an anterior restoration that is indistinguishable from adjacent natural teeth typically requires a highly skilled laboratory technician. However, if one could mimic the surface texture of adjacent natural tooth surfaces and use a milling machine to reproduce it, one could provide a very good aesthetic restoration without the need for a highly skilled laboratory technician. The goal of this article is to describe a novel approach that attempts to reproduce the complexities and nuances observed in the surface texture and lustre of natural teeth utilising the AST technique for CAD/CAM restorations.

At this point, it was decided to address the patient's aesthetic goals with porcelain veneers. To achieve a rapid aesthetic transformation, the treatment plan involved using digital dental technology together with a novel concept in which composite resin temporary veneers (composite resin shells) were utilised prior to the placement of the final restorations to predict the final aesthetic outcome and to provide lifelike texture.

Figs. 2a & b Image of the Hajto model showing the surface texture of the anterior teeth (a). Image of composite shells under polarised light. Note the opalescence of the composite shells when the photograph was taken under polarised light (b).

Figs. 3a-f Anatomic resin shell being positioned (a), polished (b) and luted (c) without etching and utilising a flowable composite. The texture obtained mimics the original texture of the Hajto model shown in Figure 2 (d-f).

Materials

IPS EmpressCAD Multi (leucite-reinforced glass-ceramic blocks; Ivoclar Vivadent) in shade A2 was selected for the final restorations. No impressions

Case description

The treatment described involved a 43-year-old patient seen at the clinic with the chief complaint of dark staining of his teeth from antibiotic therapy (particularly tooth 21; Figs. 1a-d). The patient stated that his appearance affected his ability to socialise and smile. The patient expressed an interest in having his teeth treated to improve both his appearance and his occlusion.

The clinical investigation showed a very dark root due to endodontic treatment, with compromised remaining coronal structure. The endodontic treatment was accepted and a fibre post was cemented using a dual-cure resin cement (Multilink Automix, Ivoclar Vivadent) according to the manufacturer's instructions, followed by temporisation. Tooth 11 also exhibited an abfraction lesion.



Fig. 3a

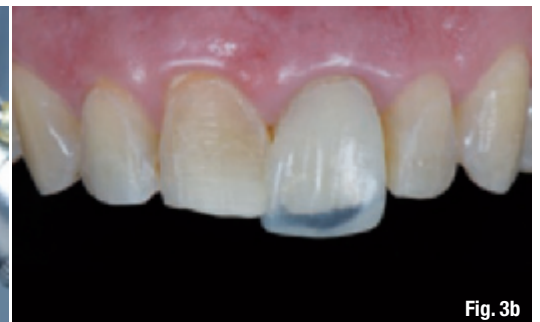

Fig. 3b

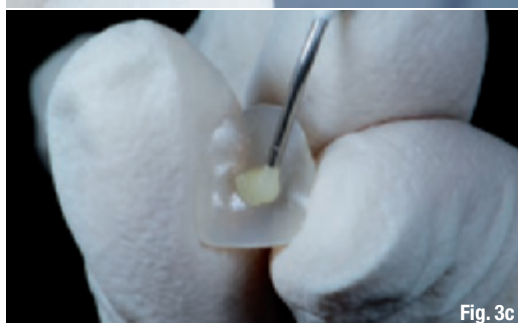


Fig. 3c

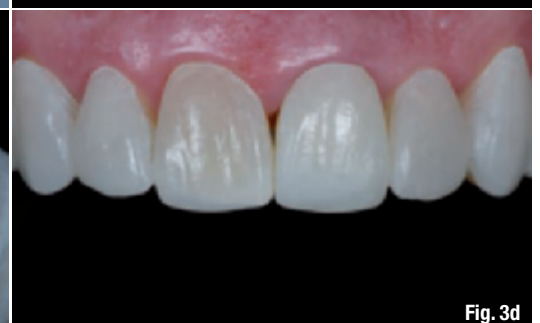

Fig. 3d

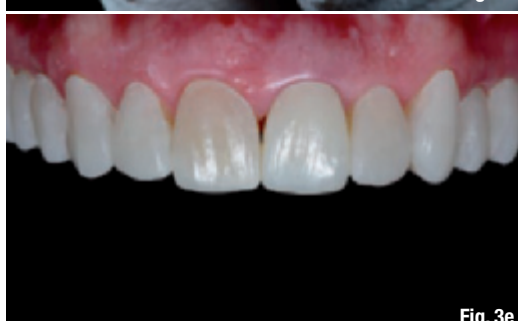

Fig. 3e

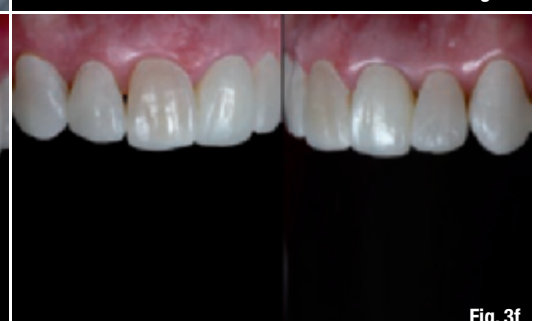

Fig. 3f



Fig. 4

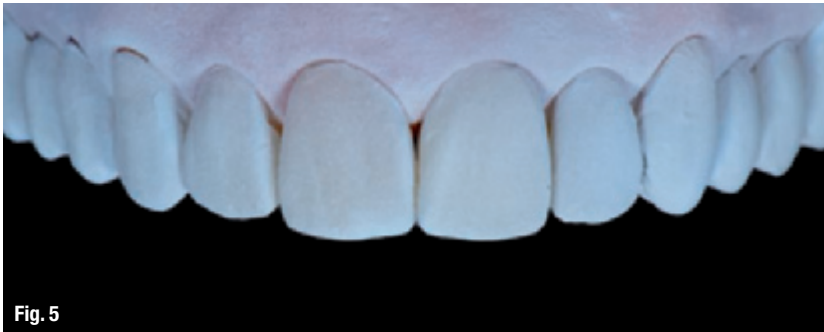

Fig. 5

Fig. 4_Initial photographs with composite shells temporarily cemented in place. The shade difference of tooth 11 is due to the dark substrate showing through the composite veneer.

Fig. 5_CEREC Optispray powder was applied in the patient's mouth to coat the teeth fitted with the polished anatomic composite resin shells.

Figs. 6a-e_A digital impression was taken after tooth preparation. The image shows the procedure for tooth 22 (a). The digital image acquired after preparation was

or diagnostic casts were used during the treatment planning and clinical procedures. The entire aesthetic treatment plan relied upon imaging (including photographs), prefabricated Hajto models³ and dental digital technology (CEREC AC with Bluecam, Sirona—CEREC Software 4.0).

_Description of the anatomic shell technique

The digital smile design protocol⁴⁻⁸ was used to determine the aesthetic needs of the patient. The patient, with the dentist's assistance, selected the shapes of the teeth that best suited him using digital photographs of natural smiles from a computer smile library.

After determining the ideal shapes and sizes from the digital smile design database, Hajto models³ were selected based on the previously determined tooth dimensions of the patient. Subsequently, a silicone index (Virtual, Ivoclar Vivadent) was produced from the labial surface of the anterior teeth of the Hajto model that best matched the patient (Figs. 2a & b). Hajto models are replicas of the ideal natural anterior dentition of males and females, with examples of different tooth shapes, sizes and surface textures.

_Composite resin shells

A light-cured flowable composite resin (Tetric EvoFlow Ivoclar Vivadent) was then carefully placed into the index to produce very thin composite shells that duplicated the shape of the model teeth. After complete polymerisation, the composite shells were gently placed intra-orally on the labial surfaces of the teeth and adjusted to obtain the best possible fit (Fig. 3a).

Once the best anatomic resin shell position was obtained, the shells were polished and luted without acid etching using flowable composite (Tetric EvoFlow, Ivoclar Vivadent) (Fig. 3d-f).

The clinician together with the patient evaluated the aesthetic outcome with the polished composite shells in place (Fig. 3d-f). Digital photographs were taken to analyse the symmetry between the teeth and the patient's face. Following the digital imaging analyses, small adjustments were performed at the interproximal embrasures. After completion of the aesthetic modifications and polishing steps, the patient was asked to give permission to proceed with treatment for his new smile (Fig. 4).

_Digital imaging

In order to facilitate the digital image capturing process, CEREC Optispray powder (Sirona; Fig. 5) was applied in the patient's mouth to coat the teeth restored with the composite resin shells. An intra-oral scanner (CEREC Bluecam) was then used to create a 3-D digital model of the full mouth with the temporary composite resin shells.

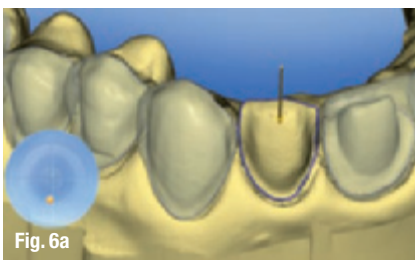

Fig. 6a

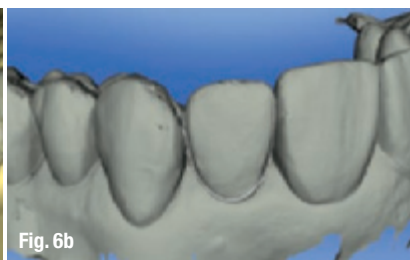

Fig. 6b

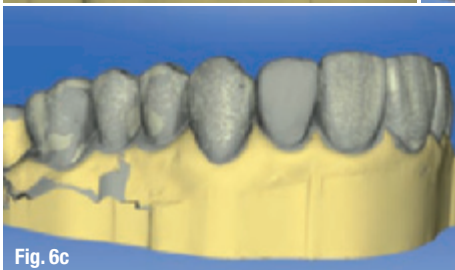

Fig. 6c

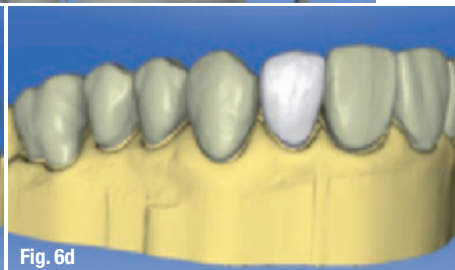

Fig. 6d




Fig. 6e

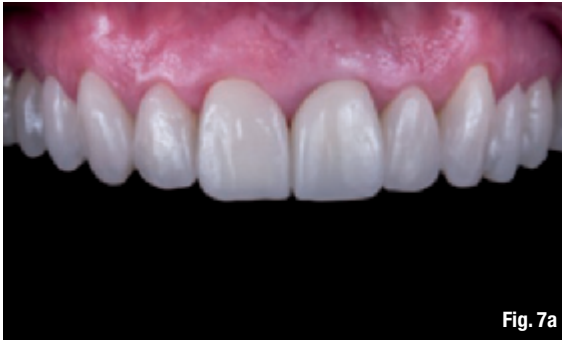

Fig. 7a

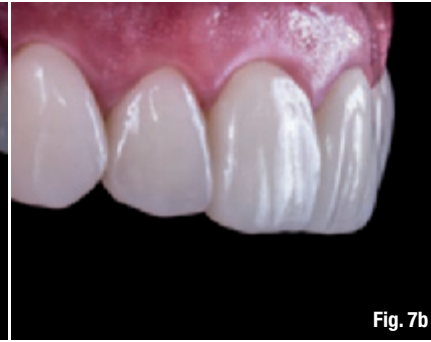

Fig. 7b

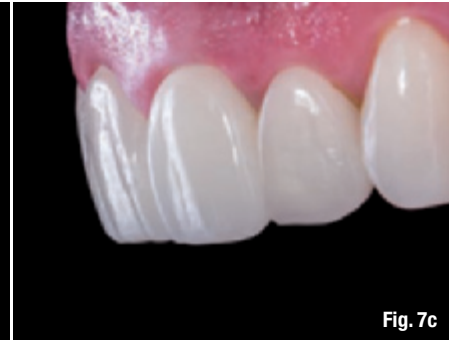

Fig. 7c

In this procedure, the composite shells help to predict the shape and the final aesthetic outcome of the milling process. They also serve as a guide to establish the amount of reduction necessary during tooth preparation. After the scanning process, therefore, the teeth were prepared using the composite resin shells as a reference to determine the amount of tooth reduction.

A digital impression was taken (CEREC Bluecam) after the preparations had been completed. The digital image acquired after preparation was merged and correlated with the digital image taken with the anatomic composite shell in place to generate the proper shape of the permanent veneers to be fabricated (Figs. 6a–e). The milling process was then initiated using a CEREC III milling unit equipped with CEREC Software 4.0.

After the milling process, the veneers were removed from the milling unit and visually inspected for potential flaws. The veneers were then tried-in, polished with 0.6 μ diamond paste and subsequently placed with Variolink Veneer Medium Value 0 (Ivoclar Vivadent) using the adhesive technique according to the manufacturer's instructions (Figs. 7a–c). In order to mask the dark shade of the tooth substrate, a staining agent (IPS Empress Universal Stains, Ivoclar Vivadent) was applied internally to each veneer prior to cementation.

Conclusion

The concept of chairside CAD/CAM restoration differs from conventional dentistry in that the restoration is typically luted or bonded in place on the same day, whereas conventional dental prostheses of larger size, such as crowns, involve the placement of temporaries for several weeks while a dental laboratory produces the restoration.¹ As the CAD/CAM restoration is bonded on the same day, the principles applied in predicting the final outcomes present unique challenges compared with conventional clinical procedures for any aesthetic treatment. The clinical case described here presented some limitations, as can be seen in the slight bulki-

ness of the final restorations and the straighter incisal edges of the two central incisors (Figs. 7a–c) compared with the composite shells (Figs. 3d–f). These differences were attributed to a software limitation, as no other anatomical/morphological modification was performed after the milling process had been completed. However, the final outcome using monochromatic blocks was acceptable and the clinical sequence presented here using AST shows a very simple and innovative way to predict the final outcome of an aesthetic treatment and suggests that CAD/CAM technology is a very attractive concept when one understands the materials science, machine capability and the limitations involved.

Editorial note: A complete list of references is available from the publisher.

merged and correlated with the digital image taken with the anatomic composite shell (b) in place to generate the proper shape (c & d) of the permanent veneers to be fabricated (e).

Figs. 7a–c—Photograph of the completed clinical case (a). The final texture produced by the milling machine (b & c) and the quality of the aesthetic result are satisfactory despite the use of a monochromatic ceramic block. The texture matches that of the buccal surface of the Hajto model (Fig. 2a) that was selected for this clinical case.

_about the authors

CAD/CAM

Nelson RFA Silva, DDS, MSc, PhD

(Federal University of Minas Gerais, Belo Horizonte), is an assistant professor at the New York University College of Dentistry.

Tel.: +55 31 8949 2405
nrfa.silva@gmail.com

Paulo Kano, DDS, is enrolled for an M.Sc. and is in private practice in São Paulo in Brazil.

Eric Van Dooren, DDS,

is a visiting professor at the University of Liège and is in private practice in Belgium.

Cristiano Xavier, DDS, is a professional photographer in Belo Horizonte in Brazil.

Jonathan L. Ferencz, DDS, is a clinical professor at the New York University College of Dentistry in the USA and in private practice in New York.

Emerson Lacerda, CDT, works in a laboratory in São Paulo.