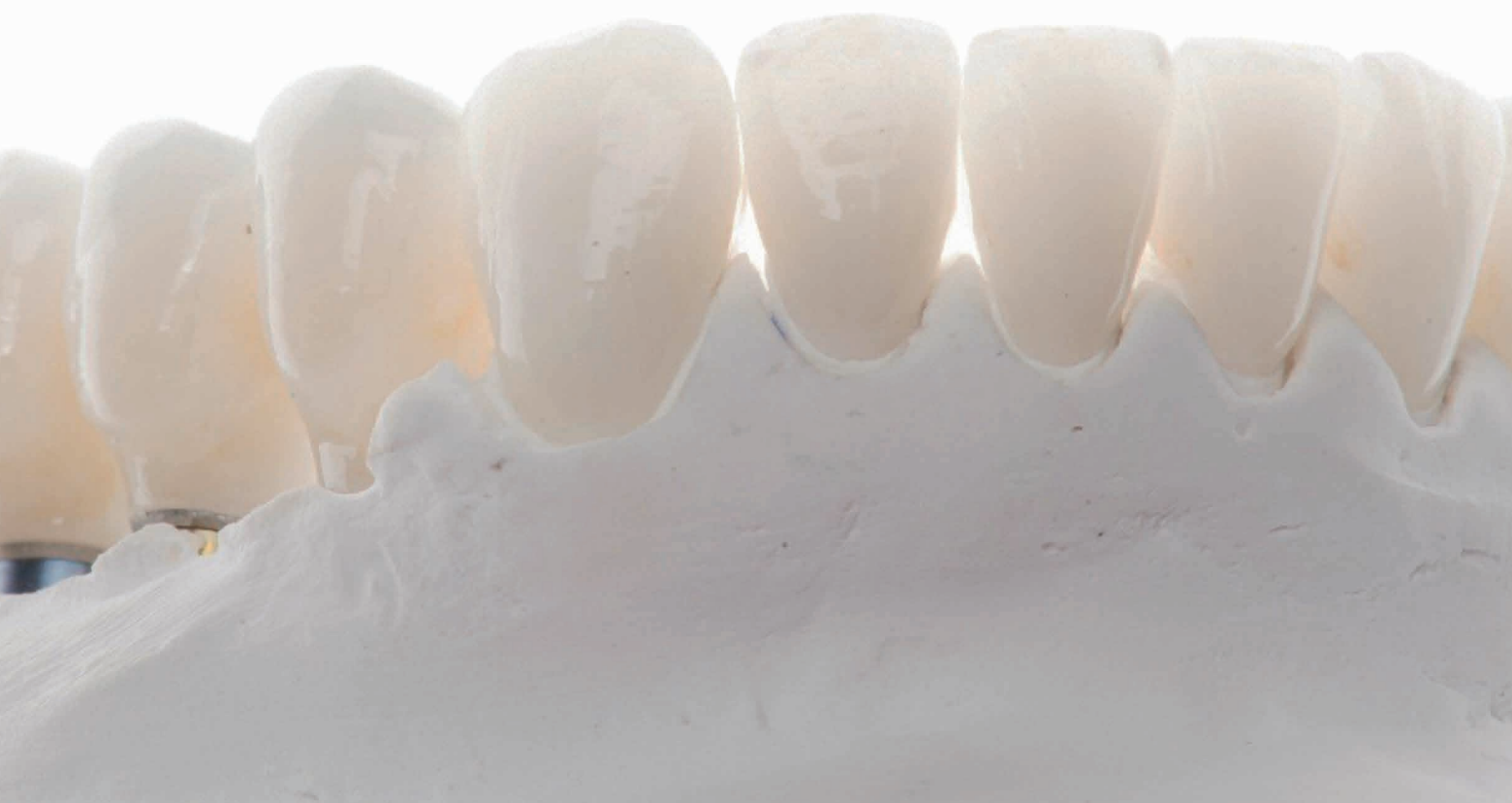
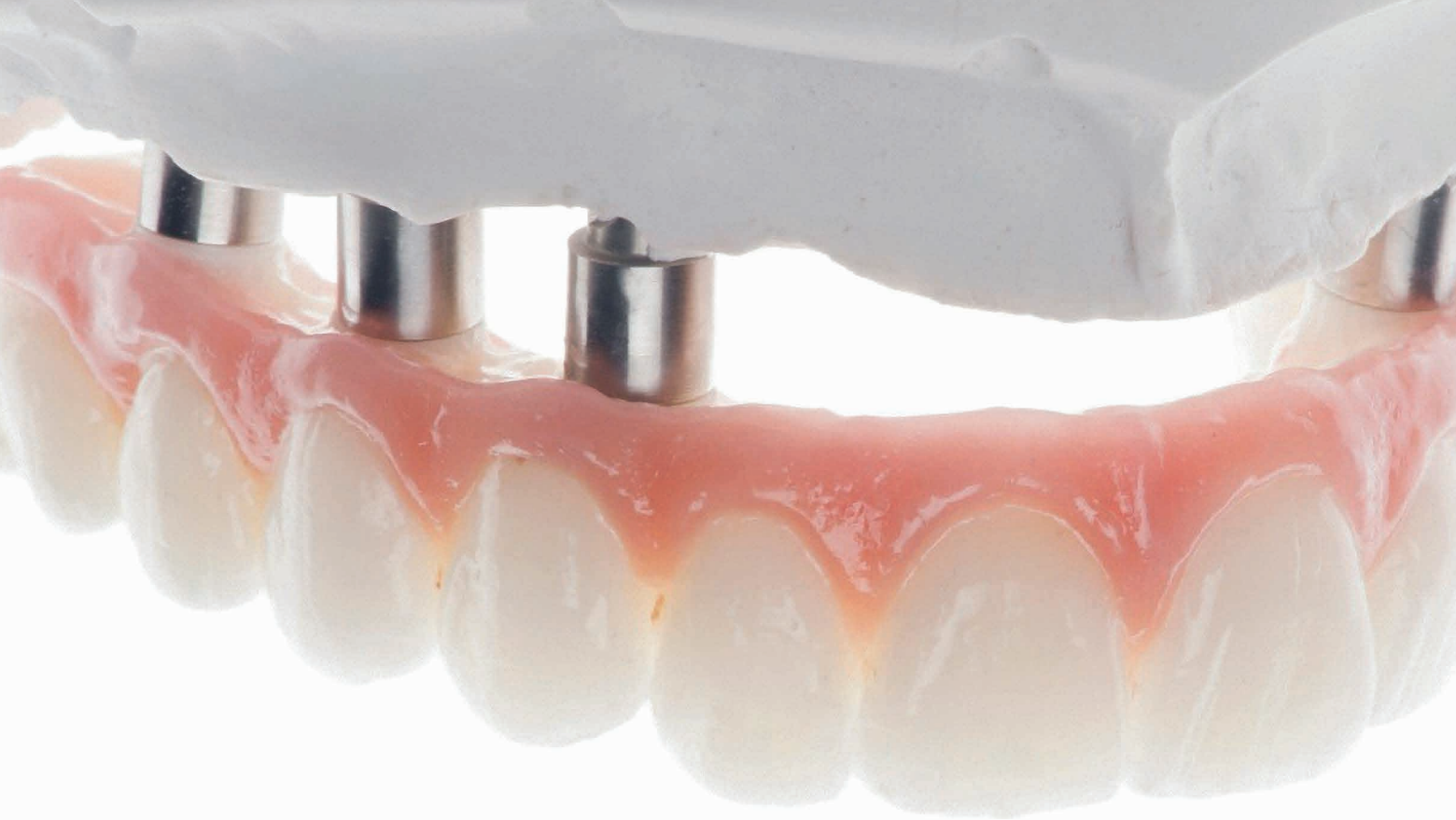


State of the Art

Esthetic Rehabilitation of a Patient with Severely Worn and Compromised Dentition

Somkiat Aimplee, DDS, MSc, FACP¹
Aram Torosian, MDC, CDT²
Sergio R. Arias, DDS, MS¹
Alvaro Blasi, DDS, CDT¹
Sung Bin Im, MDC, CDT, BS²
Gerard Chiche, DDS³

¹Esthetic and Implant Fellow, Ronald Goldstein Center for Esthetic and Implant Dentistry, Augusta University, College of Dental Medicine, Augusta, Georgia, USA.

²Master Dental Ceramist, Ronald Goldstein Center for Esthetic and Implant Dentistry, Augusta University, College of Dental Medicine, Augusta, Georgia, USA.

³Director, Ronald Goldstein Center for Esthetic and Implant Dentistry, Augusta University, College of Dental Medicine, Augusta, Georgia, USA.

Correspondence to: Dr Somkiat Aimplee, Ronald Goldstein Center for Esthetic and Implant Dentistry, Augusta University, College of Dental Medicine, 1430 John Wesley Gilbert Drive, Augusta, GA 30912 USA.
Email: draimpleecosmetic@gmail.com

This article depicts the use of high-strength all-ceramic restorations in the rehabilitation of a patient who had a severely worn dentition caused by dental attrition and compromised by dental caries.

CASE PRESENTATION

A 65-year-old man presented to the Center for Esthetic and Implant Dentistry at Augusta University. The patient's chief complaint concerned his loose anterior fixed dental prosthesis and the severely worn dentition. The initial clinical examination revealed generalized dental caries, short and thin clinical crowns, and root fracture of anterior restoration abutments due to dental attrition from bruxism and a constricted envelope of function (Fig 1). Both esthetics and function were compromised.

The key factors in rehabilitating a severely worn dentition such as this are based on understanding the etiology, diagnosing the problem properly, designing and sequencing the treatment plan, and finally selecting the proper restorative material.

Etiology and Diagnosis

Understanding the etiology of the disease is crucial because it will affect the treatment plan, restoration design, material selection, and prognosis. The differential diagnosis of worn dentition can be made by analyzing the nature and location of the wear pattern.¹⁻³ This patient's teeth displayed wear facets mostly on the occlusal surfaces that coincided with the pathways of grinding, which is a typical characteristic of patients with bruxism. The patient's occlusion also displayed a steep anterior guidance with a constricted envelope of function and an irregular occlusal plane caused by the loss of posterior tooth support.⁴

Treatment Plan

The etiology of the worn dentition dictates the treatment plan to a large extent and affects the prognosis, especially when considering the amount of occlusal load and the pathways of function.² A worn dentition caused by den-

tal attrition has a relatively high functional-risk prognosis. Therefore, high-strength all-ceramic restorations must be utilized with a meticulous prosthesis design and harmonized occlusion.⁵

Treatment Sequence

Esthetic Evaluation

The seven-step esthetic analysis was utilized; it consists of evaluation of the smile line, incisal profile, length, proportion, tooth-to-tooth proportion, gingival outline, and desired fullness.⁶ The information from the analysis is used to create an esthetic design as well as to fabricate the surgical guide and finally the immediately loaded prosthesis.⁷

Diagnostic wax-up. The wax-up assists in the creation of pleasing proportions, display, and length of the anterior teeth. It also gives a preview of the definitive restorations and allows the patient to provide input on the design of the prosthesis.⁸

Functional Evaluation

Anterior guidance. Anterior guidance was designed to provide sufficient disocclusion of the posterior teeth in harmony with the envelope of function.⁴

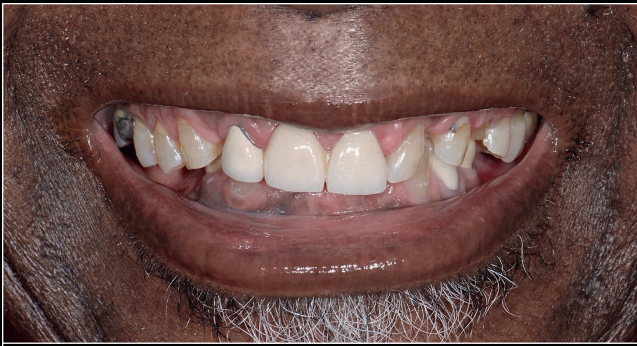Three functional steps included: (1) mutually protected occlusion with (2) moderate guidance that will determine (3) the new vertical dimension of occlusion.

Surgical Phase

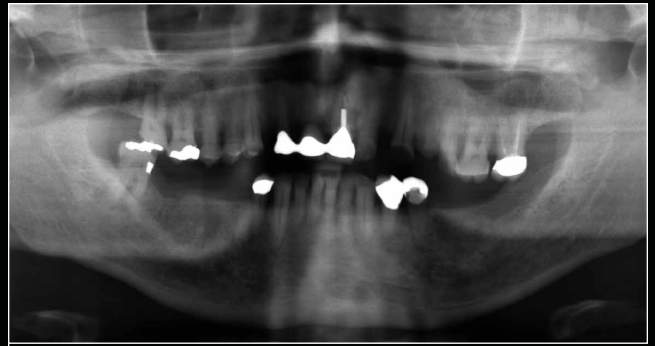
Tooth extraction and bone-reduction procedures were performed in the maxillary arch utilizing a surgical guide fabricated from the diagnostic wax-up to create sufficient space for the framework material of the high-strength ceramic restorations.

Implant Placement

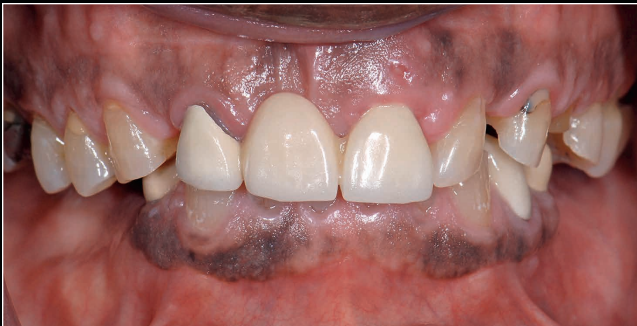Implants were placed in the maxillary and mandibular arches (Replace Select, Nobel Biocare) according to the prosthesis form and functional design. On the maxillary arch, multiunit abutments were seated and immediately loaded with a screw-retained prosthesis. A conventional two-stage loading approach was utilized for the mandibular arch (Figs 2 and 3).⁹



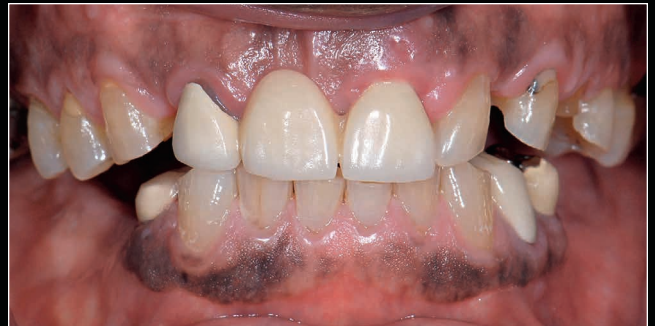1a



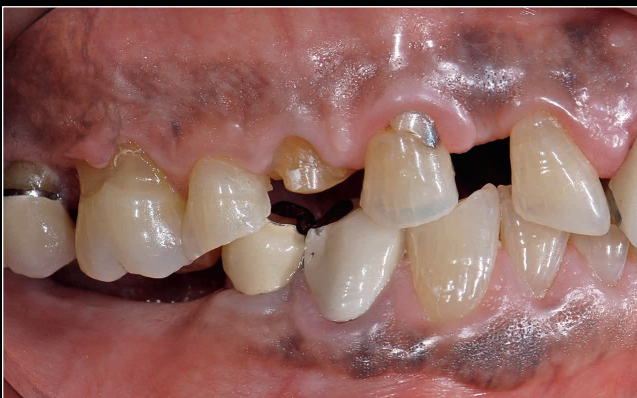1b



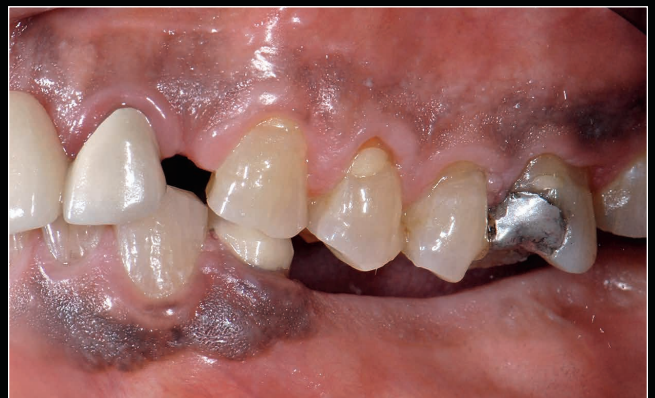1c



1d



1e



1f

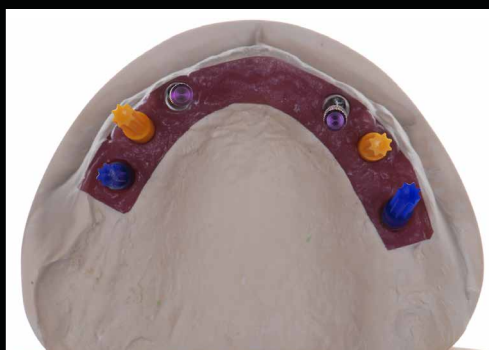Figs 1a to 1f Preoperative situation showing severely worn dentition caused by dental attrition and biologic failure caused by dental caries.

Fig 1a Close-up view of the patient's smile.

Fig 1b Panoramic radiograph.

Figs 1c and 1d Intraoral frontal views in centric occlusion and protrusion.

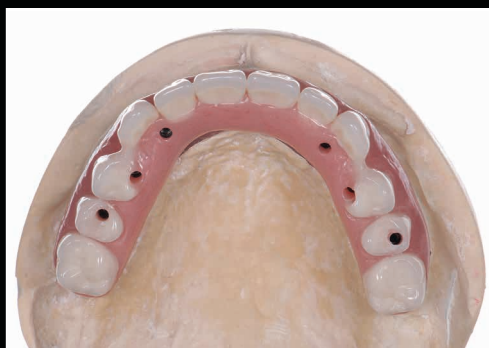Figs 1e and 1f Intraoral lateral views in centric occlusion.



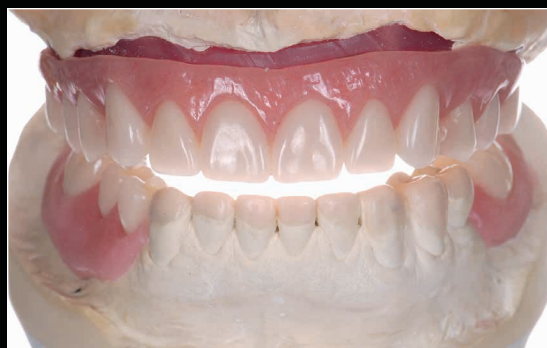2a



2b

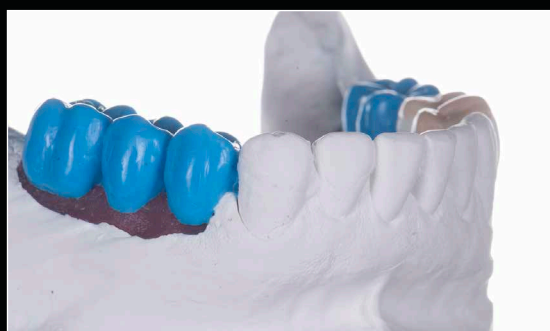


2c

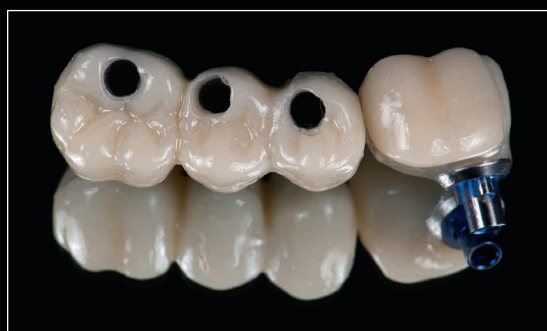

2d

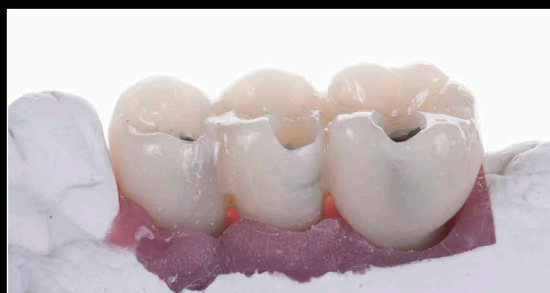Figs 2a to 2d Fabrication and delivery of maxillary implant-supported screw-retained immediately loaded interim prosthesis.



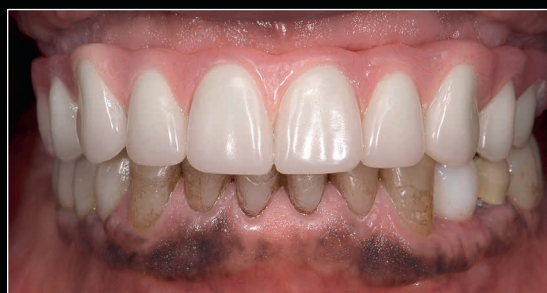3a



3b

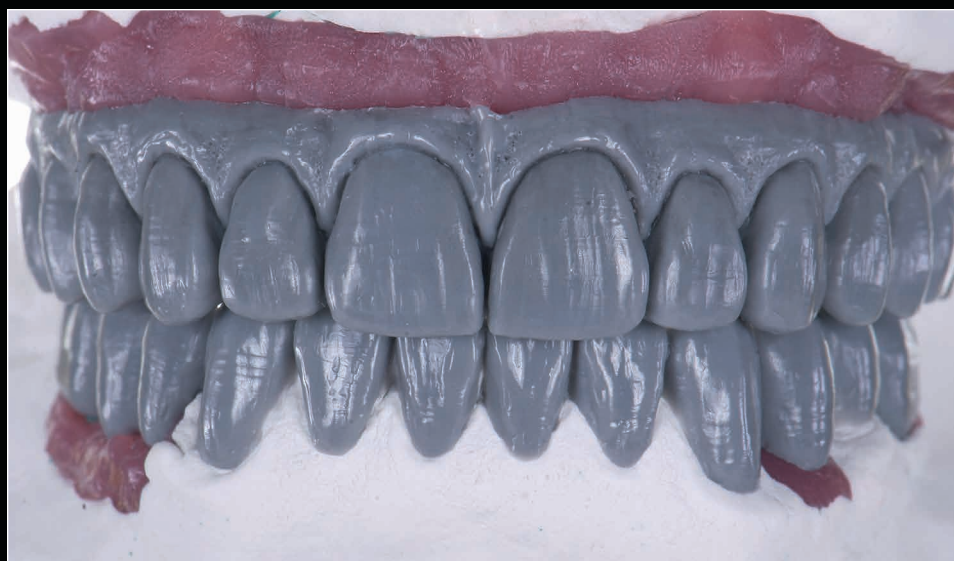

3c

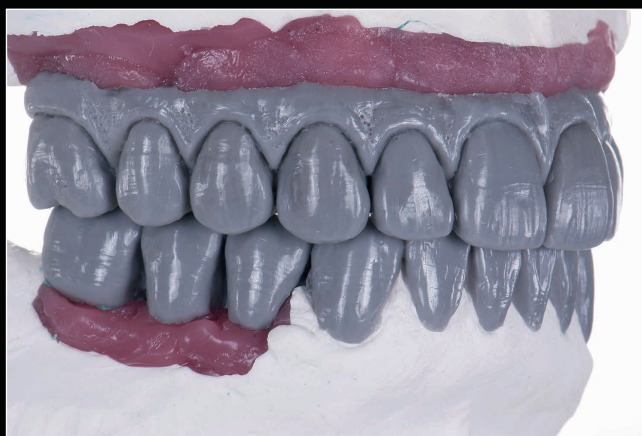

3d

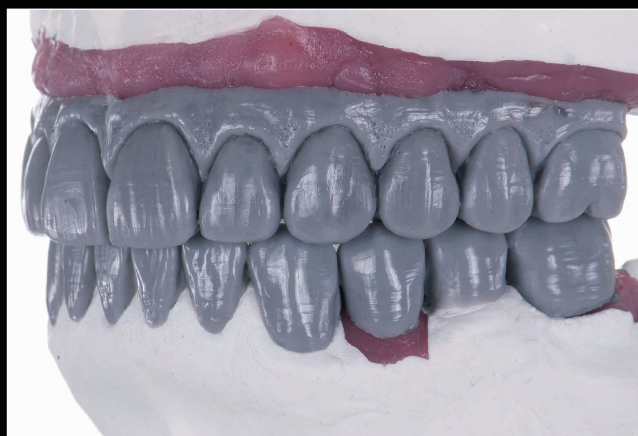Figs 3a to 3d Mandibular implant-supported screw-retained interim prosthesis.



4a



4b



4c

Figs 4a to 4c Diagnostic wax-up according to the esthetic design evaluation of the interim prosthesis.

Definitive Diagnostic Wax-up

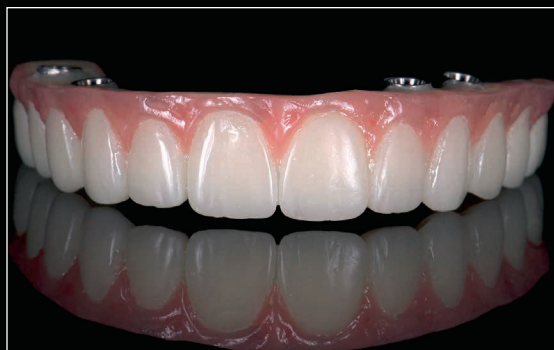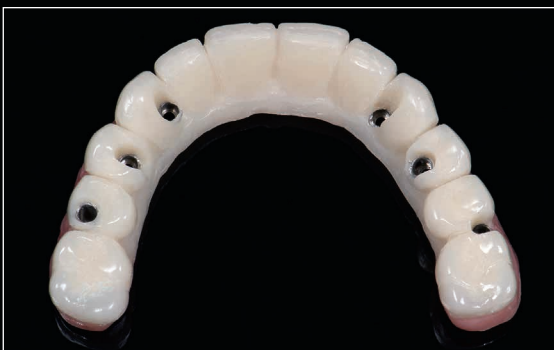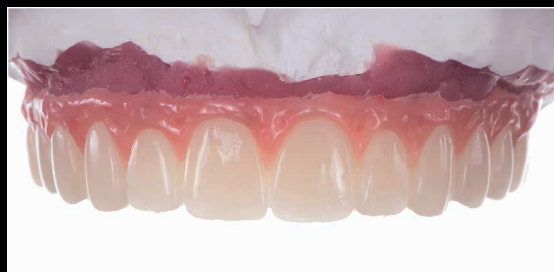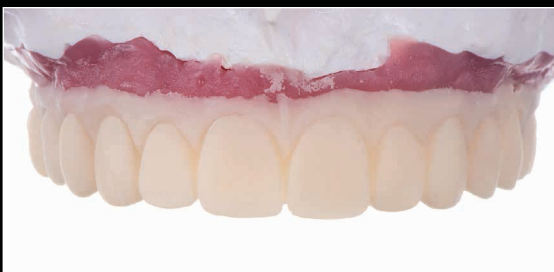The corrected esthetic design of the interim prostheses was transferred to the new diagnostic cast after the hard and soft tissues healed. The definitive diagnostic wax-up was completed in harmony with the smile line and posterior occlusal plane. A mutually protected occlusion was used (Fig 4).

Provisional Restorations

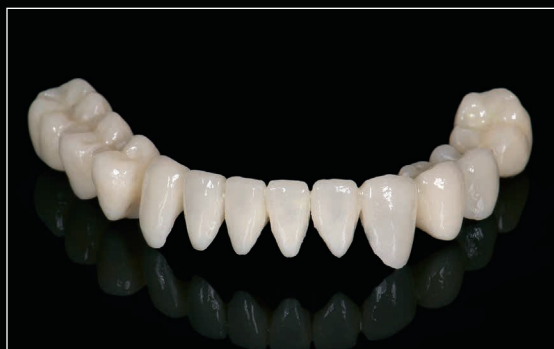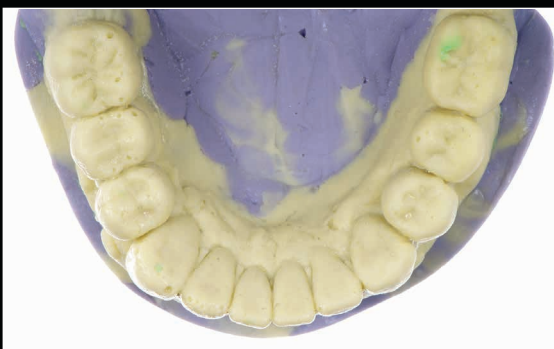The maxillary screw-retained provisional and mandibular shell provisional were fabricated with a polymethyl meth-

acrylate (PMMA) cutback and layering technique (New Outline, Anaxdent) by duplicating the diagnostic wax-up (Figs 5 and 6).

The mandibular teeth were prepared (Fig 7a), and mandibular provisional restorations were relined with PMMA (Jet A1, Lang Dental) and finished. Maxillary and mandibular provisional restorations were seated, and esthetics and occlusion were verified and adjusted as needed (Fig 7b). The soft tissue profiles for the definitive restorations would be created using the provisional restorations as a reference.



Figs 5a to 5d Duplication of the diagnostic wax-up and fabrication of the maxillary screw-retained provisional prosthesis with cutback and layering technique (New Outline, Anaxdent).


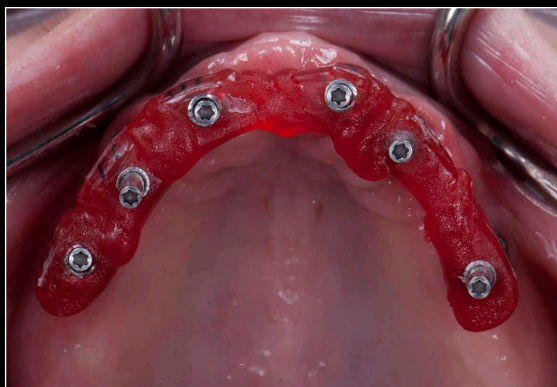


Figs 6a and 6b Duplication of the diagnostic wax-up to fabricate the mandibular shell provisional prosthesis.

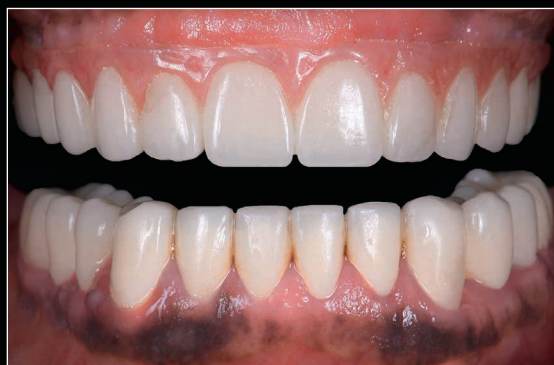
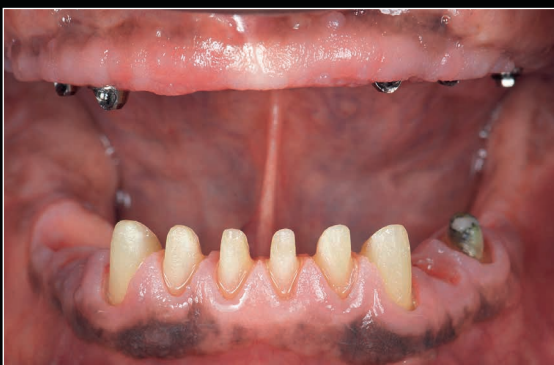
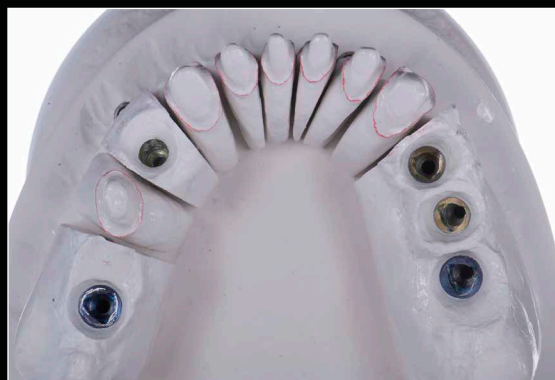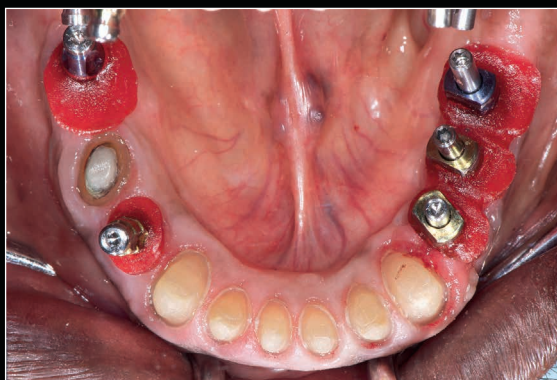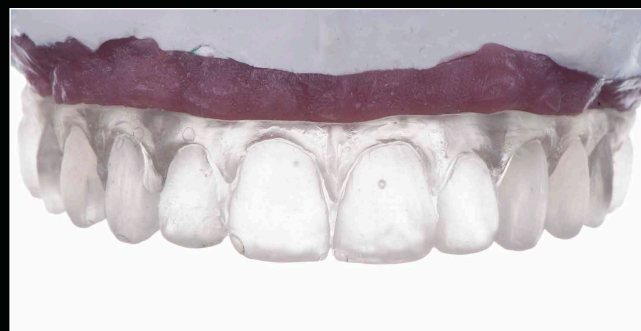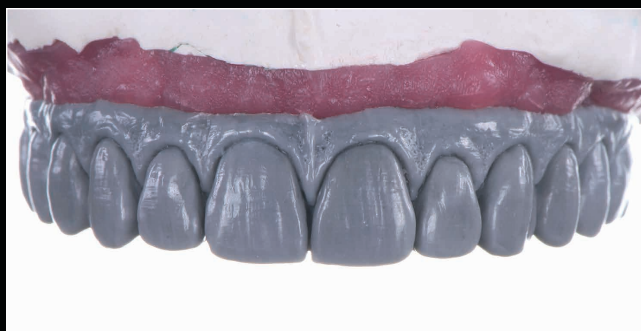Fig 7a Maxillary multiunit abutments and mandibular anterior teeth preparation.

Fig 7b Maxillary and mandibular provisional restorations.



Figs 8a to 8d Open-tray impression of the maxillary implants and mandibular implants/teeth preparation.

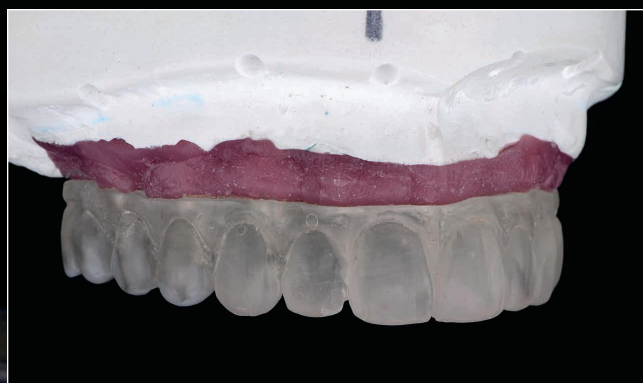

Figs 9a and 9b Framework prototype duplicated from the diagnostic wax-up and cross-articulated with the provisional/working casts.

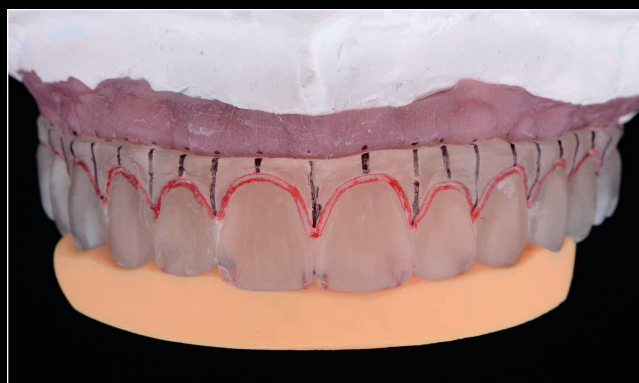
Final Impression

Polyvinyl siloxane (Flexitime, Heraeus Kulzer) final impressions were made in closed trays to fabricate verification jigs with open-tray impression coping, and open-tray impressions were made to provide working casts with maximum

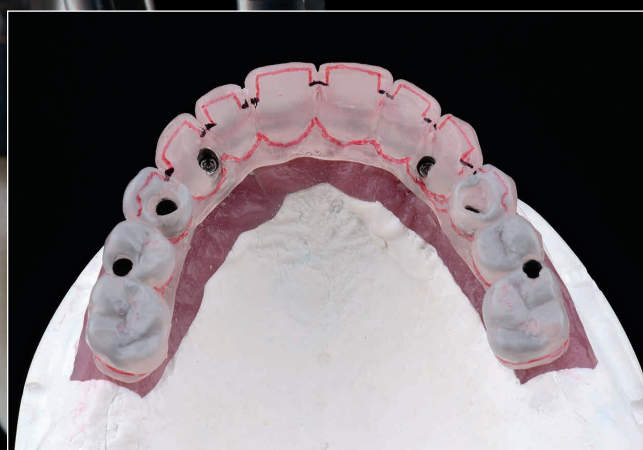accuracy (Fig 8).^{10,11} The maxillary framework prototype was duplicated in clear acrylic resin from the diagnostic wax-up that was evaluated in the provisional phase, and cross-articulation of the prototype, provisional, and working casts was performed (Fig 9).¹²



10a



10b



10c

Fig 10a Maxillary prototype duplicated in clear acrylic resin.

Fig 10b Gingival areas marked to control cutback.

Fig 10c Lingual cutback design for maximum support.

Framework Design

A silicone matrix was made of the incisal edges of the anterior teeth to control the cutback of framework design (Fig 10). The cementoenamel junctions (CEJs) and gingival areas were marked with a thin marker to guide and provide an outline for the step-by-step controlled cutback. The tooth shade was determined using the Vita 3D shade guide system (Fig 11a). The gingival shade was determined using the Noritake shade and color guide (Fig 11b).

Photographs were taken with multiple pink color tabs to determine pink, dark pink, orange, and bright areas for natural gingival color reproduction during the ceramic stages.

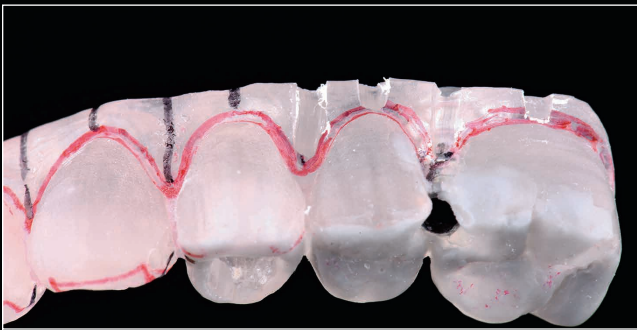
The gingival area of the duplicated prototype was prepared with 0.5-mm depth-cutting burs to control the cutback and achieve a uniform design. Following the cutback of the gingival area, the tooth surface was marked with a thin marking pen and divided into thirds. Similar to the gingival area, the tooth surface was reduced with 0.5-mm depth-cutting burs to achieve a uniform thickness (Fig 12).

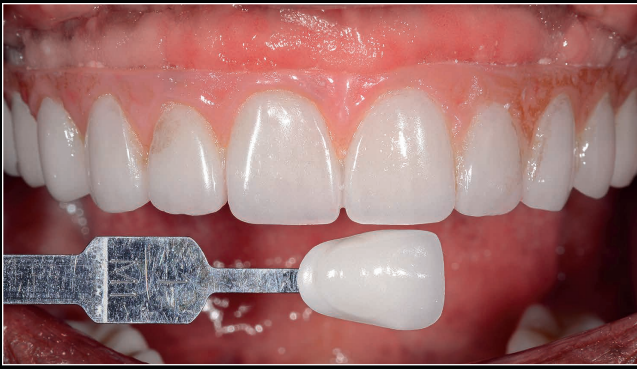

Fig 11a Tooth shade is determined using the Vita 3D shade guide system.

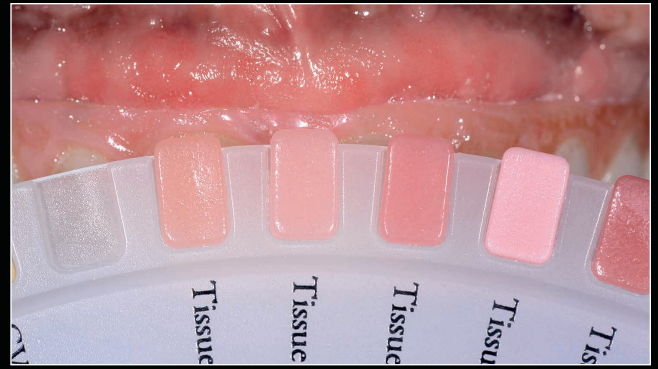

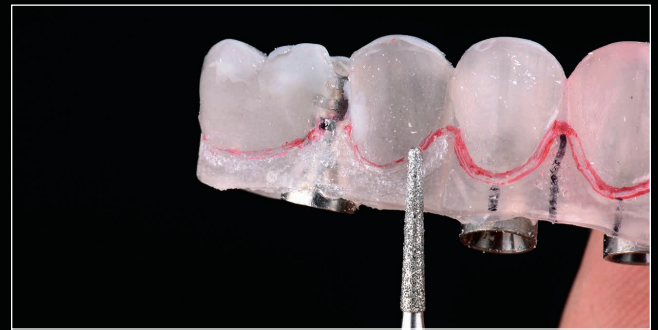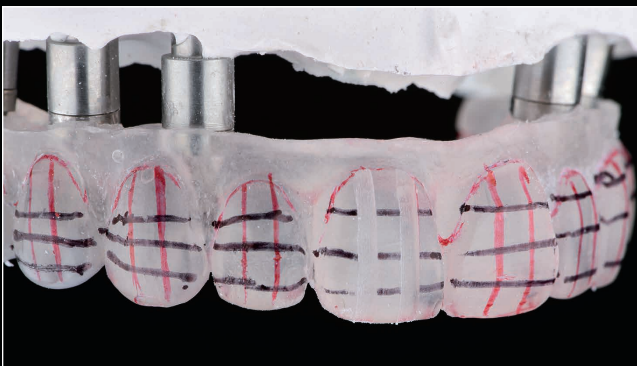
Fig 11b Gingival shade is determined using the Noritake shade and color guide.




12a



12b

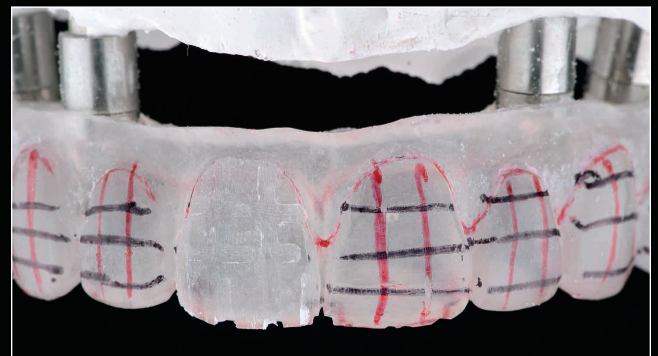


12c



12d

Figs 12a to 12e Controlled preparation of the gingival and tooth areas with depth-cutting burs.



12e

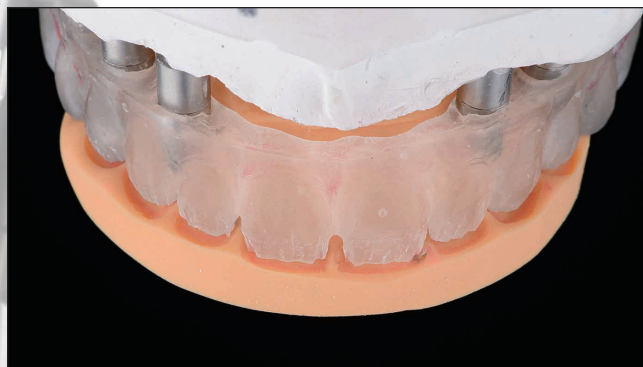

Fig 13 Cutback design checked against a silicone matrix to verify reduction.

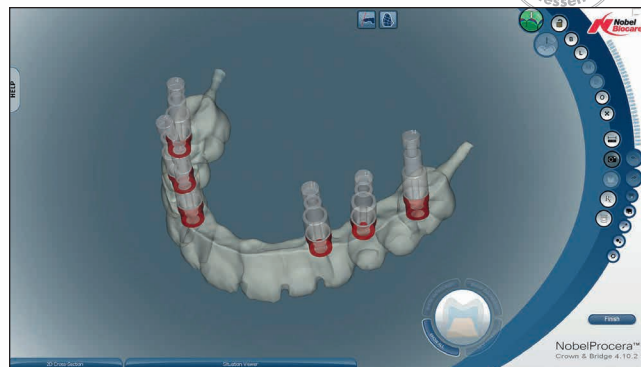

Fig 14a Scanned framework prototype in the design module of the Procera System.

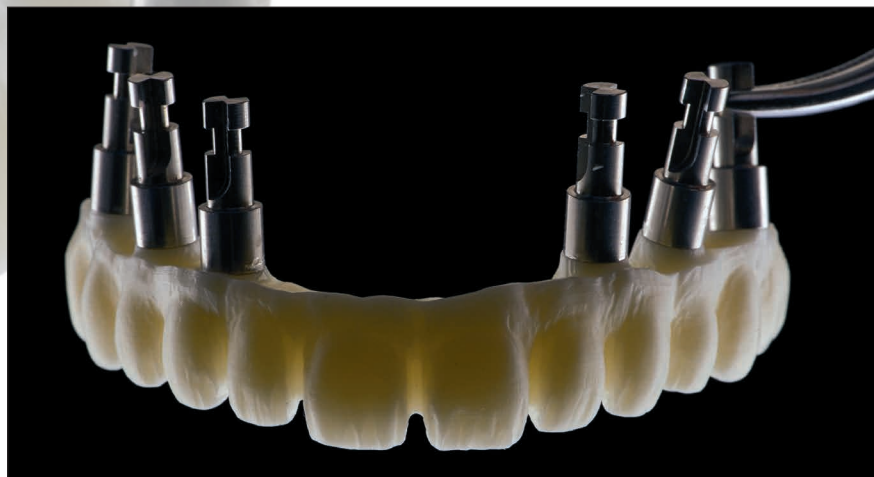

Fig 14b Milled and finished framework.

Framework Material Selection and Fabrication

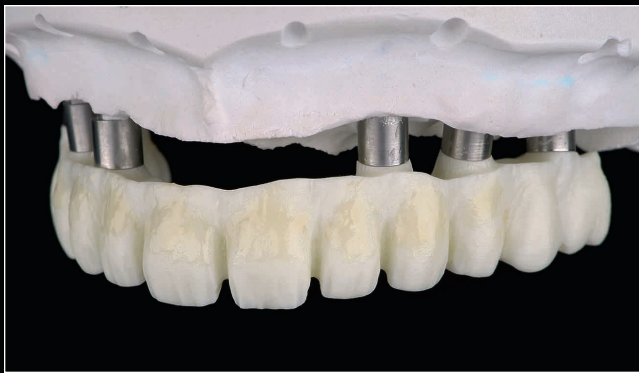
Due to the patient's high occlusal load, monolithic zirconia was selected for the definitive restorations and fabrication planned as follows:

- The maxillary monolithic zirconia framework with only minimal cutback was fabricated through CAD/CAM technology (Procera, Nobel Biocare) using the framework prototype as a reference and layered with feldspathic porcelain (CZR, Noritake).^{13–30}
- Mandibular posterior monolithic zirconia restorations also were fabricated through CAD/CAM technology (Procera) using the wax-up as a reference with external staining. For the anterior restoration, zirconia copings layered with feldspathic porcelain were used (Ceramien ZR [CZR], Noritake).⁵

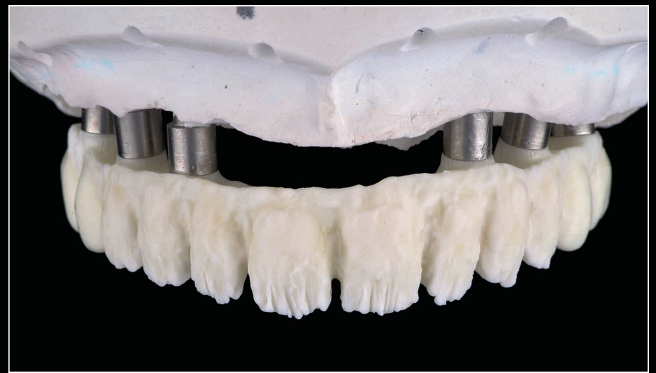
Ceramic Application

The maxillary acrylic resin framework prototype was checked using the silicone matrix to verify adequate reduction (Fig 13), after which the prototype was used to scan and copy mill the definitive framework, which was then prepared for ceramic application (Fig 14).

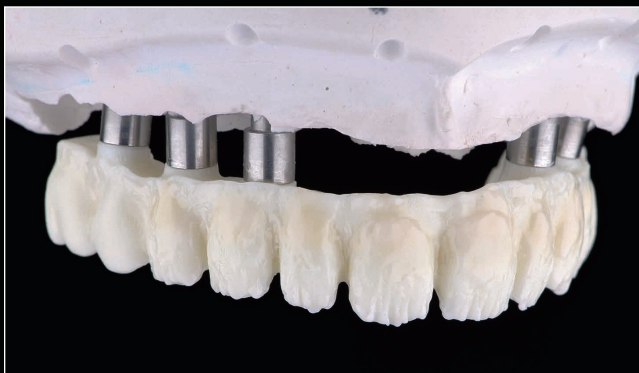A wash bake was carried out using opaque dentin. In the second bake, additional opaque dentin was applied to mimic internal structures and create color. In the third bake, dentin was used to create internal mamelon effects and was covered with enamel to achieve a natural look. After an internal stain bake, the luster layers and pink gingival ceramic were used to create natural contours of the teeth as well as the gingiva. In the next bake, more external modifier luster and gingival ceramic were applied to achieve a lifelike appearance (Fig 15).



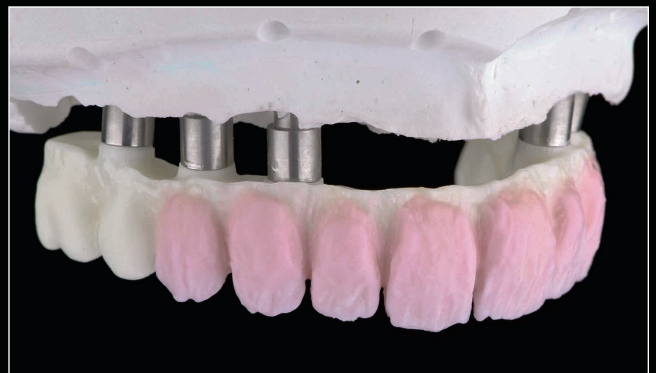15a



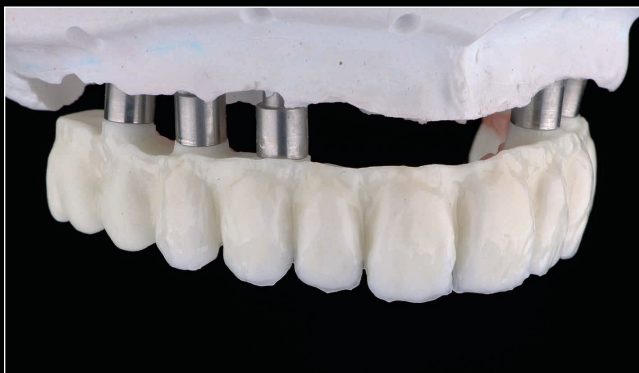15b



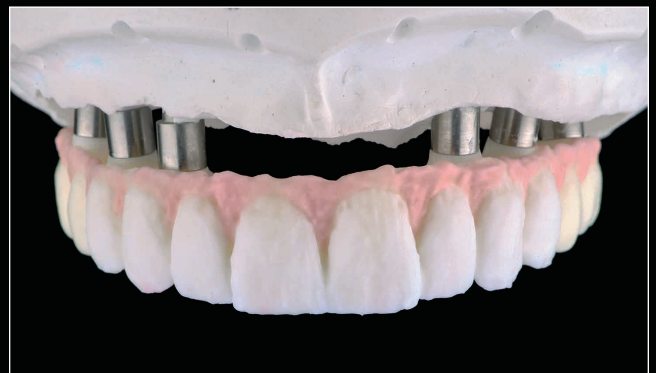15c



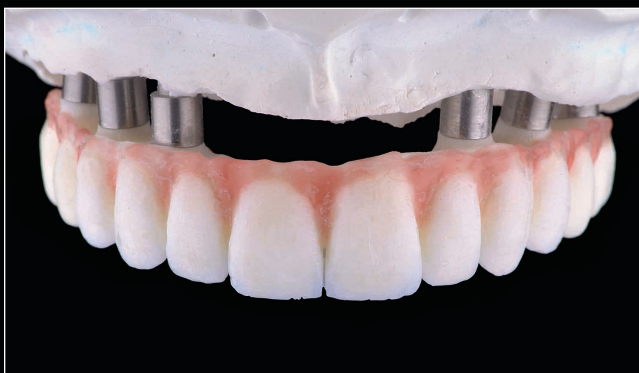15d



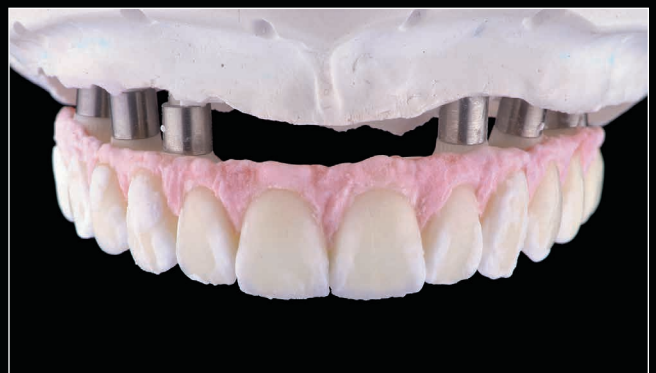15e



15f



15g



15h

Figs 15a to 15h Ceramic application steps.

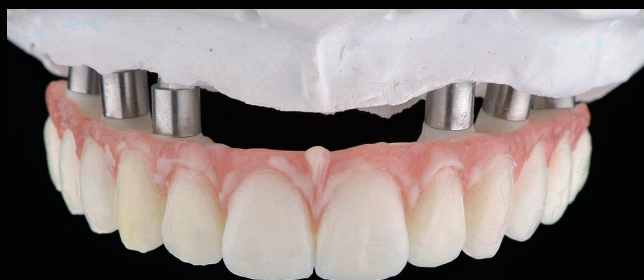

Fig 16a Wax simulation before the final bake.

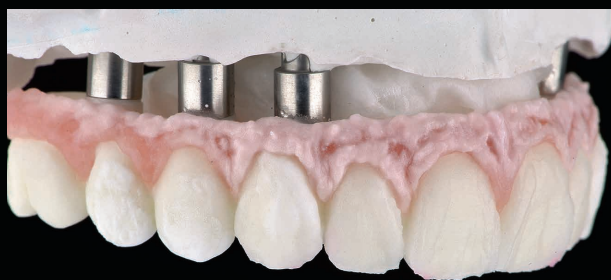
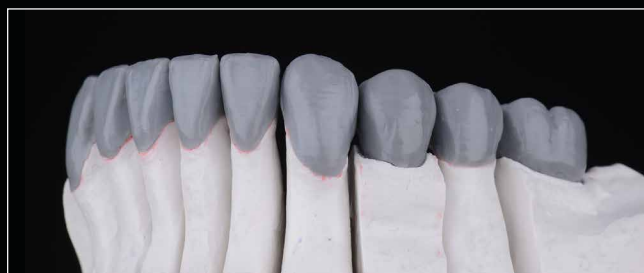
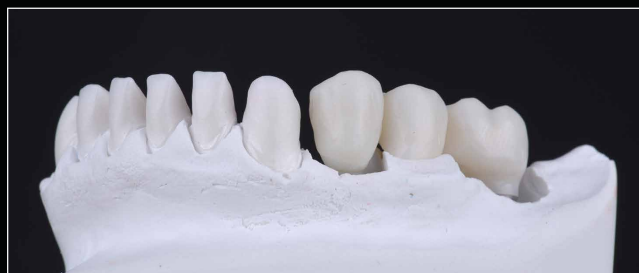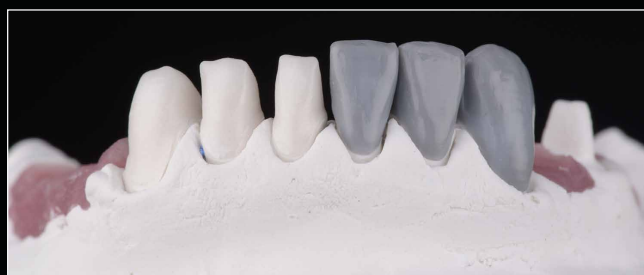Fig 16b Final contour bake.



17a



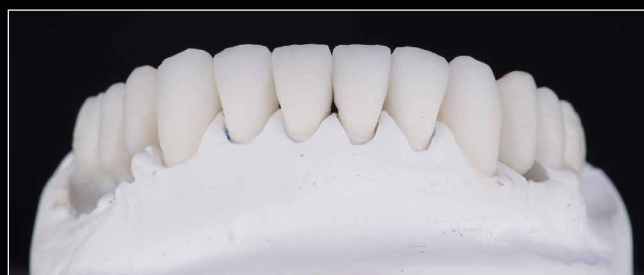17b



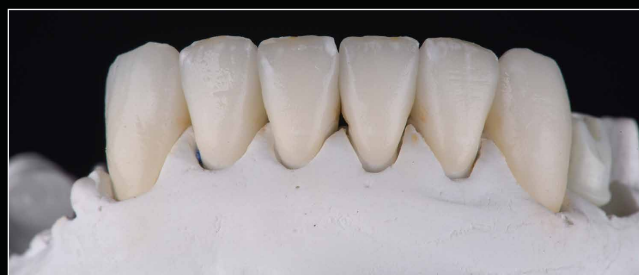17c



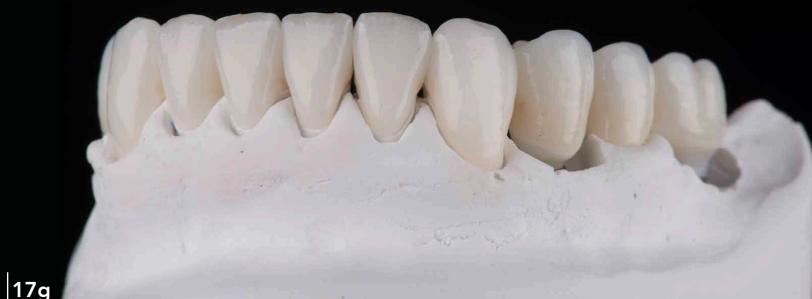17d



17e

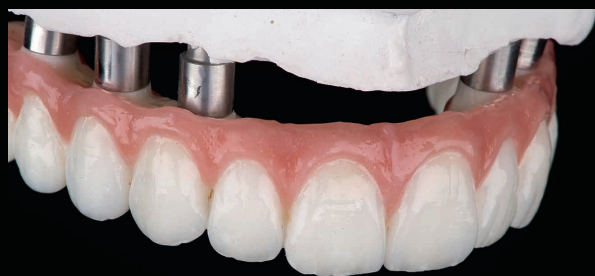

17f

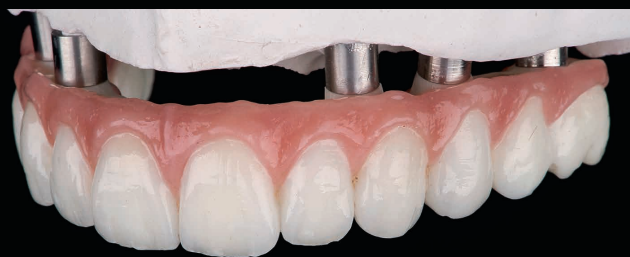

17g

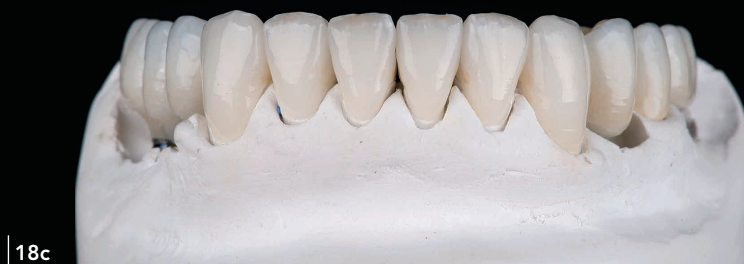Figs 17a to 17g Mandibular crowns waxing and ceramic application steps.



18a

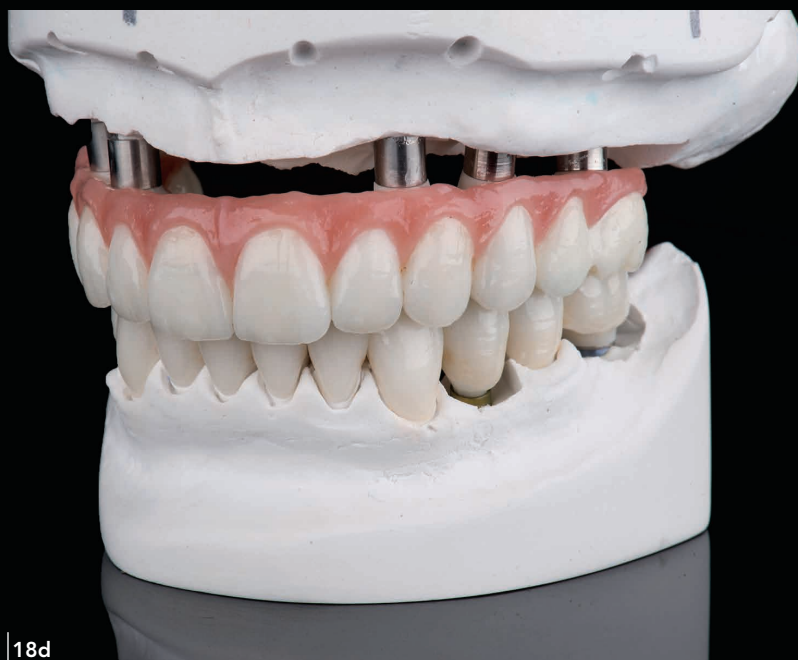

18b



18c

Figs 18a to 18d Finished restorations.



18d

Prior to the final contour bake, wax was applied to provide a preview of the final esthetics of the maxillary zirconia prosthesis (Fig 16a). Note that it is helpful to photograph this, and after steaming the wax (Fig 16b) have the image on the screen when applying the final layers of gingival

and tooth ceramic. Mandibular restorations were created with layering and monolithic zirconia ceramic (Fig 17). The final restorations showing morphologic adjustments and mechanical polishing are shown in Fig 18.



Fig 19a Mandibular anterior crowns were air abraded with 30-µm silica particles (Rocatec Soft, 3M ESPE).

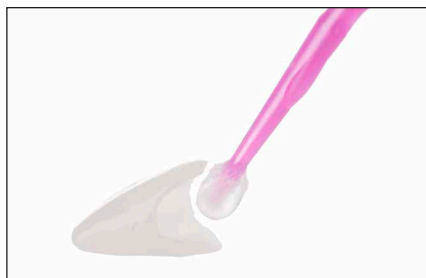

Fig 19b Ceramic primer (Clearfil, Kuraray Noritake) is applied.

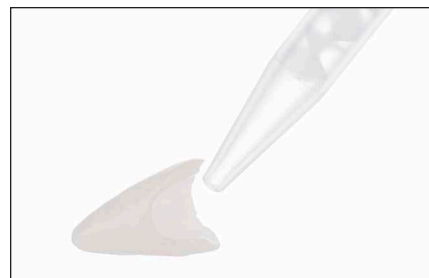

Fig 19c Resin cement (Panavia SA, Kuraray Noritake) is applied.

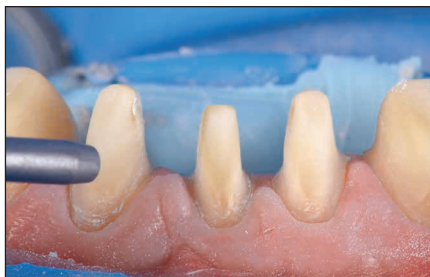

Fig 19d Mandibular anterior prepared teeth are air-particle abraded.

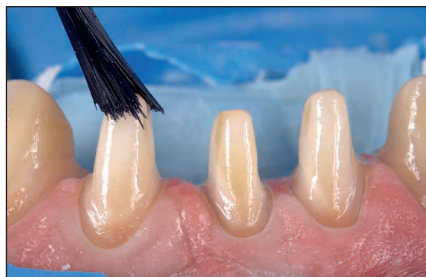

Fig 19e Self-etching adhesive (Clearfil SE Bond 2, Kuraray Noritake) is applied.

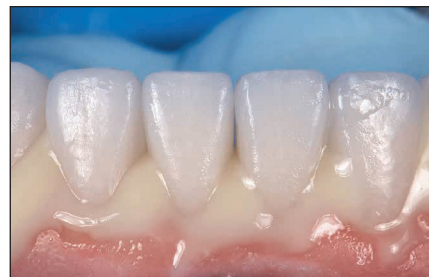

Fig 19f Resin cement (Panavia SA, Kuraray Noritake) is used for bonding.

Bonding Technique

The mandibular anterior zirconia crowns were air-abraded with 30-micron silica particles (Rocatec Soft, 3M ESPE) for 20 seconds, rinsed, dried, and silanated (Clearfil ceramic primer, Kuraray Noritake) (Figs 19a to 19c).

The prepared teeth were polished with pumice on a rubber cup and then air-particle abraded with 30-micron silica particles (Rocatec Soft) to increase micromechanical retention (Fig 19d). A self-etching adhesive (Clearfil SE Bond 2, Kuraray Noritake) was applied, as the majority of the remaining tooth structure was dentin (Fig 19e).

An adhesive resin cement (Panavia SA, Kuraray Noritake) was used to bond all the mandibular anterior restorations (Fig 19f). Periapical radiographs were taken to verify the absence of any residual excess cement.³¹

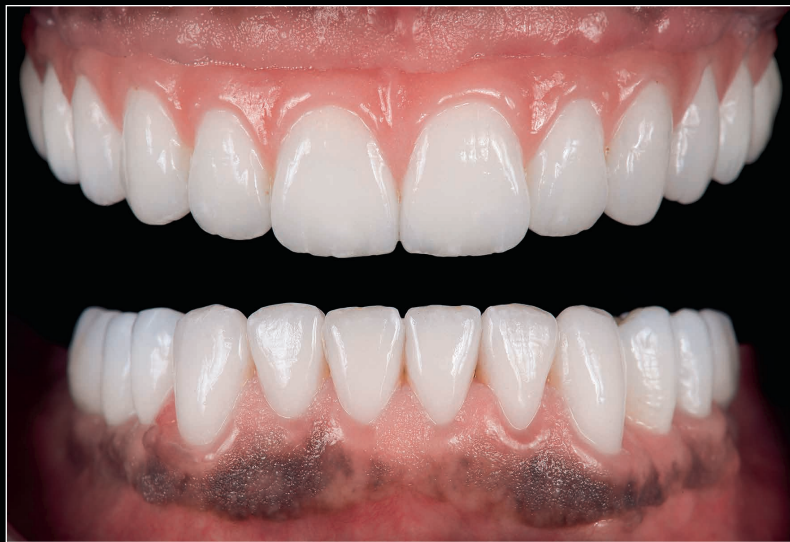The maxillary and mandibular screw-retained prostheses were seated and tightened with new screws to 15 Ncm and 35 Ncm, respectively. All screw holes were closed with polytetrafluoroethylene tape and composite resin for retrievability.³²

Definitive Restorations and Follow-up

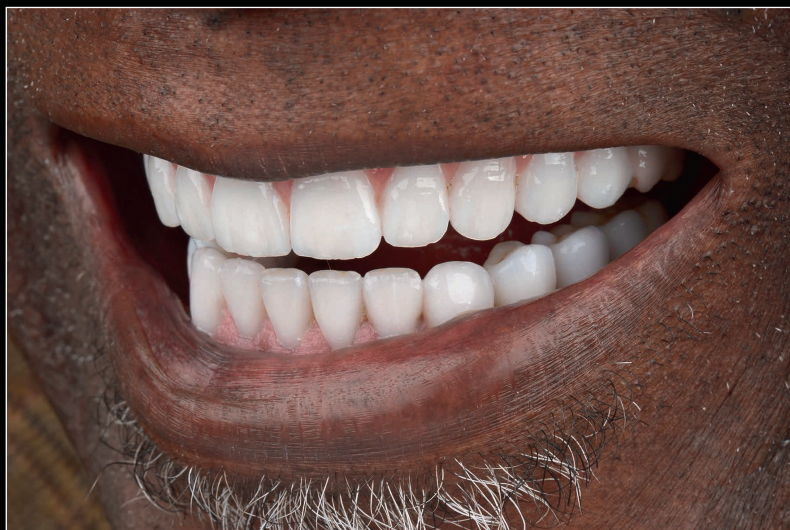The occlusion was verified and adjusted to achieve a mutually protected occlusion. Final intraoral, extraoral, and radiographic views of the restorations are shown in Fig 20. Follow-ups were performed at 1, 3, and 6 months.

CONCLUSIONS

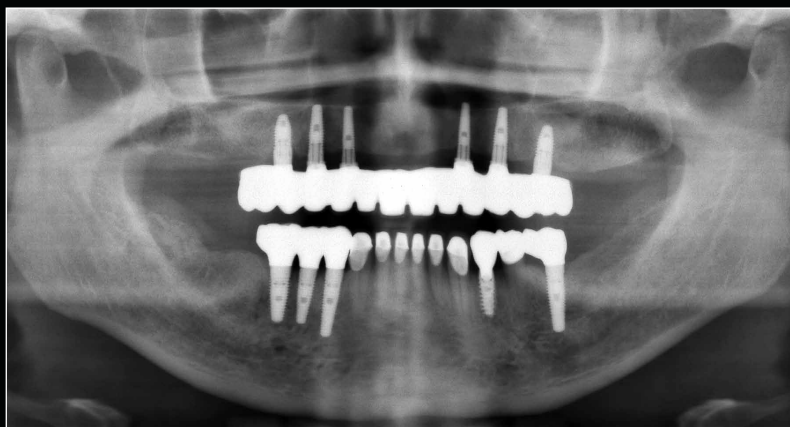
Attrition was the main cause of this patient's worn dentition. However, dental caries contributed to the biologic failure. A clear understanding of the disease etiology and proper diagnosis and material selection were essential to the execution of the treatment. Key to the success of this treatment was the meticulously designed treatment plan according to esthetic and functional parameters along with the use of artistic philosophy and CAD/CAM technology to create an excellent outcome.



20a



20b



20c

Figs 20a and 20b Intraoral and extraoral views of the completed rehabilitation.

Fig 20c Final radiograph.

ACKNOWLEDGMENTS

The authors would like to thank Dr Jimmy Londono and Dr Jae Seon Kim for their collaboration in the patient's treatment, and Dr Henry Ferguson for the surgical treatment performed in this case. This work was supported by the Nobel Biocare/Augusta University Center of Excellence, Augusta, Georgia.

REFERENCES

1. Abrahamsen TC. The worn dentition—Pathognomonic patterns of abrasion and erosion. *Int Dent J* 2005;55(4 suppl 1):268–276.
2. Verrett RG. Analyzing the etiology of an extremely worn dentition. *J Prosthodont* 2001;10:224–233.
3. Grippo JO, Simring M, Schreiner S. Attrition, abrasion, corrosion and abfraction revisited: A new perspective on tooth surface lesions. *J Am Dent Assoc* 2004;135:1109–1118.
4. Dawson P. *Functional Occlusion from TMJ to Smile Design*. St Louis: Mosby, 2007.
5. Guess PC, Schultheis S, Bonfante EA, et al. All-ceramic systems: Laboratory and clinical performance. *Dent Clin North Am* 2011;55:333–352.
6. Chiche GJ. Proportion, display, and length for successful esthetic planning. In: Cohen M (ed). *Interdisciplinary Treatment Planning: Principles, Design, Implementation*. Chicago: Quintessence, 2008: 21–29.
7. Gamborena I, Blatz M. Immediate protocol and guided surgery for esthetic success with full-mouth implant rehabilitations. *Quintessence Dent Technol* 2009;32:47–62.
8. Chiche GJ, Pinault A. *Esthetics in Fixed Prosthodontics*. Chicago: Quintessence, 1996.
9. Jivraj S, Chee W. *Treatment Planning in Implant Dentistry*. London: BDJ Books, 2007.
10. Papaspyridakos P, Benic GI, Hogsett VL, White GS, Lal K, Gallucci GO. Accuracy of implant casts generated with splinted and non-splinted impression techniques for edentulous patients: An optical scanning study. *Clin Oral Implants Res* 2012;23:676–681.
11. Papaspyridakos P, Lal K, White GS, Weber HP, Gallucci GO. Effect of splinted and nonsplinted impression techniques on the accuracy of fit of fixed implant prostheses in edentulous patients: A comparative study. *Int J Oral Maxillofac Implants* 2011;26:1267–1272.
12. Zaghloul HH, Younis JF. Marginal fit of implant-supported all-ceramic zirconia frameworks. *J Oral Implantol* 2013;39:417–424.
13. Guess PC, Att W, Strub JR. Zirconia in fixed implant prosthodontics. *Clin Implant Dent Relat Res* 2012;14:633–645.
14. Lorenzoni FC, Martins LM, Silva NR, et al. Fatigue life and failure modes of crowns systems with a modified framework design. *J Dent* 2010;38:626–634.
15. Larsson C, El Madhoun S, Wennerberg A, Vult von Steyern P. Fracture strength of yttria-stabilized tetragonal zirconia polycrystals crowns with different design: An in vitro study. *Clin Oral Implants Res* 2012; 23:820–826.
16. Sundh A, Sjogren G. A comparison of fracture strength of yttrium-oxide- partially-stabilized zirconia ceramic crowns with varying core thickness, shapes and veneer ceramics. *J Oral Rehabil* 2004;31: 682–688.
17. Rosentritt M, Steiger D, Behr M, Handel G, Kolbeck C. Influence of substructure design and spacer settings on the in vitro performance of molar zirconia crowns. *J Dent* 2009;37:978–983.
18. Larsson C. Zirconium dioxide based dental restorations. Studies on clinical performance and fracture behaviour. *Swed Dent J Suppl* 2011;(213):9–84.
19. Larsson C, Vult Von Steyern P. Implant-supported full-arch zirconia-based mandibular fixed dental prostheses. Eight-year results from a clinical pilot study. *Acta Odontol Scand* 2013;71:1118–1122.
20. Papaspyridakos P, Lal K. Computer-assisted design/computer-assisted manufacturing zirconia implant fixed complete prostheses: Clinical results and technical complications up to 4 years of function. *Clin Oral Implants Res* 2013;24:659–665.
21. Puri S, Parciak EC, Kattadiyil MD. Complete mouth reconstruction with implant-supported fixed partial dental prostheses fabricated with zirconia frameworks: A 4-year clinical follow-up. *J Prosthet Dent* 2014;112:397–401.
22. Rojas-Vizcaya F. Full zirconia fixed detachable implant-retained restorations manufactured from monolithic zirconia: Clinical report after two years in service. *J Prosthodont* 2011;20:570–576.
23. Tiozzi R, Gomes EA, Lapria Faria AC, Silveira Rodrigues RC, Ribeiro Rf. Effect of cyclic loading on the vertical microgap of long-span zirconia frameworks supported by 4 or 6 implants. *J Prosthet Dent* 2014;112:828–833.
24. Sadid-Zadeh R, Liu PR, Aponte-Wesson R, O'Neal SJ. Maxillary cement retained implant supported monolithic zirconia prosthesis in a full mouth rehabilitation: A clinical report. *J Adv Prosthodont* 2013; 5:209–217.
25. Bacchi A, Consani RL, Mesquita MF, dos Santos MB. Stress distribution in fixed-partial prosthesis and peri-implant bone tissue with different framework materials and vertical misfit levels: A three-dimensional finite element analysis. *J Oral Sci* 2013;55:239–244.
26. Cheng CW, Chien CH, Chen CJ, Papaspyridakos P. Complete-mouth implant rehabilitation with modified monolithic zirconia implant-supported fixed dental prostheses and an immediate-loading protocol: A clinical report. *J Prosthet Dent* 2013;109:347–352.
27. Garbelotto LG, Maziero Volpato CA, Rocha MD, Maranghello CA, Calasans A, Ozcan M. Laboratory and clinical considerations on prosthetic zirconia infrastructures for implants. *Implant Dent* 2013; 22:578–583.
28. Thalji GN, Cooper LF. Implant-supported fixed dental rehabilitation with monolithic zirconia: A clinical case report. *J Esthet Restor Dent* 2014;26:88–96.
29. Worni A, Kolgeci L, Rentsch-Kollar A, Katsoulis J, Mericske-Stern R. Zirconia-Based Screw-Retained Prostheses Supported by Implants: A Retrospective Study on Technical Complications and Failures. *Clin Implant Dent Relat Res* 2014 Feb 27; doi: 10.1111/cid.12214 [Epub ahead of print].
30. Mehra M, Vahidi F. Complete mouth implant rehabilitation with a zirconia ceramic system: A clinical report. *J Prosthet Dent* 2014;112: 1–4.
31. Blatz MB, Phark JH, Ozer F, et al. In vitro comparative bond strength of contemporary self-adhesive resin cements to zirconium oxide ceramic with and without air-particle abrasion. *Clin Oral Investig* 2010; 14:187–192.
32. Lee A, Okayasu K, Wang HL. Screw- versus cement-retained implant restorations: Current concepts. *Implant Dent* 2010;19:8–15.