

OF THE CALIFORNIA DENTAL ASSOCIATION

Journal

JUNE 2012

Esthetic Transformation

Ultimate Ceramic Veneer

Dental Ceramics



novel technologies in
esthetic oral rehabilitation

SILLAS DUARTE JR., DDS, MS, PHD

Vol 40 N°06

Getting all of your insurance through the most trusted source? Good call.

Protect your business:

TDIC Optimum bundle

- Professional Liability
- Building and Business Personal Property
- Workers' Compensation
- Employment Practices Liability

Protect your life:

- Life/Health/Disability
- Long-Term Care
- Business Overhead Expense
- Home and Auto

Protecting dentists.
It's all we do.®

800.733.0633 tdicsolutions.com CA Insurance Lic. #0652783

Coverages specifically written by The Dentists Insurance Company include Professional Liability, Building and Business Personal Property, Workers' Compensation and Employment Practices Liability. Life, Health, Disability, Long-Term Care, Business Overhead Expense and Home and Auto products are underwritten by other insurance carriers and offered through TDIC Insurance Solutions.



DEPARTMENTS

- 461** The Editor/ *The End of the World ... or Not*
- 463** Letter to the Editor
- 465** Impressions
- 473** CDA Presents
- 519** Continuing Education
- 529** Classifieds
- 540** Advertiser Index
- 542** Dr. Bob/*Celebreteeth for Sale*



465

FEATURES

476 THE IMPORTANCE OF THE OPTICAL PROPERTIES IN DENTAL SILICA-BASED CERAMICS

Dental ceramics are able to reproduce the optical and functional properties of the dental tissues. This paper emphasizes that a correct communication process with the laboratory is the key to success and biointegration with the ceramic indirect restoration.

Paulo Monteiro, DMD, MSc; Pedro Brito, CDT; Joana Pereira, MSc; and Ricardo Alves, DMD, MSc

483 ESTHETIC TRANSFORMATION OF A FAILED IMPLANT RECONSTRUCTION TO FIXED-SUPPORTED PROSTHESIS: A CASE REPORT

This article describes a clinical situation where an ill-fitting prosthesis supported by malpositioned dental implants was esthetically transformed to fixed definitive restorations.

Domenico Cascione, CDT, BS; Hessam Nowzari, DDS, PhD; Mamaly Reshad, DDS, MSc

489 ULTIMATE CERAMIC VENEER: A LABORATORY-GUIDED PREPARATION TECHNIQUE FOR MINIMALLY INVASIVE LAMINATE VENEERS

The purpose of this article is to present a novel technique called ultimate ceramic veneer, where the preparation was laboratory-guided and done after impression, meaning, that, if necessary, the ceramist trims the model only where there is no space for the material.

Oswaldo Scopin de Andrade, DDS, MS, PhD; Ronaldo Hirata, DDS, MS, PhD; Marcos Celestrino, CDT; Marcio Seto, DDS, MS; Sérgio Siqueira Jr., DDS, MS; and Rodrigo Nahas, DDS, MS

497 IMPLANT-SUPPORTED FULL-MOUTH RECONSTRUCTION MALO IMPLANT BRIDGE

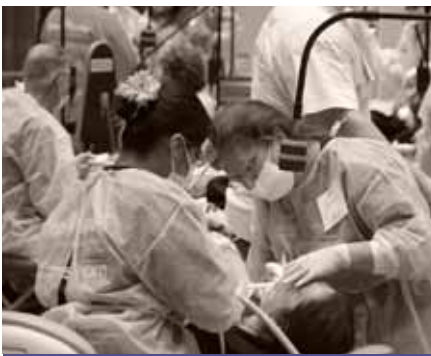This article describes the clinical techniques and laboratory procedures for fabricating a predictable Malo Implant Bridge, involving application of an occlusal screw-retained implant superstructure on the basis of the All-on-4 concept.

Taishi Kodama, RDT

509 ESTHETIC CONSIDERATIONS FOR THE TREATMENT OF THE EDENTULOUS MAXILLA BASED ON CURRENT INFORMATIC ALTERNATIVES: A CASE REPORT

Presentation of a protocol and discussion to take advantage of the computed tomography-based software programs and navigation systems, and the computer-aided design and computer-aided manufacturing innovative techniques for the treatment of the edentulous maxilla.

Mario H. Rodríguez-Tizcareño, DDS; Lizbeth Barajas, DDS; Marisol Pérez-Gásque, DDS; and Salvador Gómez



Thank you to our volunteers.

CDA Cares Modesto exemplified the best of our community in action. It was more than 1,200 volunteers, from all walks of life and professions, coming together to help those in need. And just look at what you accomplished:

- \$1.2 million in dental services
- 7,200 procedures
- 1,650 patients
- countless smiles

Thank you to all those who saw the need and stepped up to answer it.

cda cares

California Dental Association Foundation
in partnership with America's Dentists' Care Foundation

cdfoundation.org/cdacares

Journal

OF THE CALIFORNIA DENTAL ASSOCIATION

CDA Journal
Volume 40, Number 6
JUNE 2012



Journal of the California
Dental Association

published by the
California Dental
Association
1201 K St., 14th Floor
Sacramento, CA 95814
800.232.7645
cda.org

Management

Kerry K. Carney, DDS
EDITOR-IN-CHIEF
Kerry.Carney@cda.org

Ruchi K. Sahota, DDS, CDE
ASSOCIATE EDITOR

Brian K. Shue, DDS
ASSOCIATE EDITOR

Peter A. DuBois
EXECUTIVE DIRECTOR

Jennifer George
VICE PRESIDENT,
MARKETING

Cathy Mudge
VICE PRESIDENT,
COMMUNITY AFFAIRS

Alicia Malaby
COMMUNICATIONS
DIRECTOR

Jeanne Marie Tokunaga
PUBLICATIONS MANAGER

Jack F. Conley, DDS
EDITOR EMERITUS

Editorial

Robert E. Horseman, DDS
CONTRIBUTING EDITOR

Sillas Duarte Jr., DDS,
MS, PhD
GUEST EDITOR

Patty Reyes, CDE
ASSISTANT EDITOR

Courtney Grant
MARKETING SPECIALIST

Crystan Ritter
ADMINISTRATIVE
ASSISTANT

Advertising

Corey Gerhard
ADVERTISING MANAGER

Jenaé Gruchow
PROJECT/TRAFFIC
ADMINISTRATOR

Mallory Buckner
ADMINISTRATIVE
ASSISTANT

Production

Matt Mullin
COVER DESIGN

Randi Taylor
SENIOR GRAPHIC
DESIGNER

Ann Davis
GRAPHIC DESIGNER/
PRODUCTION ARTIST

California Dental Association

Daniel G. Davidson, DMD
PRESIDENT
president@cda.org

Lindsey A. Robinson, DDS
PRESIDENT-ELECT
presidentelect@cda.org

James D. Stephens, DDS
VICE PRESIDENT
vicepresident@cda.org

Walter G. Weber, DDS
SECRETARY
secretary@cda.org

Clelan G. Ehrler, DDS
TREASURER
treasurer@cda.org

Alan L. Felsenfeld, DDS
SPEAKER OF THE HOUSE
speaker@cda.org

Andrew P. Soderstrom, DDS
IMMEDIATE PAST
PRESIDENT
pastpresident@cda.org

Reader Guide:

Upcoming Topics

JULY: *Virtual Dental Home*
AUGUST: *General Topics*
SEPTEMBER: *General Topics*

Manuscript Submissions

Patty Reyes, CDE
ASSISTANT EDITOR
Patty.Reyes@cda.org
916-554-5333
Author guidelines
are available at
[cda.org/publications/
journal_of_the_california_
dental_association/
submit_a_manuscript](http://cda.org/publications/journal_of_the_california_dental_association/submit_a_manuscript)

Classified Advertising

Jenaé Gruchow
PROJECT/TRAFFIC
ADMINISTRATOR
Jenae.Gruchow@cda.org
916-554-5332

Display Advertising

Corey Gerhard
ADVERTISING MANAGER
Corey.Gerhard@cda.org
916-554-5304

Letters to the Editor

Kerry K. Carney, DDS
Kerry.Carney@cda.org

Subscriptions

The subscription rate is \$18 for all active members of the association. The subscription rate for others is as follows: *Non-CDA members and institutional*: \$40 *Non-ADA member dentists*: \$75 *Foreign*: \$80 *Single copies*: \$10 Subscriptions may commence at any time. Please contact: Crystan Ritter ADMINISTRATIVE ASSISTANT Crystan.Ritter@cda.org 916-554-5318

Permission and Reprints

Jeanne Marie Tokunaga
PUBLICATIONS MANAGER
JeanneMarie.Tokunaga@cda.org
916-554-5330

Journal of the California Dental Association (ISSN 1043-2256) is published monthly by the California Dental Association, 1201 K St., 16th Floor, Sacramento, CA 95814, 916-554-5330. Periodicals postage paid at Sacramento, Calif. Postmaster: Send address changes to *Journal of the California Dental Association*, P.O. Box 13749, Sacramento, CA 95853.

The *Journal of the California Dental Association* is published under the supervision of CDA's editorial staff. Neither the editorial staff, the editor, nor the association are responsible for any expression of opinion or statement of fact, all of which are published solely on the authority of the author whose name is indicated. The association reserves the right to illustrate, reduce, revise, or reject any manuscript submitted. Articles are considered for publication on condition that they are contributed solely to the *Journal*.

Copyright 2012 by the California Dental Association.



The End of the World ... or Not

KERRY K. CARNEY, DDS

There is something reassuring about end of the world predictions. They never go out of style. They are as regular as the coming of summer. They are liberating. Nothing matters because it is all going to end soon. Also, there is that great potential “I told you so” aspect. Of course, the only people you would really be able to say that to would not be around to recognize how right you were.

The end of the world. You can't get much more final than that. Why bother paying those bills or going to work or doing the laundry? I suppose I should wait until closer to the date of the end of the world to stop making entries in my patient records. So what is that date?

According to Hollywood and New Age hype it is Dec. 21, 2012. The Mayan calendar is the putative source of the current end of days.

The ancient Mayan study of time and celestial events was precise and accurate. There is a great story by Augusto Monterroso titled, *El Eclipse*. In the story, the priest Bartolomé Arrazola is about to be sacrificed by his Mayan captors. He tries to convince them of his power and thereby win his release. He draws on his knowledge of an imminent solar eclipse and tells them that he will blot out the sun and turn the day into night.

Unfortunately for him, the Mayan astronomers had already predicted all solar eclipses, including that one. His theatrical prediction failed to win him a reprieve. The tale ends with Arrazola's sacrifice during the twilight of the eclipse to the sound of his captors chanting the dates of future eclipses.

This most recent end-of-the-world prediction is really a misrepresentation of the meaning of the “long count” divisions of



Overall, the future of dentistry that was conjured up in 2001 looked a lot like the dentistry of that age.

the Mayan calendar. Regardless, perhaps we can use this media-created brouhaha in some positive way.

The end of the world should be a great time of reckoning, a time to take stock of previous predictions and where we are now.

How about a look at the ADA's “Future of Dentistry Executive Summary” subtitled, “Today's Vision: Tomorrow's Reality”? This was a summary of “The 2001 Future of Dentistry Report.” I ran across this publication and perused it to see how accurate yesterday's vision proved to be. More than a decade ago, where did we think we would be in 2012?

The most obvious flaw was the failure to foresee the 2008 crash of the housing market and the ensuing great depression and its effect on dentistry. For example, in the section on “Economic Trends” the report reassured us that “[t]he last genuine economic contraction occurred in 1991, and even that downturn was brief and mild. The ensuing decade has been one of uninterrupted prosperity and steady growth ... As a result an increasing number of Americans have access to needed treatment.”¹

The introduction goes on to say, “Dentistry's record of health promotion through private practice and community-based prevention programs positions it to play a leading role in future public health initiatives.”¹ That would seem to

be a description of smooth sailing with a clear horizon. There is no foreshadowing of forces outside of organized dentistry positioning themselves to play a role in public health initiatives.

The report provides seven “Broad Recommendations.” They are generic enough to still apply to the here and now.

- Establish and support partnerships and alliances among dental, other health care professionals, and public health organizations, as well as business and social service groups in order to address common goals to improve oral health;
- Aggressively address the oral health needs of the public;
- Strengthen and expand dentistry's research and education capabilities;
- Ensure the development of a responsive, competent, diverse, and “elastic” workforce;
- Develop strategies to address the fiscal needs of the practice, education, and research sectors of dentistry to ensure their viability and vitality;
- Establish a formal organization ... representing research; and
- ... [Emphasize] the development of highly targeted, collaborative marketing, and public relations initiatives.¹

The recommendations for “Clinical Dental Practice and Management” predicted that despite transforming technological advances, “... the dominant dental delivery

modes will continue to be solo practices and small group practices.”¹ That does describe the here and now but future trends bring that prediction into question. Large and very large dental group practices appear to be gaining market share and have become significant enough to have their own associations: the Dental Group Practice Association (DGPA) and the American Academy of Dental Group Practice (AADGP).

The report called for studies that would “establish whether alterations must be made to assure that the public can be adequately served.”¹ There were four recommendations that focused on efforts to lobby for increased awareness of the importance of oral health but not much on how to increase funding for the delivery of oral health care.

There was one recommendation in support of fluoridation efforts. Before CDA sponsored successful fluoridation legislation in 1995, the percentage of Californians having access to fluoridated water was only 17 percent. That percentage has increased as a result and stands at 63 percent today.

In the section titled, “Dental Laboratory Technician Training and Program Accreditation,” the discussion was around the need for dentists to be in charge of directing the fabrication of prostheses. The report postulated that “Given longer life expectancy and the *inevitable* [emphasis added] loss of teeth of the older population ...” resources must be found to provide the prostheses. I was under the impression that with proper professional and home care that the loss of dentition was not *inevitable*.

This study’s future of dentistry did not foresee the steady increase in computer-assisted design or fabrication of restorations, and little mention was made of the growing importance of implants in the armamentarium of general dentistry.

There was no forecast of the importance of the electronic record nor the impact of social media. (Facebook and Yelp both launched in 2004.)

The proposed “Recommendations for Financing of Dental Services” look like wishful thinking in large part.

The section on “Recommendations for Access to Care” starts out boldly declaring that, “we ... must summon the political will to break down financial and other barriers that diminish access to care.”¹ However the majority of this section concentrated on the need for market-level reimbursement and specialty clinics.

It did not foresee the discussions that are ongoing in the legislatures around the country today. Nor did it portend the important role groups outside dentistry would play in oral health policy and legislation. The rest of the recommendations concerned licensure, dental education, dental and craniofacial research, and global oral health.

Overall, the future of dentistry that was conjured up in 2001 looked a lot like the dentistry of that age. That future does not look much like the dentistry of today.

Predicting the future is about as reliable as predicting the end of the world.

One particularly stressful day, while I was trying to put out one administrative fire after another, I was complaining to my spouse, “You know it never ends!” His response stopped me cold in my frazzled tracks. He said, “No. One day it does.”

Life is a constant balance of future-oriented goal-setting and living every day as if it might be your last. The ancient Mayans had a point. Time is a property to be counted and measured, but every individual’s position on that slide rule makes one appreciate the experience of the present for the gift that it is. ■■■■

REFERENCES

1. American Dental Association, *Future of Dentistry — Executive Summary*. Chicago, American Dental Association, Health Policy Resources Center, 2002.

The Journal of the California Dental Association welcomes letters.

We reserve the right to edit all communications and require that all letters be signed. Letters should discuss an item published in the Journal within the past two months or matters of general interest to our readership. Letters must be no more than 500 words and cite no more than five references. No illustrations will be accepted. Letters may be submitted via email to the Journal editor-in-chief at kerry.carney@cda.org. By sending the letter to the Journal, the author certifies that neither the letter nor one with substantially similar content under the writer’s authorship has been published or is being considered for publication elsewhere, and the author acknowledges and agrees that the letter and all rights of the author with regard to the letter become the property of the California Dental Association.

Future Ramifications of Zirconia Crowns

As a general dentist who has been practicing for many years, I'm getting more and more concerned about our profession's love affair with bonded zirconia and lithium disilicate restorations.

Yes, in these days of high-priced noble metals and focus on esthetics, it's certainly a very attractive solution to many of our problems. I believe, however, we need to be aware of the long-term effect of our choices.

Over the years of practice, I have removed many failed crowns and replaced them with PFGs or porcelain. The removal has been fast, easy, and nontraumatic to the tooth (pulp) and patient.

I've not had to remove any lithium disilicate or zirconia crowns yet, but the advertising speaks about "the virtually unbreakable" zirconia. I can see the next generation of dentists struggling with the removal of bonded full-zirconia crowns on molars. What happens to the tooth? The patient?

Shouldn't we, as a profession, be conscious about the ramifications of what we do today on our patients in the future?

I'm close to retirement, so I'll be safe, but my heart goes out to the young dentist buying a practice from a not-so-conscious dentist with poor-fitting zirconia crowns. Be aware!

ANNIKA LOGART, DDS
Huntington Beach, Calif.

Ostrow School of Dentistry of USC

ASSISTANT DEAN OF CLINICAL AFFAIRS

The University of Southern California (USC), founded in 1880, is located in the heart of downtown L.A. and is the largest private employer in the City of Los Angeles. As an employee of USC, you will be a part of a world-class research university and a member of the "Trojan Family," which is comprised of the faculty, students and staff that make the university what it is.

Since 1897, the Ostrow School of Dentistry has shaped talented students into outstanding dentists and dental hygienists. Our challenging clinical education and our expert faculty members provide future oral health professionals with the skills they need in order to become the best.

The Ostrow School of Dentistry of USC seeks applicants for a full-time, non-tenure-track position at the rank of assistant, associate or full professor in the Division Restorative Sciences to serve as the Assistant Dean of Clinical Affairs. This position will report to the Associate Dean of Clinical Affairs for the School and will work closely with Division Chairs, the Associate Dean of Academic Affairs & Student Life, pre-doctoral Group Practice Directors, post-doctoral Program Directors and clinic staff to manage the day-to-day operation of the pre-doctoral clinics, facilitate pre-doctoral clinic education and ensure excellence in teaching and patient care services. The Assistant Dean of Clinical Affairs will have primary responsibility for providing academic leadership and management of the teaching and learning activities in the pre-doctoral clinics, as well as, faculty and staff development, clinic utilization management, patient relations, performance improvement and fiscal management.

Candidates must have a DDS or DMD degree and at least three to five years' experience managing clinic operations and teaching in an institution of higher education. Academic rank is commensurate with experience and qualifications. Consideration of applicants will begin immediately and will continue until the position is filled.

Interested applicants should submit a cover letter, complete curriculum vitae, and arrange to have at least three to five letters of reference sent to:

Dean Avishai Sadan
Ostrow School of Dentistry of USC
925 West 34th Street, DEN 203
Los Angeles, CA 90089-0641

For more information and/or to apply: <https://jobs.usc.edu/applicants/Central?quickFind=64055>

USC values diversity and is committed to equal opportunity in employment. Women and men, and members of all racial and ethnic groups, are encouraged to apply.

You've built a practice as exceptional as you are. Now choose the optimum insurance to protect it.

TDIC Optimum

Anything but ordinary, Optimum is a professional bundle of products that combines TDIC's singular focus in dentistry, thirty years of experience and generous multipolicy discounts. Creating the ultimate coverage to protect your practice, perfectly. And you wouldn't have it any other way.

TDIC Optimum Bundle
Professional Liability
Building and Business
Personal Property
Workers' Compensation
Employment Practices
Liability

**Protecting dentists.
It's all we do.®**

800.733.0633
tdicsolutions.com
CA Insurance Lic. #0652783

Eligible multipolicy discounts apply to Professional Liability, Building and Business Personal Property and Workers' Compensation.



tdic®



Put Down the Cake

The pandemic is growing as quickly as you can say, “Please pass the cake.”

Obesity, cardiovascular disease, high blood pressure, type 2 diabetes, and heart disease – most may blame alcohol or fast food, but the American Heart Association says it directly correlates to sugar. The AHA recommends women consume no more than about six teaspoons of added sugar daily and men about nine teaspoons.

Karen Davis, RDH, BSDH, led a lecture at *CDA Presents* in San Francisco titled “America’s Sweet Tooth Obsession and Its Impact on Oral and Systemic Health.” Attendees were told they should learn how to educate their patients on eating too much sugar.

“I suggest you teach your patients to be label detectives, especially when you are looking in the mouths of individuals who have a medical history of diabetes, cardio-

CONTINUES ON 467

Four Times the Fluoride Protection With New ‘Massage’ Method

Rubbing toothpaste onto your teeth can provide four times better fluoride protection, according to a recent study. Researchers testing a Swedish toothpaste with more than three times the fluoride content as standard toothpaste also evaluated a number of different brushing techniques.

The team of researchers, from the University of Gothenburg’s Sahlgrenska Academy, are the first to perform a scientific study of the effect of the so-called “high-fluoride toothpaste,” according to a news release from the university.

Sixteen volunteers tested various brushing techniques, brushing either two or three times a day with high-fluoride or standard toothpaste.

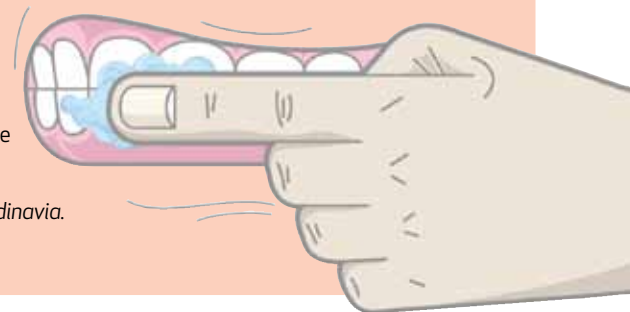
“The study revealed that those who used a high-fluoride toothpaste three times a day had four times better fluoride protection in the mouth than those who used standard toothpaste twice a day,” said researcher Anna Nordström, from the Institute of Odontology at the academy, in the release.

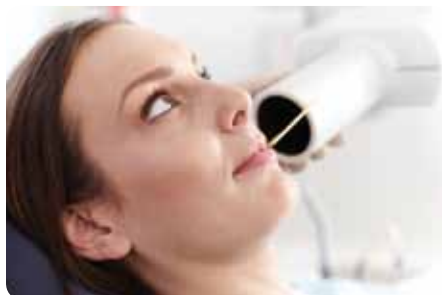The team also tested an innovative rubbing method that involves massaging toothpaste onto teeth with a finger.

Researchers found the “massage” method to be at least as effective as a third brushing in increasing the amount of fluoride in the mouth.

“But this should not replace brushing with a fluoride toothpaste morning and evening — it’s an extra,” Nordström said.

The study was published in March in *Acta Odontologica Scandinavica*.





American Dental Association: X-rays Necessary for Diagnosis and Treatment

The American Dental Association recently responded to the results of a study published in the American Cancer Society's online journal, *Cancer*, which associated yearly or more frequent dental X-rays with an increase in the risk of developing meningioma, a type of noncancerous brain tumor.

The ADA reviewed the study and responded in a news release stating that "results (of the study) rely on the individuals' memories of having dental X-rays taken years earlier." According to the organization, studies have shown that the ability to recall information is often imperfect. Therefore, the statement added, the results of studies that use this design can be unreli-

able because they are affected by what scientists call "recall bias."

Reiterating its long-standing position, the ADA says dentists should utilize dental X-rays "only when necessary for diagnosis and treatment" and referenced its recommendations, which are provided to help ensure that radiation exposure is "as low as reasonably achievable." These recommendations include using a digital X-ray or the fastest available film speed (E or F) as well as abdominal shielding and thyroid collars on all patients.

According to the ADA, its Council on Scientific Affairs will publish clinical guidance on the use of cone-beam computed tomography in an upcoming issue of *The Journal of the American Dental Association*.

To see the ADA's full statement, go to ada.org/6972.aspx.

Diabetes Drug May Fight Oral Cancer

New research suggests that metformin, the most widely used treatment for patients with type 2 diabetes, may protect against oral cancer. Results of the study, published in *Cancer Prevention Research*, a journal of the American Association for Cancer Research, are part of increasing evidence of metformin's protective effect. Researchers found metformin acted against mTOR to prevent lesion progression, the authors reported.

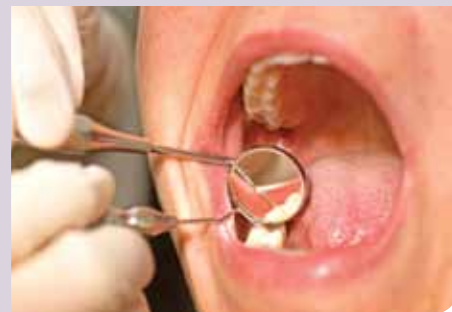J. Silvio Gutkind, PhD, chief of the Oral and Pharyngeal Cancer Branch of the National Institute of Dental and Craniofacial Research at the National Institutes of Health, and colleagues induced premalignant lesions in laboratory mice and studied the effect of metformin on progression of these lesions to oral cancers.

"We saw strong activity against mTORC1 (mammalian target of rapamycin complex 1), which we know contributes to oral cancers, so this is strong preclinical information that there is a protective effect," said Gutkind in a news release.

Gutkind and colleagues found that administration of metformin reduced the size and number of carcinogen-induced oral tumoral lesions in mice and significantly reduced the development of squamous cell carcinomas by about 70 to 90 percent, according to a news release from the American Association for Cancer Research.

Metformin inhibited mTORC1 function in the basal layer of oral premalignancies and prevented their spontaneous development into head and neck squamous cell carcinomas, the research team concluded.

Source: *Cancer Prevention Research* 5(4):562, published online first, April 3, 2012. DOI: 10.1158/1940-6207.CAPR-11-0502. Press release: <http://www.aacr.org/home/public-media/aacr-in-the-news.aspx?d=2765>.



Dentist Anesthesiologists Wanted in Pediatric Practices

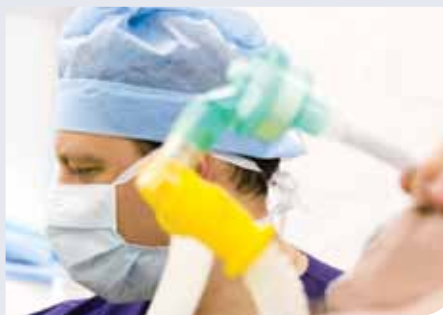The desire for dentist anesthesiologists in pediatric dental practices is reportedly on the rise, according to a survey published in an issue of *Anesthesia Progress*.

“The purpose of this study is to explore the use of office-based sedation by board-certified pediatric dentists practicing in the United States,” the authors wrote.

The research team, from Indiana University in Indianapolis, surveyed active board-certified pediatric dentists who are members of the American Academy of Pediatric Dentistry. Of the 1,917 recipients, a total of 494 practitioners completed and returned the survey, according to the report.

More than 70 percent of board-certified pediatric dentists in the United States report using some form of sedation. Less than 20 percent administer IV sedation, while 20 to 40 percent use a dentist anesthesiologist, and 60 to 70 percent say they would use a dentist anesthesiologist if one were available.

Source: *Anesthesia Progress* 59(1):12-7, Spring 2012.



CAKE, CONTINUED FROM 465

vascular diseases, high blood pressure and evidence of demineralization,” Davis said.

According to Davis, over the last 25 years, consumption of sugary drinks has risen 135 percent nationwide. Energy drinks, flavored drinks and sports drinks can be targeted as possible culprits, and portion sizes are not helping either. Typically, soft drinks in the ‘50s were 6.5 ounces. By 1960, it had increased to 12 ounces, and by 2000, it had reached 20 ounces on average.

Davis recommended advising patients to choose foods that have natural levels of antioxidants and also do not have high levels of natural sugar. According to Davis, the best fruit choices are pears, grapefruits, nectarines, raspberries, and lemon and limes – all of which are not loaded with natural sugar and have natural antioxidants.

Patients also should be advised on cooking with sugar substitutes. While there are many on the market, Davis recommended xylitol because it is one of the only natural options with the exact same sweetness as sugar.

“For your patients who have diminished salivary flow, using xylitol products can help stimulate natural salivary flow,” Davis said.

Other tips for gaining control of the sugar binge for improved health include setting discretionary limits for daily calories; reducing cravings with substitution snacks such as almonds, walnuts/cheese and fruit; and preparing foods with fresh herbs to increase satisfaction with meals. Davis also recommended dentists use an assessment on patients to prevent caries.

“The Caries Management by Risk Assessment, coined CAMBRA, is what most of us can and should be using in our dental practices today to determine the risk of a patient,” Davis said.

CAMBRA offers an innovative approach to oral care — helping dentists and hygienists assess a patient’s risk for oral disease by examining various health and lifestyle factors as part of their regular dental checkup. A CAMBRA assessment form and other related tools can be found in the October 2007 edition of the *Journal of the California Dental Association*.

Caries Risk Recommendations

Moderate Caries Risk

- Xylitol (6-8 grams daily)
- Over-the-counter fluoride toothpaste twice daily
- Over-the-counter fluoride rinse daily
- Sealants on pits/fissures
- In-office fluoride varnish application at each visit
- Re-examining the patient every four to six months
- Bitewing every 18-24 months

High Caries Risk

- Xylitol (6-8 grams daily)
- Over-the-counter fluoride rinse daily, chlorhexidine rinse daily for one week every month
- 5,000 PPM fluoride toothpaste
- Sealants on pits/fissures
- In-office fluoride varnish application at each visit
- Re-examining the patient every three to four months
- Bitewing every six to 18 months

After completing an assessment to identify if a patient has a moderate or high caries risk, dentists should use recommendations beneficial to reverse the process and promote remineralization. (See accompanying box.)

“We need to be proactive,” Davis said.

Sure, evacuating the pulp chamber is simple.



Now, let's increase your wisdom on dental benefit plan contracts.

Signing up for a plethora of dental plans may seem prudent, but choose the wrong ones and things can go south in a hurry. To help, there's Dental Contracts 101 on CDA's Compass. This quick read is packed with insight on fee schedules, plan procedures and everything you need to ensure your bottom line is smarter than ever.

cdacompass.com | where smart dentists get smarter.™





**"GINTUIT provides
an alternative treatment to
the current standard of care
for treatment of
gingival conditions."**

KAREN MIDTHUN, MD

FDA Approves First Cell-Based Product to Treat Mucogingival Conditions in Adults

The Food and Drug Administration recently approved the first cell-based product made from allogeneic human cells (from a donor unrelated to the patient) and bovine collagen, the agency stated in a news release.

The product, called GINTUIT, is indicated for topical application to a surgically created vascular wound bed in the treatment of mucogingival conditions in adults, according to the FDA, and should make dental gum surgery easier and less painful for patients. GINTUIT is used as part of a surgical procedure to treat mucogingival conditions and the treatment regimen is a single application of the product over a surgically created vascular wound bed in the mouth.

"GINTUIT provides an alternative treatment to the current standard of care for treatment of gingival conditions," Karen Midthun, MD, director of the FDA's Center for Biologics Evaluation and Research, said in a statement from the agency.

The newly approved product consists of two layers — an upper layer formed by human keratinocytes and a lower layer consisting of bovine-derived collagen, human extracellular matrix proteins, and human dermal fibroblasts (skin cells that generate connective tissue).

The FDA reported that while the exact way in which GINTUIT increases keratinized tissue has not been identified, research has shown that it secretes human growth factors and other proteins known to be involved in wound repair and regeneration.

The efficacy of the cell-based product was evaluated in two clinical studies in adults with insufficient gingival tissue. In each of the two studies, GINTUIT was associated with an increase of at least 2 millimeters of gingival tissue in at least 50 percent of study subjects, the FDA stated.

For more information:
[fda.gov/NewsEvents/Newsroom/
PressAnnouncements/ucm295429.htm](http://fda.gov/NewsEvents/Newsroom/PressAnnouncements/ucm295429.htm).

Enzyme in Saliva Can Help Regulate Blood Glucose

Scientists from the Monell Center recently reported blood glucose levels following starch ingestion are influenced by genetically determined differences in salivary amylase, an enzyme that breaks down dietary starches. Specifically, higher salivary amylase activity is related to lower blood glucose.

The findings, published in *The Journal of Nutrition*, are the first to demonstrate a significant metabolic role for salivary amylase in starch digestion, suggesting that this oral enzyme may contribute significantly to overall metabolic status.

The team of scientists, led by Abigail Mandel, PhD, a nutritional scientist at Monell, used saliva samples from 48 healthy adults to measure the amylase activity. Based on extremes of salivary amylase activity, two groups of seven were formed: high amylase (HA) and low amylase (LA), the study reported.

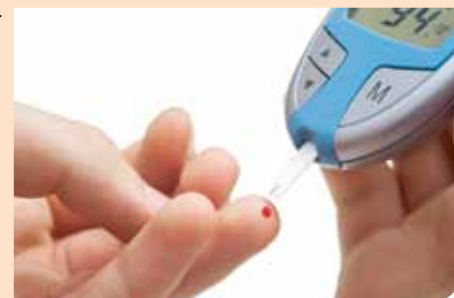Each subject drank a simplified corn starch solution and blood samples were obtained over a two-hour period afterward. Blood glucose levels and insulin concentrations were then analyzed from the samples.

"Two individuals may have very different glycemic responses to the same starchy food, depending on their amylase levels," said Mandel in a news release.

After ingesting the starch, individuals in the HA group had lower blood glucose levels relative to those in the LA group. This appears to be related to an early release of insulin by the HA individuals.

Starch from wheat, potatoes, corn, rice, and other grains is a major component of the U.S. diet, comprising up to 60 percent of our calories. Amylase enzymes secreted in saliva help break down starches into simpler sugar molecules that can be absorbed into the bloodstream. In this way, amylase activity influences blood glucose levels, which need to be maintained within an optimal range for good health.

Source: *Journal of Nutrition* volume 142, issue 4, April 1, 2012.





Jon Pascarella, DDS

Who knew braces could help you stand taller, too?

Jon Pascarella was the kid who never wanted to smile. He was insecure about his crooked teeth. What's more, in a single-parent household, money for braces wasn't easy to come by. One day, his mom suggested a payment plan to their orthodontist and thankfully he agreed. Braces didn't just straighten Jon's teeth; they transformed his being. The shy boy radiated confidence, smiled wide and knew, without a doubt, that one day he wanted to become a dentist.

Every dentist has a unique story behind why they chose this profession, but the reasons to join CDA are clear—advocacy, protection, education, support and being part of an organization dedicated to improving the oral health of all Californians.

Join. Share.
cda.org/member

cda[®]



Dentures Effectively Disinfected in Microwave

Results of a study examining different methods for disinfecting dentures was recently published in the *Journal of the American Dental Association*. Dentures are often found to be infected with super bugs like methicillin-resistant *Staphylococcus aureus* (MRSA), which “can be aspirated, thus causing infections such as aspiration pneumonia,” the study’s authors wrote.

The Centers for Disease Control and Prevention estimates that one in four people in the United States between the ages of 65 and 74 have no teeth and that an estimated 20 million people in the country wear full or partial dentures.

“MRSA strains, besides being disseminated systemically, have been isolated

from the oral cavity,” the study reported. “Some appliances within the mouth, such as removable dentures, may function as a reservoir of pathogens and render the patient more susceptible to oral colonization by MRSA.”

The team of scientists from Brazil researched the effectiveness of two disinfectant solutions and microwave irradiation in disinfecting complete dentures contaminated with MRSA. According to the study, researchers contaminated 36 simulated complete dentures with MRSA and divided them into four equal groups: a positive control group (dentures that were not disinfected); a group that soaked in 1 percent sodium hypochlorite for 10 minutes; a group that soaked in 2 percent chlorhexidine gluconate for 10 minutes; and a group that underwent microwave irradiation for three minutes.

Led by Karen Tereza Altieri, DDS, MSc, a dentist at the Araraquara Dental School at the Universidade Estadual Paulista in Sao Paulo, the team found both the soaking in chlorhexidine gluconate solution and the microwave irradiation to be effective in complete disinfection of all dentures, killing even the MRSA bugs, in the short and the long term. Either method is enough to disinfect dentures coated with the toughest MRSA biofilms for up to a week, according to the study.

Authors reported the method of soaking in a sodium hypochlorite solution was effective only as a short-term disinfectant.

“The protocols adopted in our study may be used in private dental offices and institutions or hospitals in which patients wearing dentures are treated, thus improving the longevity and quality of life of these patients and reducing the burden of disease caused by MRSA,” the authors concluded.

Source: *Journal of the American Dental Association* 143(3):270-7, March 1, 2012; jada.ada.org/content/143/3/270.full.

UPCOMING MEETINGS

2012

June 21-24	Academy of General Dentistry 2012 Annual Meeting and Exhibits, Philadelphia, agd.org/philadelphia .
June 22-24	ADA New Dentist Committee’s 26th New Dentist Conference, Washington, D.C., newdentist@ada.org or 312-440-2779.
Sept. 30-Oct. 3	National Primary Oral Health Conference, La Jolla, Calif., nnoha.org/conference/npohc.html
Oct. 18-23	ADA 153rd Annual Session, San Francisco, ada.org
Nov. 4-10	U.S. Dental Tennis Association, Tuscon, Ariz., 800-445-2524 or dentaltennis.org

2013

Feb. 7-9	20th anniversary Conference and Exhibition, Academy of Laser Dentistry, Palm Springs laserdentistry.org/ .
April 7-13	U.S. Dental Tennis Association, TOPS’L Resort, Destin, Fla., 800-445-2524 or dentaltennis.org
Nov. 3-9	U.S. Dental Tennis Association, Big Island, Hawaii, 800-445-2524 or dentaltennis.org

To have an event included on this list of nonprofit association continuing education meetings, please send the information to Upcoming Meetings, CDA Journal, 1201 K St., 16th Floor, Sacramento, CA 95814 or fax the information to 916-554-5962.

Thank you to our sponsors!

Major Sponsors:



Sponsors:



The Art
and Science
of Dentistry

Anaheim
California

Cool Products

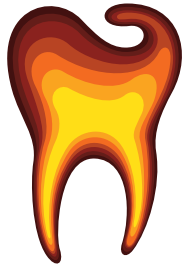CDA Presents. The home for dental innovation.

If you're looking for the latest technology, products and services in dentistry, look no further than CDA Presents. The Anaheim tradeshow featured more than 140 new products. And if you're looking for the next big idea in dentistry, it could be one of these Cool Products.

	Company	Product
	Advanced Technology & Capital	LeEject Dental Safety Syringe and Needle System Reduce needle stick injuries with a side-loading syringe and needle system that eliminates the need for recapping and unscrewing. LeEject offers the same self-aspirating feature found in premium priced syringes — at a fraction of the cost. The product will be offered to select dental programs free of charge. For more information or to inquire about distribution opportunities, please email info@leeject.com .
	Air Techniques Inc.	Mojave™ Dry Vacuum Mojave™ features an efficient single-stage regenerative pump that's driven by a variable frequency drive. Besides needing no oil or water, this pump spins fast enough to deliver the best flow rates and slows down to save energy costs. Various models are available to suit individual practice needs. <ul style="list-style-type: none"> • Lower Energy Cost: pumps only spin as fast as needed. • Consistency: highest flow rate at every operator • Efficiency: additional pumps turn on only when needed
	Carestream Dental	CS 7600 Carestream Dental's CS 7600 system generates high-quality intraoral images, quickly and easily. With exclusive Scan & Go technology, the unit is designed for multiple patients and users. And since the CS 7600's plates are as easy to use as film, the system integrates into most working environments; making it a cost-effective solution for any practice. <ul style="list-style-type: none"> • High-quality intraoral images • Exclusive Scan & Go technology • Cost-effective solution for any practice
	Carestream Dental	CS 1600 Intraoral Camera The CS 1600 intraoral camera with caries detection is a next generation, multi-use intraoral camera that combines patented caries detection technology with Carestream Dental's industry-leading image quality. The CS 1600 helps identify potential caries during screening, while delivering the highest quality images for improved communication and diagnoses. <ul style="list-style-type: none"> • Camera with caries detection • Helps identify potential caries during screening • Multi-use intraoral camera delivers the highest quality images
	Colgate	Colgate 360 Fresh 'N Protect Toothbrush Introducing Colgate 360 Fresh 'N Protect, Colgate's first Toothbrush designed for Tweens ages 8+! This product features: <ul style="list-style-type: none"> • Unique, custom colors designed to appeal to Tweens • Ultra-compact head and non-slip grips for comfortable brushing • Unique cheek and tongue cleaner that helps to remove over 96% more bacteria • Tightly packed, tapered bristles and polishing cups that help to remove more plaque and stains than an ordinary Toothbrush.
	HealthFirst	Tru-Align X-Ray Positioning System Reduce Radiation Exposure in your Dental Practice with the Tru-Align X-Ray Positioning System. Laser alignment enables rectangular collimation with precise targeting. This reduces scatter radiation 60 to 70 percent, improves images and eliminates most retakes. Show your commitment to the ALARA Principle.

	Company	Product
	Heraeus	<p>Venus® Pearl Venus® Pearl is a universal nano-hybrid composite based on the innovative urethane monomer chemistry of Venus Diamond. Venus® Pearl offers the same unprecedented combination of low shrinkage stress and high durability—in a creamy consistency. Formulated for easy handling, Venus® Pearl delivers high esthetic results through excellent color adaptation, sculptability and polishability.</p>
	Infostar	<p>SideKick MP New SideKick MP multi-platform patient education program (PC/Mac, servers, cloud, tablets and smartphones). A site license. No on-going fees. The SideKick MP has more useful features than all of its competitors combined.</p> <ul style="list-style-type: none"> • Add your own procedures and text • Translate text into 50 languages • Email anything
	MIS Implants Technologies Inc.	<p>PerioPatch PerioPatch® is a unique patch that absorbs wound exudates and promotes natural healing by forming a protective seal over inflamed gingiva and oral mucosa. Applied directly over the affected area, PerioPatch® adheres on contact and provides pain relief and natural healing with sustained protection from further irritation.</p>
	Mutual Patient	<p>Dental CE Pro Store, track and share your continuing education credit, all from your mobile device. Log all course related expenses, create a budget for every renewal period, link hotel related accommodations, categorize & rate course info, and forward your favorite courses to a friend. Created by a CDA member dentist.</p> <ul style="list-style-type: none"> • Available to Dentists, Hygienists, Assistants, Office Admin, Students • Downloadable May 1, 2012 for iPhone/iPad/Droid • Course Instructors – course marketing and utilize immediate attendee feedback Download your app today!
	ProSites	<p>Mobile Websites New patients are searching for you on their smartphones! ProSites mobile websites help you reach prospects and patients while “on-the-go.” Designed with advanced features like click-to-call phone numbers and click-to-map directions, your mobile site makes it easy for patients to find and contact your practice instantly.</p>
	Ultradent Products Inc.	<p>Edelweiss Composite Veneers Edelweiss composite veneers unlock opportunities for patients and dentists alike. Each veneer in the Edelweiss system is laser sintered for superior scratch and wear resistance. And at a fraction of the cost of lab-based systems, Edelweiss is especially attractive to people who have previously opted not to have esthetic restorations done.</p>
	VELscope LED Dental Inc.	<p>VELscope LED Dental Inc. The VELscope is the first adjunctive device cleared by the FDA and Health Canada to help clinicians detect mucosal abnormalities, including cancer, that might not be apparent to the naked eye. Visit velscope.com and the Velscope booth to see how easy it is to add Velscope to your practice. Like Velscope on Facebook at facebook.com/velscope to follow the latest information and testimonials. Join Velscope today and make early detection your priority.</p>





The Importance of the Optical Properties in Dental Silica-Based Ceramics

PAULO MONTEIRO, DMD, MSC; PEDRO BRITO, CDT; JOANA PEREIRA, MSC;
AND RICARDO ALVES, DMD, MSC

ABSTRACT To make esthetic rehabilitation similar to the natural teeth, all-ceramic restorations must have equal optical properties to the natural teeth in terms of color, translucency, fluorescence, and opalescence. Furthermore, a correct communication process with the laboratory is the key to success and biointegration with the ceramic indirect restoration and the teeth.

AUTHORS

Paulo Monteiro, DMD, MSC, is with CiiEM (Centro de Investigação Interdisciplinar Egas Moniz), Instituto Superior de Ciências da Saúde Egas Moniz, Caparica, Portugal.
Conflict of Interest
Disclosure: None reported.

Pedro Brito, CDT, is a ceramist in Lisboa, Portugal.
Conflict of Interest
Disclosure: None reported.

Joana Pereira, MSC, is with CiiEM (Centro de Investigação Interdisciplinar Egas Moniz), Instituto Superior de Ciências da Saúde Egas Moniz, Caparica, Portugal.
Conflict of Interest
Disclosure: None reported.

Ricardo Alves, DMD, MSC, is with CiiEM (Centro de Investigação Interdisciplinar Egas Moniz), Instituto Superior de Ciências da Saúde Egas Moniz, Caparica, Portugal.
Conflict of Interest
Disclosure: None reported.

Today, dental ceramics are known for their natural appearance and durability of the optical and chemical properties, presenting an important role in the oral rehabilitation.^{1,2}

The desire to find a strong and esthetic dental restorative material has been the reason of research for many years. Back in the 18th century, Alexis Duchateau used, for the first time, ceramic in teeth for a total prosthesis.^{2,3}

The appearance of crowns made totally of ceramic in 1980, resulted in best esthetic results, with innovative processing methods.¹ By the end of 20th century, many ceramic systems were introduced in the market in order to produce ceramic restorations free of metal, providing an adequate esthetic outcome with adequate color stability and the ability to mimic the dental structure.⁴

With various physical qualities, dental ceramics are characterized as glass, having as main components feldspar, quartz, alumina, and kaolin. Dental ceramics are composed by two phases: a crystal phase surrounded

by a vitreous phase.⁵ The two phases of the ceramic present light reflection that is very similar to that of the dental structure, resulting in acceptable esthetic appearance.^{3,6}

Various factors influence the ceramic resistance, of which, the ceramic material mixture used, adhesive resistance, crown thickness and restoration design, as well as adhesive technics and characteristics of the support material.⁷

According to the processing method, ceramics can be divided in two groups: porcelain fused to metal and all-ceramic.⁸

Despite the resistance capacity and reasonable esthetic appearance of the metal-ceramic restorations, patient demand for better esthetic restorations boosted the development of all-ceramic systems to be used for inlays, onlays, crowns, veneers, and implant-supported restorations. Oral rehabilitations using all-ceramic systems are becoming more and more popular.

As the most recent ceramic system, IPS system e.max Press (Ivoclar Vivadent) was introduced in 2005, being presented as an improved pressed ceramic material, in



FIGURE 1. Dental ceramic veneers (IPS e.max).

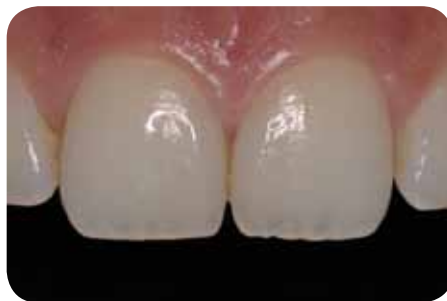

FIGURE 2. Translucent tooth incisal area.

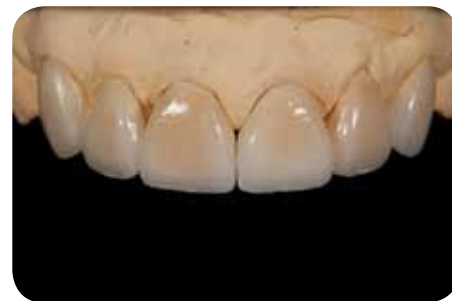

FIGURE 3. Translucency of dental ceramic (IPS e.max).

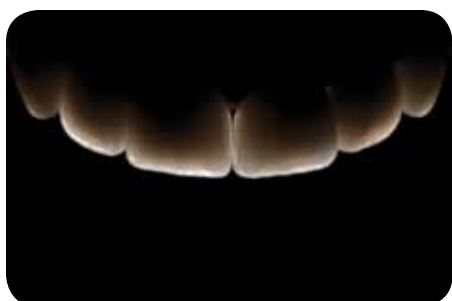

FIGURE 4. Dental ceramic opalescence (IPS e.max).

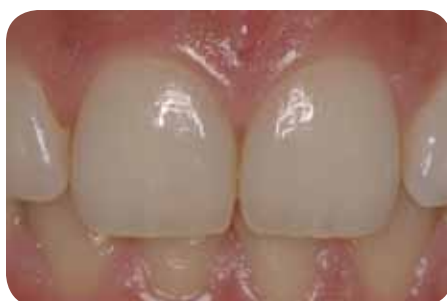

FIGURE 5. Natural enamel opalescence, reflected light.

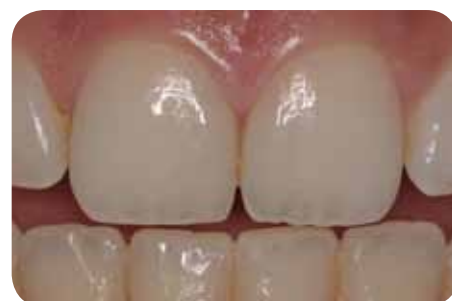

FIGURE 6. Natural enamel opalescence, transmitted light.

comparison to its predecessor. IPS e.max (Ivoclar Vivadent) consists in a reinforced vitreous ceramic with lithium disilicate, but its physical and translucency properties are improved through a different burning process. Lithium-disilicate-based ceramics, as well as the feldspar ceramics, result in superior esthetic outcomes. On the other hand, the aforementioned system has less strength when compared with alumina- and/or zirconia-based ceramics.

With ceramic restorations it can be highlighted the adequate adaptation to the remaining dental structure and surrounding gum tissues and an esthetic integration with the side teeth, resulting in a seamless and biomimetic piece of ceramic.

Optical Properties

The perfect reproduction of the color of a tooth is one of the major challenges in esthetic dentistry (FIGURE 1).⁹ Tooth color is determined by the combination of intrinsic and extrinsic coloring features. Intrinsic coloring is related to light dispersion and with light absorption properties of the enamel and dentin. The extrinsic

coloring or pigmentation is related with the enamel surface absorption characteristics, i.e., tea, red wine, coffee, chlorhexidine, and many others.¹⁰ Moreover, the color of a tooth is determined by the combination of its optical properties. These optical properties result from a light dispersion, meaning the light first focuses on the tooth before reaching the focus surface to be observed. In 1995, a group of investigators measured the light expansion in the enamel and dentine and discovered that in the enamel, the hydroxyapatite crystals contributed significantly to the light dispersion and in the dentin the dental tubules are the ones causing this phenomenon.¹¹ The dentin constitutes the first source of color and the internal light reflected will be transmitted through the enamel and modified by its thickness.¹²

The color phenomenon corresponds to a psychophysical answer, to the interaction of the light energy with the object and to the subjective experience of a person. Three main factors can influence the color perception: the light source, the observed object, and the observer.¹⁰ The source of light

affects the perception of color, once the individual sources contain variable quantities of each visible light wavelength.¹⁰

Color can be defined according with the color spectrum of Munsell, in terms of value, hue, and chroma.¹⁰ The hue corresponds to the constituting pigment color, being a physiological and psychological interpretation of the wavelengths summary. In dental medicine, the hue is represented by the letters A, B, C, and D in the VITA scale (Classical VITA Zahnfabrik, Sackingen, Germany).¹³ Value or brightness corresponds to the quantity of light reflected by an object. Munsell described the color brightness as scale of white grays to black. Bright objects have less amount of gray while objects with reduced brightness present larger amounts of gray and appear to be darker. The brightness of a crown can be increased in two ways: decreasing the color concentration or increasing the reflection of the object surface. Decreasing the value means a decrease of light that returns the lighted object; more light will be absorbed, dispersed or transmitted through the object.¹³

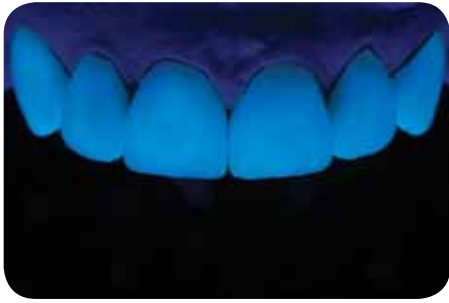


FIGURE 7. Dental ceramic fluorescence (IPS e.max).

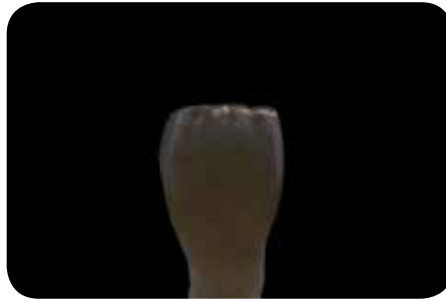

FIGURE 8. Try-in ceramic tab. Opalescence effect.

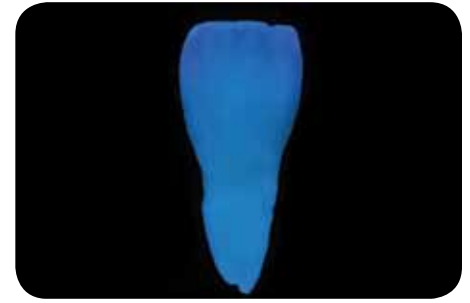


FIGURE 9. Try-in ceramic tab. Fluorescence effect.

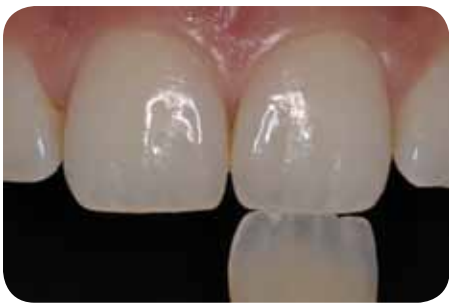

FIGURE 10. Try-in ceramic tab. Opalescence effect compared with the natural tooth, transmitted light.

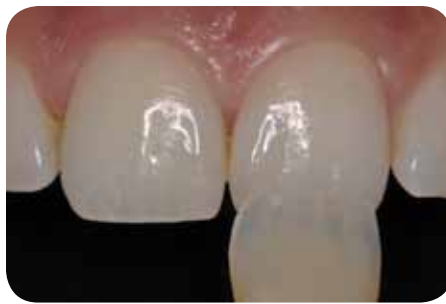

FIGURE 11. Try-in ceramic tab. Opalescence effect compared with the natural tooth, reflected light.

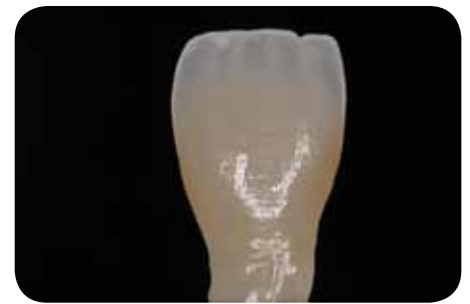

FIGURE 12. Try-in ceramic tab.

Chroma corresponds to the color saturation level and describes force, intensity, and vivacity of the color.¹⁰ For example, if a red coloring is mixed in a glass of water, each time more coloring is added, its intensity increases, but the color is always the same. In other words, the matrix is the same. The larger intensity turns into a darker color, meaning, when chroma increases the value (or brightness) decreases. Chroma and the value are characteristics inversely related.

Besides the value, hue, and chroma, there are other secondary optical properties that affect the general appearance of the ceramic restoration: translucency, opalescence, and fluorescence.¹⁰ These three optical properties must be addressed in order to obtain success in ceramic restorations.^{14,15} An incorrect reproduction of some of these characteristics affects the final esthetic result and conducts to an artificial appearance, resulting in an unsuccessful restoration.¹⁴

Translucency

Translucency can be defined as a relative quantity of light that goes through a certain thickness of material.¹⁶

This property indicates the quantity and quality of the light reflection.¹⁰

The translucency of the enamel varies according with the focus angle, surface brightness, light wavelength, and dehydration level. As for dentin, even though it is more opaque than the enamel, it is also translucent and its translucency increases with age.¹⁶ The incisal third is the most translucent region of the tooth as the thickness of the dentin is thinner than that of the gingival third (FIGURE 2).¹⁶

The percentage of the light transmission in the enamel is 70.1 percent and in dentine is 52.6 percent.¹⁶ Thus, less translucent ceramic powders are used to reproduce the dentin in a ceramic restoration and the more translucent increments are used to reproduce the enamel. This technique allows a progressive decrease of chroma from gingival third to the incisal third, as well as from the internal part to the external part of the restoration.¹⁶ Glass ceramic restorations allow the light to pass through the crown, creating a better esthetic appearance when compared with that of metal ceramic crowns.

Metal ceramic crowns reflect most part of the light and do not allow the light to go through the metal. However, the translucency in the all-ceramic restorations allow the color of the prepared tooth to influence the final color of the restoration.¹⁷

The thickness of any type of material affects its resistance and optical properties.¹⁸ In order to assure a better resistance, the manufacturers recommend a minimum of 1.5 mm of thickness for all-ceramic restorations. The thickness of ceramic affects translucency, as the thicker materials present a higher opacity.¹⁸

The coefficient of translucency used in the dough for the confection of ceramic restorations (enamel and dentine) is very important, as the reproduction of the correct incisal third details depends on it (translucency, mamelons, incisive halo) (FIGURE 3).

Opalescence

Opalescence is an optical property that consists in a dispersion of the shortest visible light wavelength, giving the object a bluish/grayish color in the reflected light and the dispersion of light

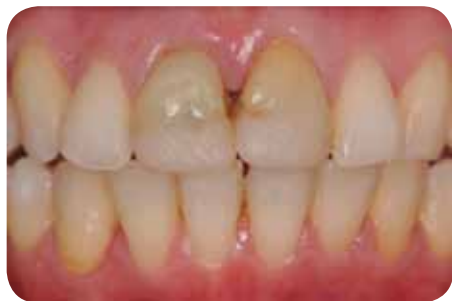

FIGURE 13. Clinical case — incisal situation.

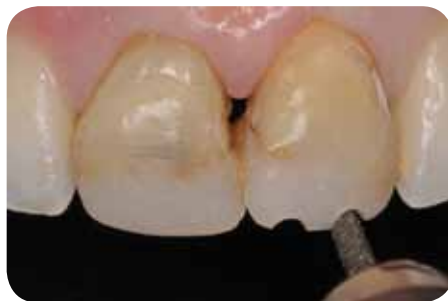

FIGURE 14. Clinical case — tooth preparation.

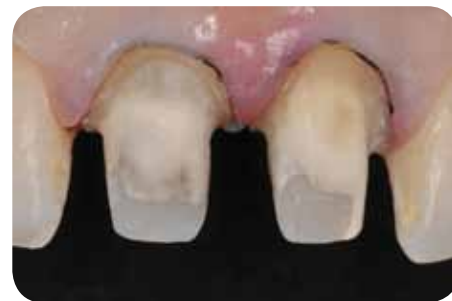

FIGURE 15. Clinical case — tooth preparation.

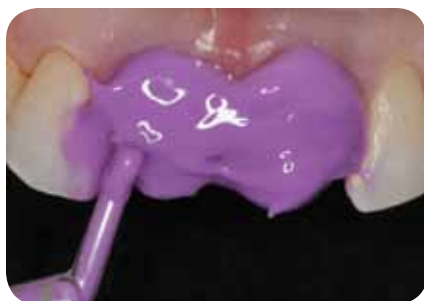

FIGURE 16. Clinical case — tooth impression with Express light body (3M ESPE).

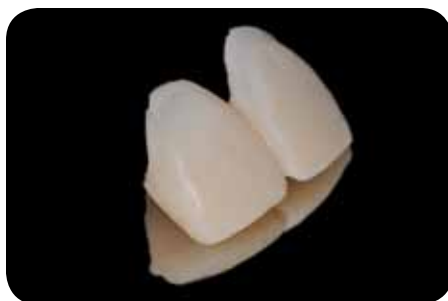

FIGURE 17. Clinical case — provisional restorations with Protemp 4 (3M ESPE).

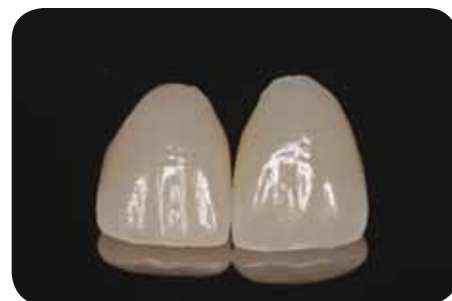

FIGURE 18. Clinical case — dental ceramic crowns (IPS e.max).

of higher wavelengths (orange, yellow, red) under transmitted light. When the reflection index existent between two substances is exceeded, the object can emit bright colors of opalescence.^{16,19}

The translucent characteristics of the enamel highlight the shorter wavelength of the visible spectrum that focus on it. It reflects a blue-grayish light that turns clearly visible between the incisive halo, and the mamelons of the dentine, varying according with the age, form of the mamelons, and distribution.^{16,20}

In dental ceramics, opalescence appears as disperse light effect obtained with the addition of small concentrations of oxides of high refraction index close to that of the visible light wavelengths (FIGURE 4). The natural teeth present some opalescence and the incorporation of this effect in the ceramic restorations can offer vitality, in conjunction with the natural translucency, matrix, chroma, and surface texture.¹

In a natural tooth, and when the patient opens their mouth, the translucent area existent between the incisive halo and the superficial dentin, turns more

noticeable turning into a bluish/grayish appearance. In young patients, this behavior is more evident. If, on the other side, the patient closes their mouth, the same translucent area will now have a chromatic orange behavior (FIGURES 5 AND 6). This phenomenon is called counteropalescence and it is important to reproduce this property in the ceramic restorations.

The reinforcement of the fluorescence and opalescence properties of dental ceramics, combined with translucency, result in restorations reactive to light that seem natural and esthetic in any type of light, and that react to the light in the same way as the natural tooth.^{19,20}

Fluorescence

In 1911, Studel demonstrated that natural teeth issue a strong blue fluorescence under the effect of ultraviolet light. This property makes the teeth whiter and lighter when exposed to daylight, or under artificial lights, such as, fluorescent lights, flashes, or dark light.^{21,22} This optical property of dental structure is determined mainly by dentin because it has more

collagen (organic material) that has amino acids that issue fluorescence, such as tripofano, resulting in a fluorescence three times larger than the enamel.^{23,24} Yet, the enamel fluorescence is attributed to its organic components that contribute in less than 2 percent of its total composition.²³

In order to make the esthetic rehabilitation similar to the natural teeth, the ceramic restorations must have an equal fluorescence to the natural teeth in terms of color and intensity, not only under the natural light but also under different light sources (FIGURE 7).²⁵ Fluorescent compounds are added to the ceramics in order to increase the quantity of light that returns to the observer, in order to block discolorations and decrease the chroma.³³ Oxides, such as europium, terbium, cerium, and ytterbium are currently used as luminophores, however, none of these components alone can give color or fluorescence similar to that of the natural teeth.²¹ Thus, luminophores must be mixed to provide acceptable fluorescence.²⁶

Fluorescence can be used to camouflage darkened teeth without negatively affecting the translucency and can in-

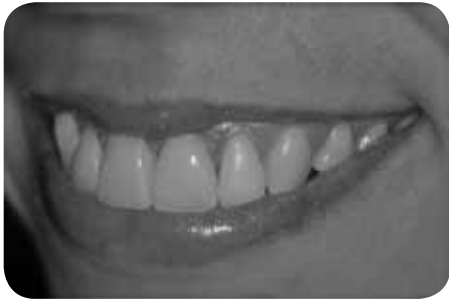

FIGURE 19. Clinical case — Cemented crowns with RelyX Ultimate (3M ESPE).

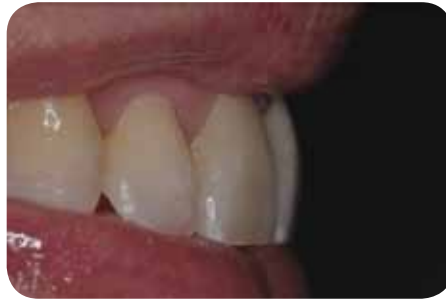

FIGURE 20. Clinical case — dental ceramic clinical behavior.

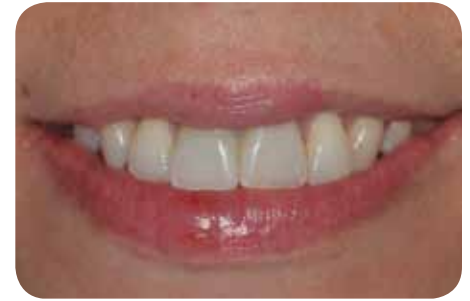

FIGURE 21. Clinical case.

crease the vitality of a restoration, minimizing the metamerism effect between the restoration and the teeth.²⁷ Even though fluorescence has a small impact under the natural light conditions, under dark light conditions can be a critical aspect when the teeth and the restorations show different fluorescences.²⁵

Fluorescence can be relevant in some social and professional environments, where teeth are under dark light (discotheques, bars, etc). If a ceramic without fluorescence is used to rehabilitate a tooth, under UV light, the appearance will be a black space, compatible with a dental absence.

Using an adequate and efficient protocol can improve the communication with the laboratory, and, as a consequence, improve the final results in terms of color, optical properties, form, macro, and microtexture. From the study models and intraoral photographs, the lab technician is able to optimize the optical properties of the natural teeth (translucency, opalescence, fluorescence) (FIGURES 8 AND 9), as well as all texture and surface details. All internal details of the incisal third of the teeth were adequately replicated (dentin shade, mamelons, translucency, opaque halo, characterization of white stains) (FIGURES 10 AND 11). From the information the dentist sends to the laboratory (study models, impressions, wax diagnosis, intraoral photographs), the lab technician can create a ceramic try-in guide with the replication of the properties needed (FIGURE 12). In the following clinical case, we can see the importance of an adequate communication with the protease laboratory,

in the re-establishment of the function and esthetic of the upper incisors teeth (FIGURES 13-18). It can be observed that the ceramic crowns replicate the optical properties of the adjacent teeth, creating an esthetic and harmonized rehabilitation (FIGURES 19-21).

Clinical Relevance

Dental ceramics are able to reproduce the optical and functional properties of the dental tissues. A correct communication process with the laboratory is the key to success and biointegration with the ceramic indirect restoration. ■■■■

REFERENCES

1. Kelly JR, Nishimura I, et al, Ceramics in dentistry historical roots and current perspectives. *J Prosthet Dent* 75(1):18-32, 1996.
2. Leinfelder KF, Porcelain esthetics for the 21st century. *J Am Dent Assoc* 131(4):47-51, 2000.
3. Kina S, Cerâmicas dentárias. *Revista Dental Press de Estética* 2(2):112-28, 2005.
4. Pinto MM, Propriedades ópticas e microestrutura de materiais cerâmicos de restauração dentária. Dissertação de Doutorado em Medicina Dentária, Universidade de São Paulo, Brasil, 2009.
5. Gomes EA, Assunção WG, et al, Cerâmicas odontológicas: o estado atual. *Cerâmica* 54:319-25, 2008.
6. Bottino MA, Quintas AF, et al, Estética em reabilitação oral metal free. Editora Artes Médicas, São Paulo, Brasil, pages 213-64, 2001.
7. Conrad HJ, Seong WJ, et al, Current ceramic materials and systems with clinical recommendations: A systematic review. *J Prosthet Dent* 98(5):389-404, 2007.
8. Denry I, Holloway JA, Ceramics for dental applications: a review. *Mater* 3(1):351-68, 2010.
9. Yoshida A, Miller L, et al, Spectrophotometric analysis of tooth color reproduction on anterior all-ceramic crowns: part 2: color reproduction and its transfer from in vitro to in vivo. *J Esthet Dent* 22(1):53-63, 2010.
10. Joiner A, Tooth colour: a review of the literature. *J Dent* 32(1):3-12, 2004.
11. Vaarkamp J, Ten Bosch JJ, et al, Propagation of light through human dental enamel and dentine. *Caries Res* 29(1):8-13, 1995.
12. Raptis NV, Michalakakis KX, et al, Optical behavior of current ceramic systems. *Int J Periodontics Restorative Dent* 26(1):31-41, 2006.

13. Fondriest J, Shade matching in restorative dentistry: the science and strategies. *Int J Periodontics Restorative Dent* 23(5):3-15, 2003.

14. Barão VAR, Gennari-Filho H, et al, Factors to achieve aesthetics in all-ceramic restorations. *J Craniofac Surg* 21(6):2007-12, 2010.
15. Uludag B, Usumez A, et al, The effect of ceramic thickness and number of firings on the color of ceramic systems: an in vitro study. *J Prosthet Dent* 97(1):25-31, 2007.
16. Duarte S, Perdigão J, et al, Composite resin restorations — natural esthetics and dynamics of light. *Pract Periodontics Aesthet Dent* 15(9):A-H, 2003.
17. Ishikawa-Nagai S, Yoshida A, et al, Spectrophotometric analysis of tooth color reproduction on anterior all-ceramic crowns: part I: analysis and interpretation of tooth color. *J Esthet Dent* 22(1):42-52, 2010.
18. Heffernan MJ, Aquilino SA, et al, Relative translucency of six all-ceramic systems. Part I: core materials. *J Prosthet Dent* 88(1):4-9, 2002.
19. Cho M-S, Yu B, et al, Opalescence of all-ceramic core and veneer materials. *Dent Mater* 25(6):695-702, 2009.
20. Lee YK, Yu B, Measurement of opalescence of tooth enamel. *J Dent* 35(8):690-4, 2007.
21. Monsénigo G, Burdairon G, et al, Fluorescence of dental porcelain. *J Prosthet Dent* 69(1):106-13, 1993.
22. Reis R, Casemiro LA, et al, Evaluation of fluorescence of dental composites using contrast ratios to adjacent tooth structure: a pilot study. *J Esthet Dent* 19(4):199-207, 2007.
23. Takahashi MK, Vieira S, et al, Fluorescence intensity of resin composites and dental tissues before and after accelerated aging: a comparative study. *Oper Dent* 33(2):189-95, 2008.
24. Busato ALS, Reichert LA, et al, Comparação de fluorescência entre resinas compostas restauradoras e a estrutura dental hídica — in vivo. *Revista Odontológica de Araçatuba* 27(2):142-7, 2006.
25. Lu H, Lee YK, et al, Influence of the amount of UV component in daylight simulator on the color of dental composite resins. *J Prosthet Dent* 96(5):322-7, 2006.
26. Baran GR, O'Brien WJ, et al, Colored emission of rare earth ions in a potassium feldspar glass. *J Dent Res* 11(56):1323-9, 1977.
27. Park MY, Lee YK, et al, Influence of fluorescent whitening agent on the fluorescent emission of resin composites. *Dent Mater* 23(6):731-5, 2007.

TO REQUEST A PRINTED COPY OF THIS ARTICLE, PLEASE CONTACT Paulo Monteiro, DMD, MSc, email paulojorgemonteiro@yahoo.ca.



Can You Afford to Enter the World of Implant Dentistry?

Actually, You Can't Afford Not To.

As a dental practitioner, you have the opportunity to improve your patients' health and your bottom line by offering the services of implant dentistry.

15-Day Surgical Program

*Newport Beach, California
starting August 2012*

Soft Tissue Solutions

*Dublin, California
November 16-18, 2012*

4-Day Fixed & Removeable Implant Prosthetics

*Scottsdale, Arizona
October 25-28, 2012*

Dr. Carl E. Misch has trained thousands of dentists in predictable implant dentistry at the Misch International Implant Institute. Founded 25 years ago, the Misch International Implant Institute is recognized as the standard of advanced dental implant education. Here, you can learn the skills and implant techniques required to bridge the gap between dental school and the critical knowledge you need to develop a new level of patient care and practice success.

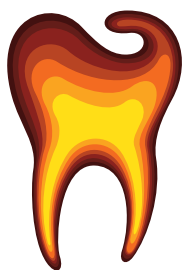

Misch International
Implant Institute
888-Misch99 or
248-642-3199
info@misch.com
www.misch.com

www.misch.com

16231 W. Fourteen Mile Rd. Suite 100, Beverly Hills, Michigan, 48025 USA





Esthetic Transformation of a Failed Implant Reconstruction to Fixed-Supported Prosthesis: A Case Report

DOMENICO CASCIONE, CDT, BS; HESSAM NOWZARI, DDS, PHD; MAMALY RESHAD, DDS, MSC

ABSTRACT This article describes a clinical situation where an ill-fitting prosthesis supported by malpositioned dental implants was esthetically transformed to fixed definitive restorations. Provisional restorations were used as a blueprint for fabrication of definitive restorations.

AUTHORS

Domenico Cascione, CDT, BS, is a clinical assistant professor, Division of Restorative Sciences, Herman Ostrow School of Dentistry, University of Southern California, Los Angeles.
Conflict of Interest
Disclosure: None reported.

Hessam Nowzari, DDS, PHD, is a professor, clinical dentistry, and director, Advanced Periodontics, Herman Ostrow School of Dentistry, University of Southern California, Los Angeles.
Conflict of Interest
Disclosure: None reported.

Mamaly Reshad, DDS, MSC, is an honorary clinical teacher, Eastman Dental Institute, University College London, and in private practice in London, England.
Conflict of Interest
Disclosure: None reported.

Tooth replacement with dental implants is a discipline that requires meticulous attention to detail. A thorough diagnosis and treatment plan, as well as a proper understanding of the properties of the materials selected with their application, is necessary.¹

Provisional restorations are the blueprint for success and an essential tool for communication.^{2,3} They allow an objective method for evaluation of all parameters prior to the fabrication of a definitive restoration. Variations in design will require diverse dimensional tolerance.^{4,5} The limiting factor in edentulous patients is the available interarch space.^{4,5} Provisional restorations are arguably the most objective method for clinicians to evaluate restorative space for the definitive prosthesis. The use of computer-assisted design/computer-aided manufacturing-designed definitive implant-supported prosthesis has gained significant popularity over the past few years. But, it is imperative not to ignore proper protocol

and treatment sequencing only because new technology is available. With proper planning, these contemporary definitive restorations may be mechanically sound as well as being esthetic and hygienic.

The situation presented in this article demonstrates how a patient was transitioned from an ill-fitting prosthesis supported by poorly positioned dental implants. Carefully fabricated provisional restorations were used to help create definitive restorations. A combination of contemporary and conventional technology was used to fabricate definitive restorations.

Case Report

A 62-year-old man was referred to the University of Southern California Faculty Practice (Oral Health Center) for the replacement of existing maxillary and mandibular implant-supported restorations (**FIGURES 1-4**). The patient's chief complaint was the high level of discomfort caused by his existing prosthesis. The maxillary prosthesis was loose and he was experiencing pain with

the mandibular. He had experienced severe weight loss, which his physician attributed to the existing restorations. The patient had also been using gauze in the buccal vestibular areas in order to avoid a sunken facial profile and cheek biting (FIGURES 1-4).⁶

Following a thorough evaluation, it was decided to re-restore the patient's dentition with implant-supported prosthesis. The existing malpositioned dental implants (FIGURES 3 AND 4) were used as interim support for the provisional restorations. These implants were later removed as they were in unrestorable positions. This strategy allowed the patient to be maintained in fixed provisional restorations throughout the treatment.⁷

Following a thorough interview to reveal the patient's esthetic desires and jaw registration, a diagnostic arrangement with denture teeth was made. Classical complete denture prosthodontics is invaluable as a diagnostic and communication tool. The use of mounted diagnostic casts, diagnostic tooth arrangements, and provisional restorations is well-documented and ensures a predictable outcome.

The diagnostic tooth arrangement in wax was duplicated in acrylic resin (FIGURES 5 AND 6) (Ena Temp; Micerium, Avegno, Italy). FIGURES 7-9 show internal character-

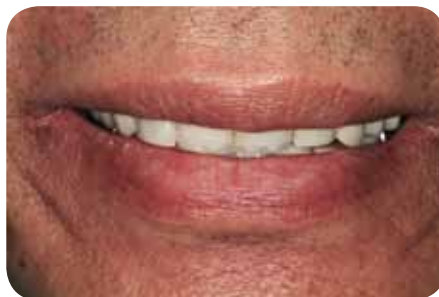

FIGURE 1. Preoperative extraoral view. Patient with a low smile line.

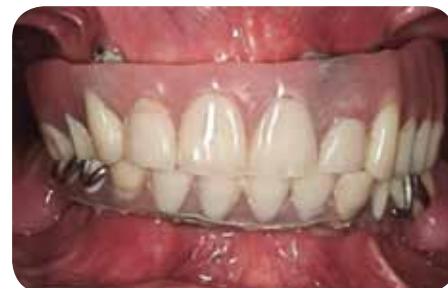

FIGURE 2. Anterior intraoral view of preoperative situation.

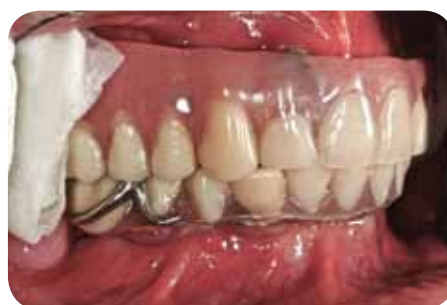

FIGURE 3. Patient is using gauze bilaterally to compensate for a deficient arch width. Mandibular removable partial denture is used over fixed mandibular implant-supported prosthesis.

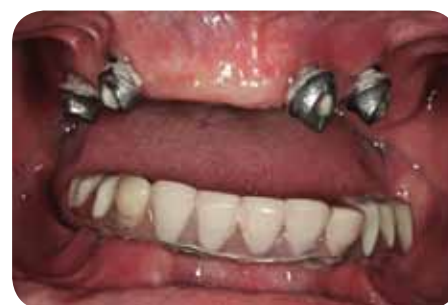

FIGURE 4. Poorly positioned dental implants with rough abutments.

ization created with the cutback technique. Appropriate treatment planning allowed adequate contours to facilitate oral hygiene procedures. A pink composite resin material (Ena Tender, HFO, Micerium) along with staining was used to mimic the simulated gingival areas (FIGURES 10-12).⁶

A certain time period is required for the evaluation of function, form, and

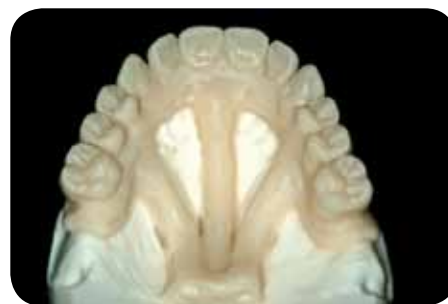

FIGURE 5. Fabrication of the provisional restoration. Dentin only.

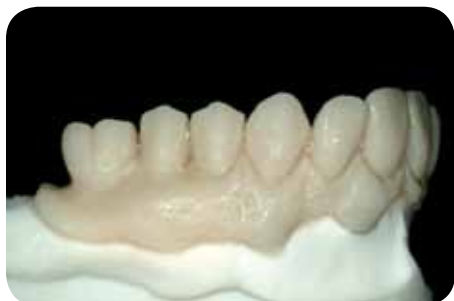

FIGURE 6A.

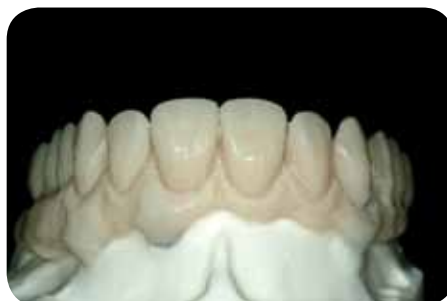

FIGURE 6B.

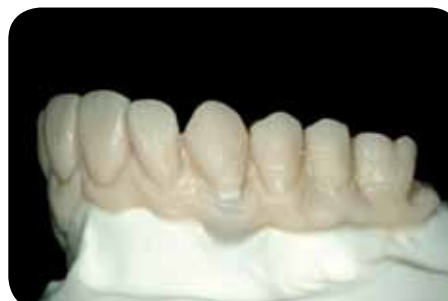

FIGURE 6C.

FIGURES 6A-C. Lateral and anterior views. Dentin only.

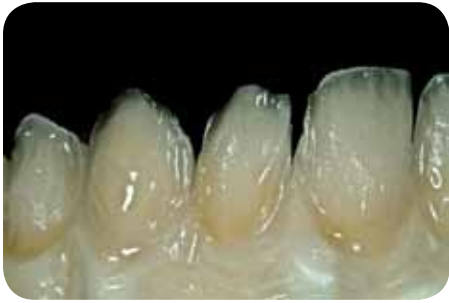

FIGURE 7A.

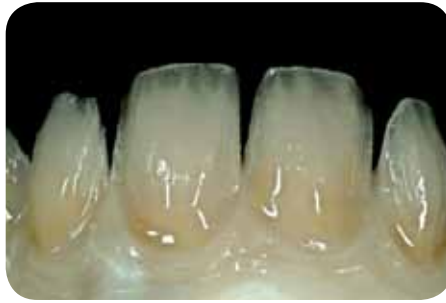

FIGURE 7B.

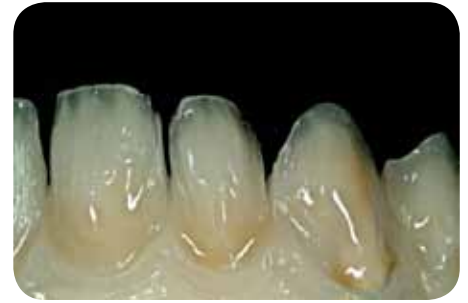

FIGURE 7C.

FIGURE 7A-C. Acrylic resin cut-back of dentin. Only minimum amount of stain applied to cervical areas. Incisal translucency achieved only through controlled cut-back of acrylic resin.

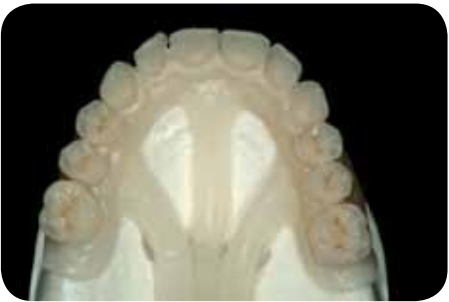

FIGURE 8. Occlusal view of provisional restorations. Enamel and dentin.

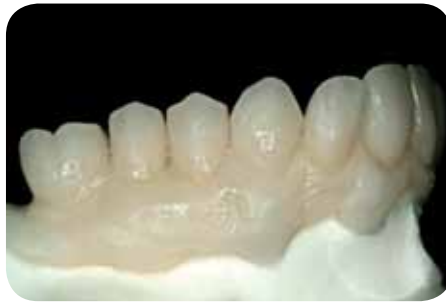

FIGURE 9A.

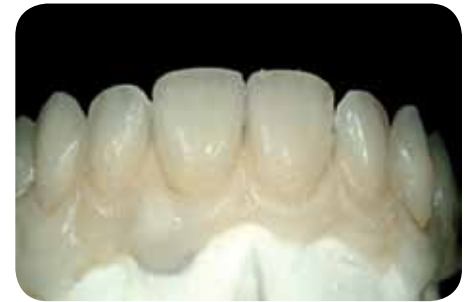

FIGURE 9B.

FIGURES 9A-C. Lateral and anterior views. Enamel and dentin. Not polished.

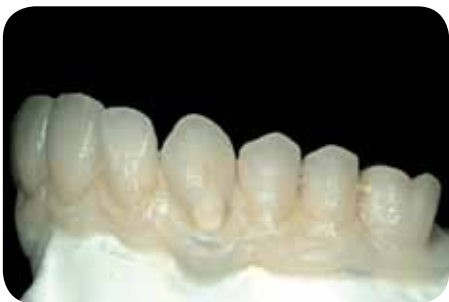

FIGURE 9C.

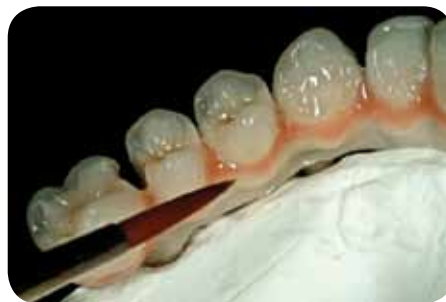

FIGURE 10. Application of soft-tissue simulated composite resin.

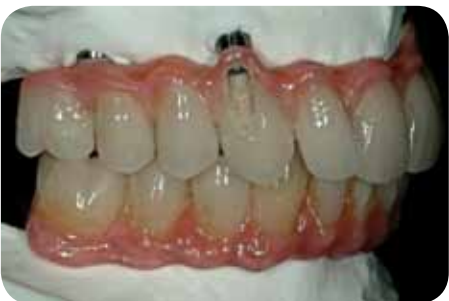

FIGURE 11A.

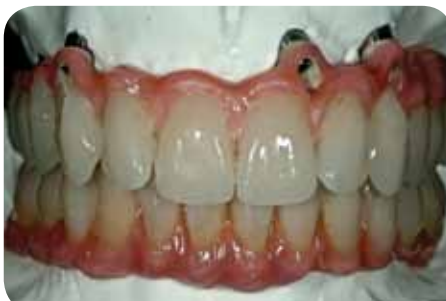

FIGURE 11B.

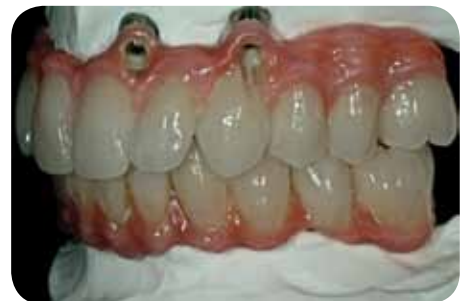

FIGURE 11C.

FIGURES 11A-C. Provisional restorations (lateral and frontal views).

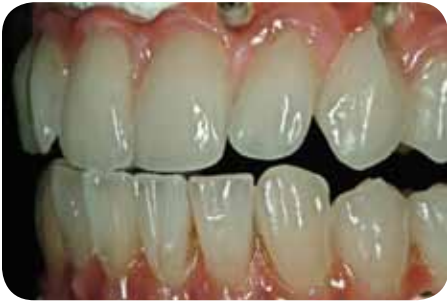

FIGURE 12A.

FIGURES 12A-B. Detailed views of the final provisionals showing the internal characterization and translucency.

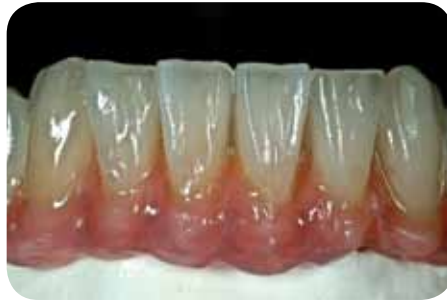

FIGURE 12B.

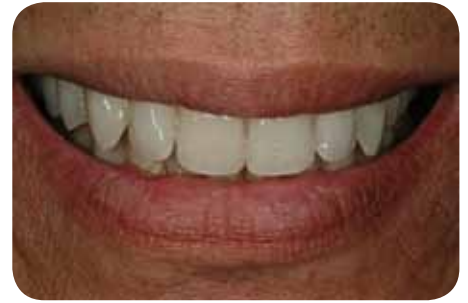

FIGURE 12C. Extraoral frontal view of the final provisional upon delivery.

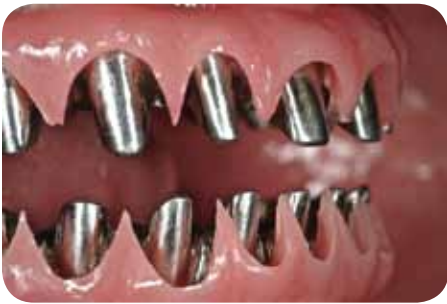

FIGURE 13. Delivery of the definitive restorations, prior to cementation of the individual copings.

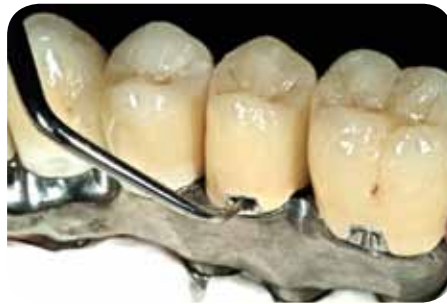

FIGURE 14. Retrieval restorations.

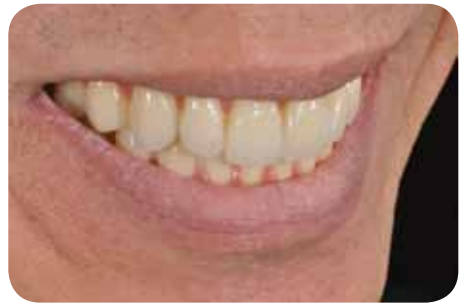

FIGURE 15A.

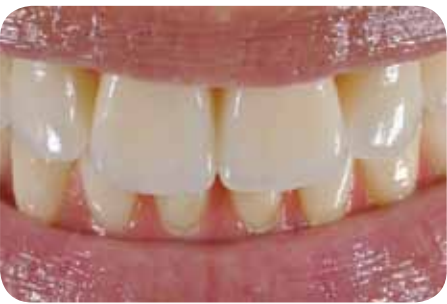

FIGURE 15B.

FIGURES 15A-D. Anterior and lateral extraoral views with the definitive restorations.

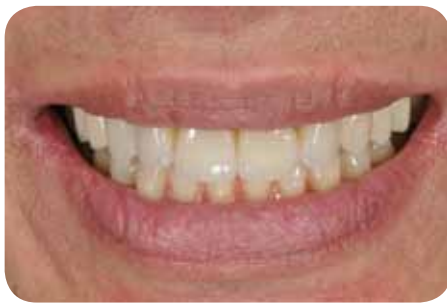

FIGURE 15C.

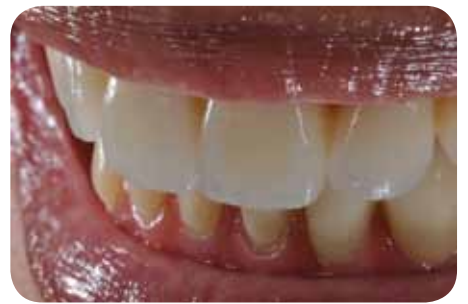

FIGURE 15D.

phonetics, in addition to esthetics. Provisional restorations serve as an excellent tool in evaluating the patient's esthetic needs (FIGURE 12C). Some patients demand a high level of restorative dentistry to achieve esthetics and function. Elective prosthetic dentistry should not be performed without a clear vision of the patient's expectations and the limitations of therapy. The final result should be visualized and realized before an irreversible procedure is performed.

Once the clinician is satisfied with all parameters, the provisional restora-

tions may be duplicated to fabricate the radiographic and surgical guides. Implant dentistry is a prosthetically driven discipline. The sequence of treatment described ensures a favorable outcome, without any complications related to poor planning.

Identical tooth arrangements may be repeatedly duplicated to fabricate additional provisional restorations and the definitive restorations.

In this situation, the frameworks for the definitive restorations were fabricated with milled titanium bars (FIGURES 13 AND 14). These were retaining individual all-ceramic zirco-

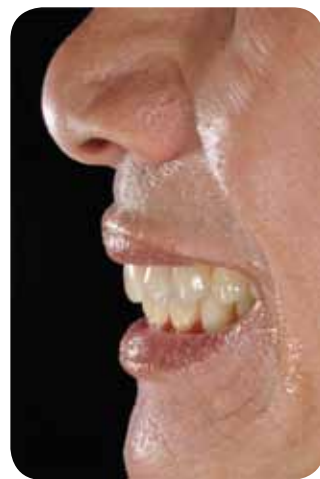

FIGURE 15E. The profile view of the definitive restoration confirming favorable esthetics and lip support.

niium oxide crowns on anterior and premolar teeth and conventional porcelain fused to metal restorations for the posterior (FIGURES 14-16).⁸ Composite resin was used to replicate gingival tissues. Detailed description for the fabrication of the definitive prosthesis has been published previously.⁹ The definitive cemented restorations were fabricated from a combination of systems currently available to satisfy functional demands while achieving suitable esthetics (FIGURE 14B).

Conclusion

When attempting to reconstruct dentitions with failed restorations it is imperative to demonstrate controlled progression through treatment. A successful outcome is more likely to follow if meticulous attention is paid to the provisional phase.¹⁰ ■■■■

REFERENCES

1. Reshad M, Jivraj S, The influence of posterior occlusion when restoring anterior teeth. *J Calif Dent Assoc* 36:567-74, 2008.
2. Reshad M, Cascione D, Magne P, Diagnostic mock-ups as an objective tool for predictable outcomes with porcelain laminate veneers in esthetically demanding patients: a clinical report. *J Prosthet Dent* 99:333-9, 2008.
3. Donovan TE, Cho GC, Diagnostic provisional restorations in restorative dentistry: the blueprint for success. *J Can Dent Assoc* 65:272-5, 1999.
4. Wicks RA, A systematic approach to definitive planning for osseointegrated implant prostheses. *J Prosthodont* 3:237-42, 1994.
5. Jivraj S, Chee W, Corrado P, Treatment planning of the edentulous maxilla. *Br Dent J* 9:201:261-79, 2006.
6. Calvani L, Michalakakis K, Hirayama H, The influence of full-arch implant-retained fixed dental prostheses on upper lip support and lower facial esthetics: preliminary clinical observations. *Eur J Esthet Dent* 2:420-8, 2007.
7. Jivraj S, Reshad M, Chee WW, Transitioning patients from teeth to implants utilizing fixed restorations. *J Calif Dent Assoc* 36:599-606, 2008.
8. Rekow D, Zhang Y, Thompson V, Can material properties predict survival of all-ceramic posterior crowns? *Compend Contin Educ Dent* 28:362-8, 2007.
9. Reshad M, Cascione D, Aalam AA, Fabrication of the mandibular implant-supported fixed restoration using CAD/CAM technology: a clinical report. *J Prosthet Dent* 102:271-8, 2009.
10. Reshad M, Cascione D, Kim T, Anterior provisional restorations used to determine form, function, and esthetics for complex restorative situations, using all-ceramic restorative systems. *J Esthet Restor Dent* 22:7-16, 2010.

TO REQUEST A PRINTED COPY OF THIS ARTICLE, PLEASE CONTACT Domenico Cascione, CDT, BS, 1332 Berkeley St., No. #3, Santa Monica, Calif, 90404.

WESTERN PRACTICE SALES | JMCA



Tim Giroux, DDS



Jon Noble, MBA



Mona Chang, DDS



John Cahill, MBA



Ed Cahill, JD

What separates us from other brokerage firms?

As dentists and business professionals, we understand the unique aspects of dental practice sales and offer more practical knowledge than any other brokerage firm. We bring a critical inside perspective to the table when dealing with buyers and sellers by understanding the different complexities, personalities, strengths and weaknesses of one practice over another.

**We offer unsurpassed exposure -
Marketing your practice in all of the major journals,
including Dental Economics.**

**Let us provide a FREE
"Opinion of Market Value"
on your Practice***

*To be used for your internal purposes only. Not to be confused with a formal business appraisal.

Testimonials

"The fact that you are a dentist adds a whole new dimension to your abilities as a broker, one which most other brokers cannot come close to"

"Your personal dedication to making everything happen was a unique touch"

"You gave me guidance that only a dentist would think of"

"Your experience & knowledge coupled with your kind personal touch I believe makes you the best in the industry!"

800.641.4179

wps@succeed.net

adstransitions.com

westernpracticesales.com

It works, because it's different.



Is it time to try something new?

CAMBRA Packages Starting at \$595.

Call **866.928.4445**
or visit **learn.carifree.com**

CariFree® 



Ultimate Ceramic Veneer: A Laboratory-Guided Preparation Technique for Minimally Invasive Laminate Veneers

OSWALDO SCOPIN DE ANDRADE, DDS, MS, PHD; RONALDO HIRATA, DDS, MS, PHD; MARCOS CELESTRINO, CDT; MARCIO SETO, DDS, MS; SÉRGIO SIQUEIRA JR., DDS, MS; AND RODRIGO NAHAS, DDS, MS

ABSTRACT Clinical success of ceramic laminate veneers depends on material selection, bonding procedures, controlled laboratory steps, and enamel preservation. Enamel preservation is the most critical because excessive tooth preparation can expose dentin reducing bond strength, which is a factor that can cause a decrease in long-term clinical success. The proposed technique based on carefully treatment planning developed between clinician and dental technician helps to maximize enamel preservation, which is an important element for clinical success.

AUTHORS

Oswaldo Scopin de Andrade, DDS, MS, PHD, is director of the Advanced Program in Implant and Esthetic Dentistry, Senac University, Sao Paulo, Brazil.
Conflict of Interest
Disclosure: None reported.

Ronaldo Hirata, DDS, MS, PHD, is director of the Advanced Program in Restorative Dentistry, ILAPEO Institute, Curitiba, Brazil.
Conflict of Interest
Disclosure: None reported.

Marcio Seto, DDS, MS, is an assistant professor of the Advanced Program in Implant and Esthetic Dentistry, Senac University, Sao Paulo, Brazil.
Conflict of Interest
Disclosure: None reported.

Sérgio Siqueira Jr., DDS, MS, is assistant professor of the Advanced Program in Implant and Esthetic Dentistry, Senac University, Sao Paulo, Brazil.
Conflict of Interest
Disclosure: None reported.

Marcos Celestrino, CDT, is a dental technician and ceramist, Aliança Dental Laboratory, Sao Paulo, Brazil.
Conflict of Interest
Disclosure: None reported.

Rodrigo Nahas, DDS, MS, is a part-time resident of the Advanced Program in Esthetic Dentistry, Senac University, Sao Paulo, Brazil.
Conflict of Interest
Disclosure: None reported.

All-ceramic restorations are indicated for a wide range of restorative procedures. Among those indications, one of the most attractive options is the utilization of this material for laminate veneers. The utilization of laminate veneers is extensively documented and has proved to be effective and predictable treatments for smile changing.^{1,2} One of the most common techniques utilized to build laminate veneers is the layering technique, which provides amazing esthetic and life-like restorations.^{3,4} Besides the esthetic outcome obtained, the utilization of this technique allows the ceramist to obtain very thin restorations, making this approach a very conserva-

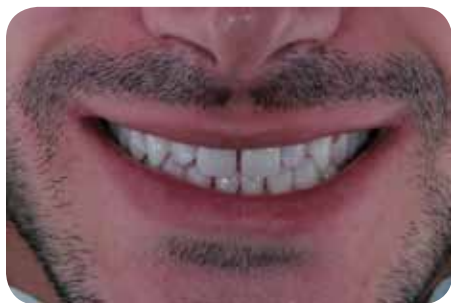

FIGURE 1A.

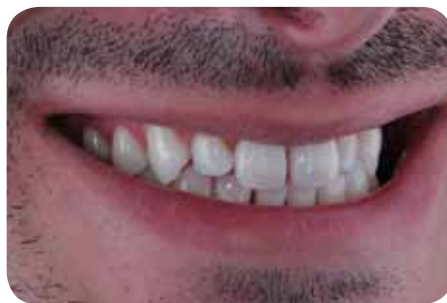

FIGURE 1B.

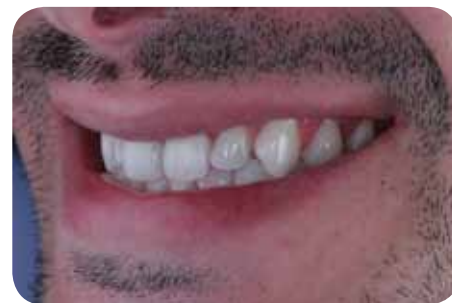

FIGURE 1C.

FIGURES 1A-C. Initial pictures show the patient smile. In the frontal view, the presence of diastema. In the lateral view (right and left), lack of proportion between both sides.

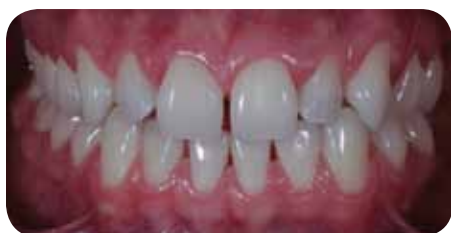

FIGURE 2A.

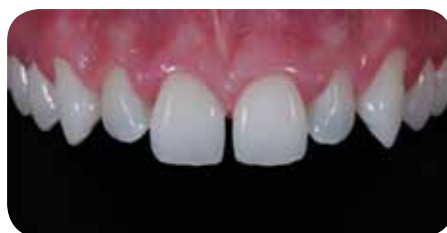

FIGURE 2B.

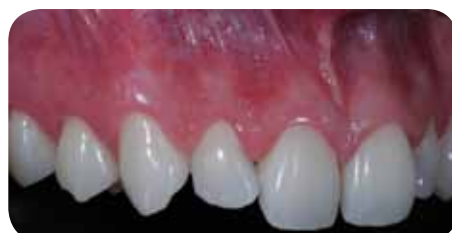

FIGURE 2C.

FIGURES 2A-D. Pictures with the lip retractor in a close up-view.

tive restorative modality.⁵ As currently emphasized by scientific literature, laminate veneers are a predictable treatment for minimally invasive restorations.^{6,7}

The predictability of this procedure is due to the physical properties of the ceramic that remains stable in terms of color and shape when careful treatment planning is carried out. Furthermore, ceramic has been proved to be a material that has low plaque adherence permitting soft-tissue stability.⁸ This perfect balance between soft tissue, esthetics, and function that lead to clinical success is dependent of the bonding ability of the material. Altering the intaglio surface of the ceramic utilizing hydrofluoric acid associated with a silane-coupling agent makes the ceramic suitable to be bonded to dental structures.⁹

Among the ceramic materials available in the market for laminate veneers, glass ceramic made on the refractory dye-technique is one of the most documented.^{10,11} In the dental literature, it is possible to find long-term clinical studies proving the effectiveness of this technique, making it a predictable

and safe procedure to be used for esthetic restorations. Even being a safe and documented restorative modality, there are some concerns regarding technical limitations.¹² From a laboratory point of view, the thickness of the veneer in thin preparations is critical because the ceramist has to control all phases of the build-up procedure to avoid air-bubble incorporation that may influence the final mechanical properties of the material, increasing time and cost to produce the restoration. A glass ceramic made on refractory dye-technique has low-fracture resistance prior to bonding to tooth structure. In this manner, from a clinician's standpoint, handling is difficult from checking the final result with the try-in paste to bonding procedures.

For those reasons, many clinicians prefer to prepare a more sound structure to get thicker restorations, having less chance of fracture and difficulties in handling. However, with the current concepts of ultraconservative procedures, ceramists and dentists are looking for new techniques that permit

minimal tooth removal with esthetic and function using the same material.¹³

The purpose of this article is to present a novel technique called ultimate ceramic veneer (UCV) where the preparation was laboratory-guided and done after impression, meaning that, if necessary, the ceramist trims the model only where there is no space for the material.¹⁴ With laboratory-made guides, the clinician may perform the preparation in a more conservative manner, saving a great deal of tooth structure, keeping the preparation in the enamel, which is essential for long-term clinical results.

Case Report

The case described in this article shows an esthetic smile changing in a young man. The main complaint of the patient was the presence of a diastema, short clinical crowns, and the overall appearance of his smile. After all the options had been explained and discussed, the patient and the clinician decided on an esthetic rehabilitation of the six maxillary teeth: four incisors and two canines.

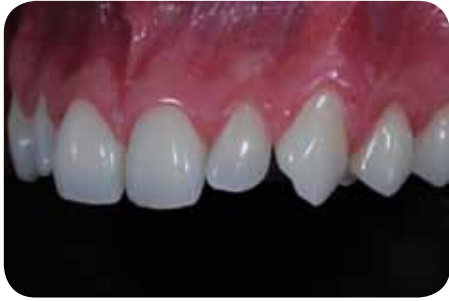

FIGURE 2D.

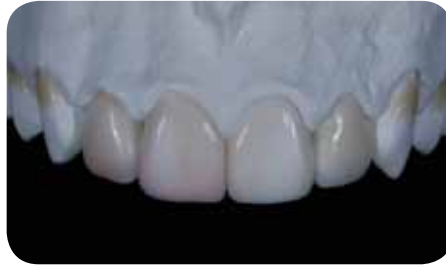

FIGURE 3. Initial additive wax-up done based on the treatment planning.

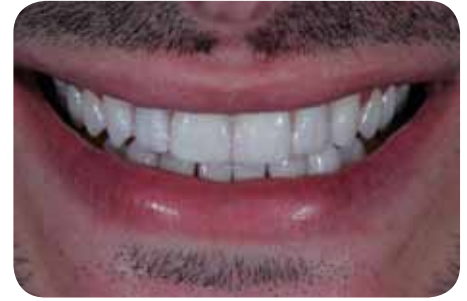

FIGURE 4. Mock-up procedure done with the wax-up for patient approval.

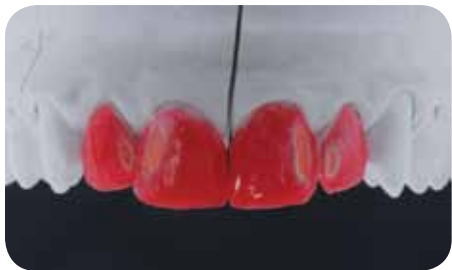

FIGURE 5A.

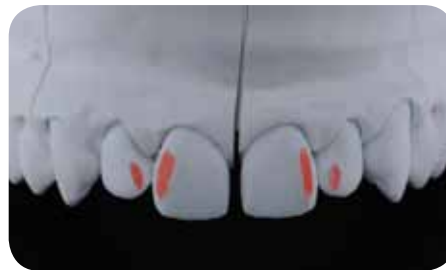

FIGURE 5B.

FIGURES 5A-B. Preparation guide (UCV guide) positioned on the master cast. The preparations were done through the acrylic, and marked with a red pencil. In Figure B, the cast without the guides.

Diagnostic Approach and Treatment Planning

The initial clinical procedure included careful analysis of the occlusion, periodontal examination, and face and intra-oral photography (FIGURES 1A-2D). A special consideration was addressed to the canine guidance. The canines are important not only as an esthetic parameter but also to maintain adequate functional height and quality of disclusion. Face photography and a face bowl helped the ceramist decide the correct midfacial line and detect any inclination of the smile line.

Addictive Preliminary Wax-Up

For precise dental treatment planning, a wax-up is indispensable. For cases where a minimal preparation is planned, the procedure must be conducted with a carefully additive technique without trimming the stone cast.¹⁵ The wax addition for planning must take in consideration the first analysis of the case, which brings together the teeth characteristics, smile design, age of the patient, occlusion pattern, gingival biotype, and perception of the patient's personality.

For this technique, the technician responsible for the case adds wax onto the preliminary cast based on anatomical parameters of natural teeth, respecting function and occlusion (FIGURE 3). The impression material for this cast must be an accurate material that can be poured more than once with the same precision.

Another important issue to be emphasized is in cases where minimal or no preparation is planned and that no temporaries are necessary. The patient must approve the esthetic design in the mock-up session, and the smile desired should be as close as possible of the final result.^{3,6}

The case planned and waxed in the preliminary model was transferred to the mouth for clinical evaluation. A bis-acrylic resin (Protemp 4, 3M ESPE) was loaded into a silicon guide made from the initial wax-up and placed in the patient's mouth¹³ (FIGURE 4). Any modification desired by the patient or detected by the clinician must be analyzed and adjusted. After patient approval, all information was collected by the mock-up using digital photog-

raphy and an alginate impression. The mock-up was removed from the mouth and teeth were pumiced for impression.

Impression Procedure

A polyether-based material (Impregum F, 3M Espe) one-step, double-mix impression technique was used, producing an appropriate reproduction of the teeth, as well as the surrounding tissue. A thin retraction cord (Ultrapack #00) was placed in the sulcus for better visualization of the cervical region. This procedure helped the ceramist to control the limit of the restoration.

Laboratory Procedures

With all the information obtained by the mock-up, the molds were poured and remounted on the articulator. Based on the wax-up the ceramist checks the space available for the veneers. A silicon index was produced on the waxed-up model, to facilitate the evaluation of the space available for the veneers. The silicon index was designed with a middle-third facial cut. The silicon index is extremely important to check the clearance available for the laminate veneers and plan how much stone, which represents the tooth structure, should be removed. After the clearance was checked, the path of insertion of the future restoration was determined.⁵

The path of insertion means the direction the laminate veneer would be positioned on a specific tooth without any interference. In order to develop a path of insertion of the restoration, some retentive areas of the tooth needed to be altered on the cast before ceramic build-up.



FIGURE 6A. Laminate veneers restorations were built in the modified master cast, with a fluorapatite glass ceramic.

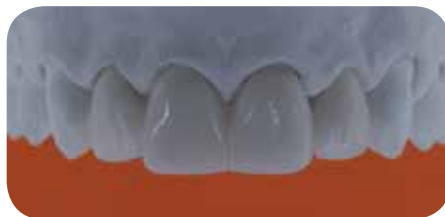

FIGURE 6B. Final restorations after final glaze.

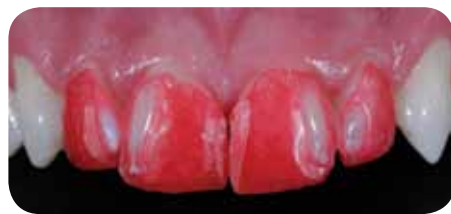

FIGURE 7A. UCV guide after being checked for proper stabilization.

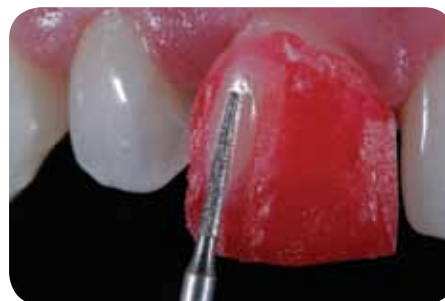

FIGURE 7B. Diamond coarse bur was used to prepare the tooth, only in the area prepared in the lab. Note the UCV guide was the reference for the preparation.

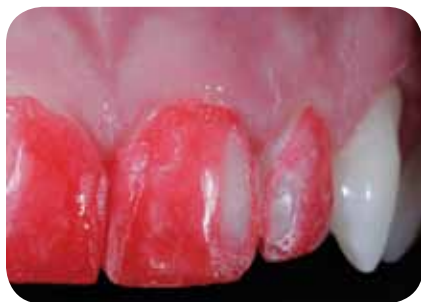

FIGURE 8A.

FIGURES 8A-B. Pictures showing the reduction done through the acrylic UCV guide.

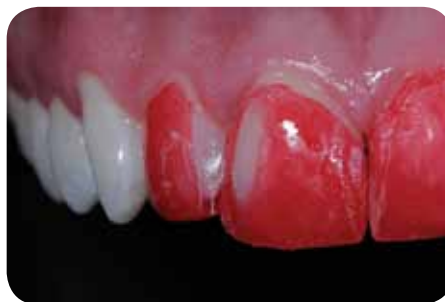

FIGURE 8B.

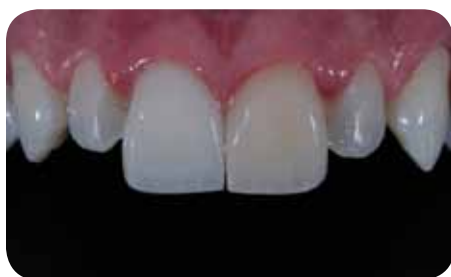

FIGURE 9. Close-up view of the central incisors with a try-in paste to select the shade of the resin cement. It can be seen the high value +2 on the tooth No. 8 and on the tooth No. 9 low value -2.

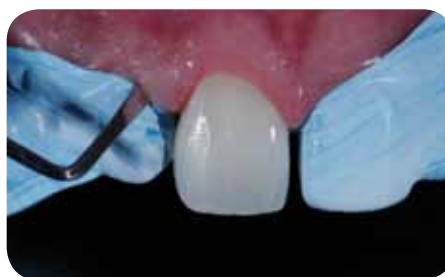

FIGURE 10. For bonding veneer on No. 8, the neighboring teeth were isolated for better handling and clinical control.

As planned, no preparation was done within the mouth and the lab would drive any reduction necessary to develop the space required for the restoration, as well as the correct path of insertion. In this manner before the preparation on the cast, the ceramist created a “preparation guide,” called a UCV (ultimate ceramic veneer) guide made with a pattern acrylic resin. In the specific area that needed to be prepared to develop the path of insertion, a UCV guide was made and the reduction was done through the acrylic until the stone was reached (FIGURES 5A-B). After the reduction guide was removed, the clearance was checked with the help of a previously made silicon index. If more room was necessary, the guide was repositioned and more stone was removed, always through the preparation guide. The same acrylic resin guide (UCV guide) used in the cast would be the tool for intraoral tooth reduction.

The clearance available for the ceramic was checked with the silicon guide in the modified cast. Ceramic final restorations were done (FIGURE 6A). Six laminate veneers were built in a refractory dye technique using a fluorapatite based glass ceramic (IPS d.SIGN, Ivoclar Vivadent, Amherst, N.Y.) (FIGURE 6B). Morphologic correction and marginal adaptation were performed, and the veneers adjusted on the master cast prepared by the technician.

Laminate veneers were checked in the master cast and delivered to the clinician.

Using the Ultimate Ceramic Veneer Guide for Teeth Reduction

At this stage, the clinician received from the laboratory: an intact cast, a waxed one, the modified prepared cast, the trim guide, and the final restorations.

The UCV guide was positioned on each tooth for controlled reduction.

The UCV guide was positioned on each tooth for controlled reduction. It is extremely important the guide is stable for preparation (FIGURES 7A-B). A thin, tapered diamond bur (No. 5011979UO Brasseler, Savannah, Ga.) was used to reduce the labial crest of the maxillary incisors, as it was reduced in the laboratory phase (FIGURES 8A-B). No reduction was necessary in interproximal areas.

After the preparation was finished, each laminate veneer was tried on the specific tooth. If the veneer did not have a passive fit, the UCV guide was repositioned and a slight adjustment was done with the help of an abrasive disk. The following step was as usual with any indirect restoration: checking marginal adaptation, interproximal contact, anatomic characteristics, and shade.

Try-in and Bonding Procedures

As previously mentioned, no temporary restoration was used. The soft tissue remained stable, and for this reason it was not necessary to have any special hemostatic control protocol. The final bonding of the ceramic restorations was preceded by a try-in procedure to select the best shade of the resin cement to obtain a perfect match with the surrounding dental structure. The laminate veneers final shade is dependent also by the resin cement. The try-in paste (Variolink Veneer Try-in Paste, +2 High Value, Ivoclar Vivadent) was applied, checked, and approved by the clinician and the patient. In FIGURE 9, it is possible to observe the difference between the two shades of the resin cement, in tooth No. 8, +2 high value and in No. 9, -2 low value.

The intaglio surface of the laminate veneers made with a fluorapatite glass ceramic was etched with hydrofluoric acid (9 percent) for 90 seconds. After being

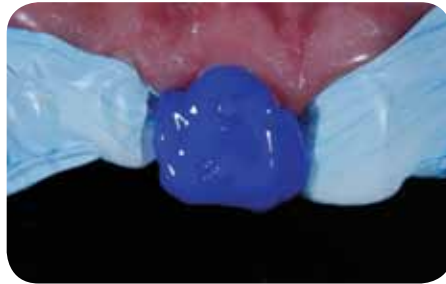

FIGURE 11A.

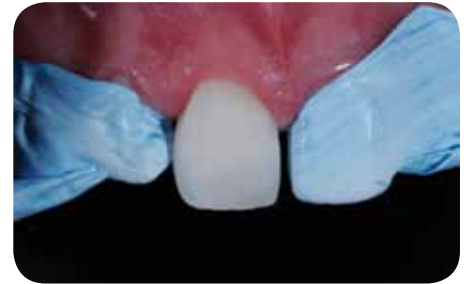

FIGURE 11B.

FIGURES 11A-11 B. Phosphoric acid were applied for 60 seconds, washed, and the surface air-dried.

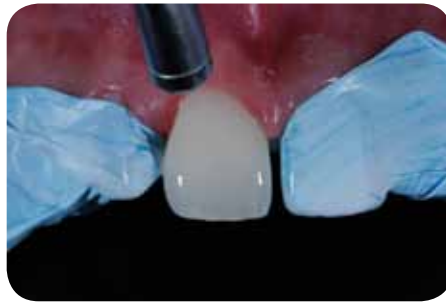


FIGURE 12A. A hydrophobic bonding agent was applied and air-thinned.

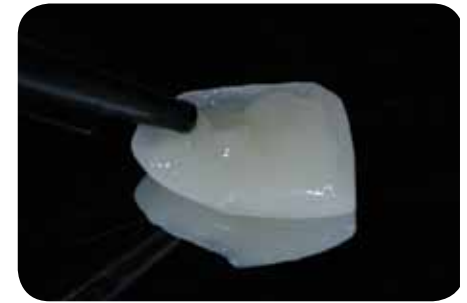


FIGURE 12B. Photo-cured resin cement was injected in the restoration to avoid air bubbles.




FIGURE 13A.




FIGURE 13B.

FIGURES 13A AND 13B. Each laminate was photo irradiated in four directions twice: 40 seconds initially and 20 seconds through a glycerin-based jelly.

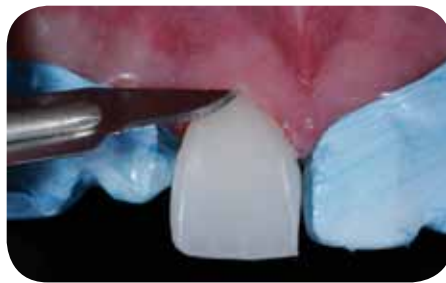


FIGURE 14. Excess of resin cement was removed with a sharp scalpel.

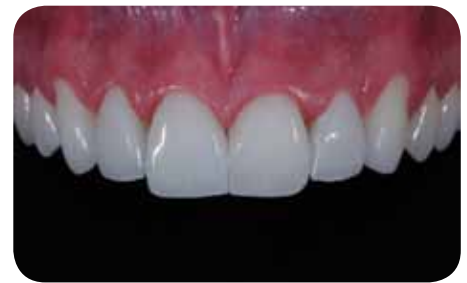

FIGURE 15. Immediate final result with lip retractor.

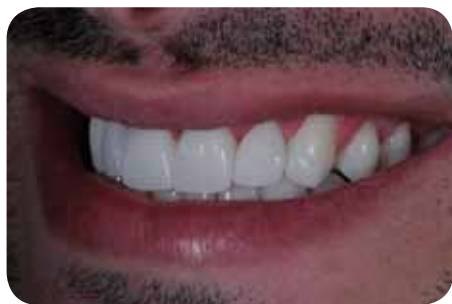

FIGURE 16A.

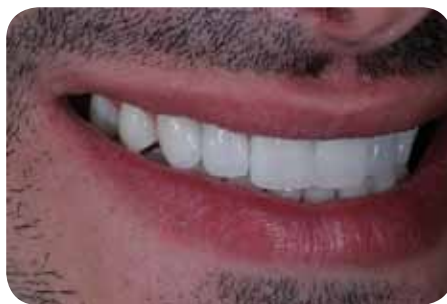

FIGURE 16B.

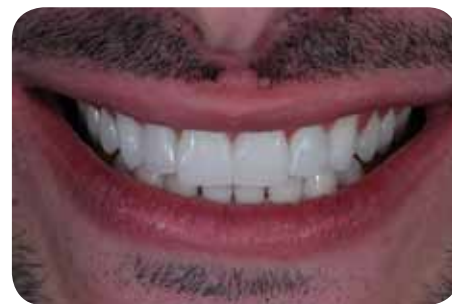

FIGURE 16C.

FIGURES 16A-C. Final result obtained with four laminate on maxillary incisors and two partial veneers on canines.

washed to remove the acid, the veneers were placed in a receptacle with distilled water for five minutes. Ultrasonic cleaning was utilized to remove the residual material originated by the etching procedure.³ Following a silane-coupling agent applied for two minutes, the evaporation of the solvent was completed with a constant blow of air. Then the intaglio surface was coated with a hydrophobic bonding agent (Heliobond, Ivoclar Vivadent), and thinned by a gentle blow of air. The adhesive was left uncured and the restoration was protected with a black plastic cover to avoid premature adhesive polymerization.

The enamel was pumiced for cleaning. For better handling and easy cleaning, one veneer was bonded each time. The neighboring teeth were isolated with plumber tape (FIGURE 10). The surface of each tooth was etched with a 37 percent phosphoric acid (Ultraetch, Ultradent) for 60 seconds, washed, and dried (FIGURES 11A-B). The same adhesive used for the intaglio surface of the ceramic was applied and also left uncured (FIGURE 12A). For laminate veneers, a light-cured resin cement is indicated for better color stability.

The previous select shade resin cement (Variolink Veneer, +2 High Value, Ivoclar Vivadent) was injected carefully onto the ceramic veneer and positioned on the specific tooth (FIGURE 12B). After resin cement excess removal, a light source was utilized for 40 seconds in four directions (FIGURE 13A). A glycerin-based jelly (Liquid Strip, Ivoclar Vivadent) was applied to air block. Each surface was

light-cured once more for 20 seconds (FIGURE 13B). A new and sharp scalpel was used to remove the excess of adhesive and resin cement (FIGURE 14). This procedure must be carried out with caution to avoid scratches on the ceramic surface.

Only one veneer was cemented each time because of easy positioning and cleaning procedures. Interproximal finishing procedures were performed with abrasive composite resin strips (Epitex, GC America). Occlusal adjustments were done with diamond polishing systems specific for ceramics (Optrafine System Ivoclar Vivadent). Every interproximal space was flossed to check if any excess was present. In the final pictures, it is possible to see the esthetic quality of the laminate veneers (FIGURES 15, 16A-C).

Conclusions

The proposed technique can be used for any laminate veneer case with minimal preparation. Careful treatment planning with an additive wax-up helps the clinician develop conservative preparations planned in the laboratory. The UCV technique can be utilized to minimize tooth preparation and preserve enamel.¹⁴ Along with precise bonding and occlusal adjustments, it fulfills the requirements for long-term clinical success.

A case planned in the laboratory may help dental technicians and dentists deliver high-quality restorations to a large number of patients with minimal tooth preparation, avoiding excessive loss of sound tooth structure. ■■■■

REFERENCES

1. Smales RJ, Etemadi S, Long-term survival of porcelain veneers using two preparations designs: a retrospective study. *Int J Prosthodont* 17(3):323-6, May-June 2004.
2. Burke FJ, Lucarotti PS, Ten-year outcome of porcelain veneers placed within the general dental services in England and Wales. *J Dent* 37(1):31-8, January 2009.
3. Magne P, Belser U, Bonded porcelain restorations in anterior dentition: a biomimetic approach. Chicago, Quintessence 2002.
4. MacLaren EA, Whiteman YY, Ceramics: rationale for material selection. *Compend Contin Educ Dent* 31(9):666-8,70,72, November-December 2010.
5. Kina S, Brugera A, Invisible: Esthetic Ceramic Restorations Artes Medicas, 2009, Sao Paulo, Brazil.
6. Gurel G, The science and art of porcelain laminate veneers. Quintessence Pub, Berlin, Germany, 2003.
7. Calamia JR, Calamia CS, Porcelain laminate veneers: reasons for 25 years of success. *Dent Clin North Am* 51(2):399-417, April 2007.
8. Chan C, Weber H, Plaque retention on teeth restored with full-ceramic crowns: a comparative study. *J Prosthet Dent* 56(6):666-71, December 1986.
9. Duarte S Jr., Phark JH, et al, Ceramic systems: an ultrastructural study. *Quintessence Dental Technol* 33:42-60, 2010.
10. Dumfahrt H, Schäffer H, Porcelain laminate veneers: part II — clinical results. *Int J Prosthodont* 13(1):9-18, January-February 2000.
11. Peumans M, De Munck J, et al, A prospective 10-year clinical trial of porcelain veneers. *J Adhes Dent* 6(1):65-76, spring 2004.
12. MacLaren EA, LeSage B, Feldspathic veneers: what are their indications? *Compend Contin Educ Dent* 32(3):44-9, April 2011.
13. Scopin de Andrade O, Kina S, Hirata R, Concepts for an ultraconservative approach to indirect anterior restorations. *Quintessence Dental Technol* 34:103-19, 2011.
14. Scopin de Andrade O, Romanini JC, Hirata R, Ultimate ceramic veneers: a laboratory-guided ultraconservative preparation concept for maximum enamel preservation. *Quintessence Dental Technol* 35:29-43, 2012.
15. Magne P, Belser UC, Novel porcelain laminate preparation approach driven by a diagnostic mock-up. *J Esthet Restor Dent* 16(1):7-16, 2004.

TO REQUEST A PRINTED COPY OF THIS ARTICLE, PLEASE CONTACT Oswaldo Scopin de Andrade, DDS, MS, PhD, Rua Barão de Piracicamirim, 889 No. 61, Piracicaba, SP, Brazil, CEP 13416-005.

Tired of Price Increases on Over-Priced Implants?




It's Time for a Reality Check. Choose Implant Direct for...
Innovative Products. Great Value. Highest Customer Satisfaction¹

Legacy™3 Implant

All-in-1 Packaging includes implant, abutment, transfer, cover screw & healing collar
\$175 vs \$621² from Zimmer Dental

✓ **Reality Check**
Zimmer Customers
Save \$446 with Legacy3



SwishPlant™ Implant

All-in-1 Packaging includes implant, straight abutment/transfer, cover screw & healing collar
\$200 vs \$705³ from Straumann®


✓ **Reality Check**
Straumann Customers
Save \$505 with SwishPlant



ReActive™ Implant

All-in-1 Packaging includes implant, abutment, transfer & cover screw
\$200 vs \$694⁴ from Nobel Biocare™

✓ **Reality Check**
Nobel Customers
Save \$494 with ReActive



Implant Direct's New Las Vegas Training Center

Implant Direct offers an extensive list of educational opportunities at its Las Vegas Training Center with computers at each desk for Image Guided Surgical Training, models/mannequins for hands-on training and a four chair dental office for live surgical demonstrations.

Debut Courses: June 1-3 | July 20-22 | September 28-30

For information on courses and dates, both in Las Vegas and throughout the US, visit Implant Direct's website or use your smart phone to link directly to our Educational Section.



EARN 2 CE CREDITS FREE: View Online Lecture with 3D Graphic Videos & Answer 13 Test Questions



The Changing Reality of Implant Dentistry

Presented by Dr. Gerald Niznick

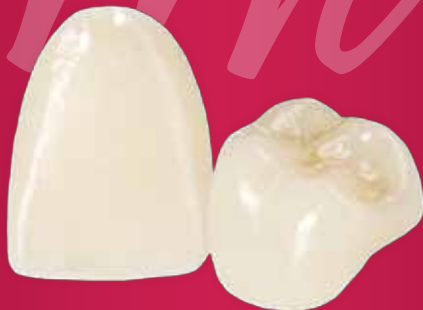Technological advances and economic factors have shifted the implant industry toward affordable care.

Continuing education credits may not apply toward license renewal in all states.
It is the responsibility of each participant to verify the requirement of his/her states licensing board(s).
Price comparisons based upon US list prices as of February 2012. All trademarks are property of their respective companies.
¹Satisfied among Current and Former Users, by Company US Q21 Millenium Research Group A Decision Research, Inc. Company
²US list price for Tapered Screw-Vent with micro grooves, healing collar & straight abutment
³US list price for SLActive Tapered Effect implant, closure screw, healing abutment, solid abutment, transfer and comfort cap.
⁴US list price for NobelActive with cover screw, impression coping & abutment
Live surgical demonstrations not available at all courses

Count on Keller

IPS e.max[®]
pressed

- CAD/CAM Accuracy & Fit
- Cement or Bond
- Pressed Strength

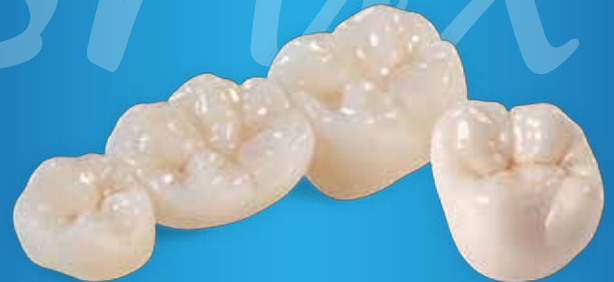

NOW

\$99
EVERYDAY

BruxZir[®]
Total Zirconia Crowns

- CAD/CAM Consistency
- Ideal for Clenchers & Grinders
- Conservative Prep



Call Today For Your Case Pick-Up!
800-325-3056



Keller Laboratories, Inc.

160 Larkin Williams Industrial Court • Fenton, MO 63026

www.kellerlab.com



**When you bundle
2 or more cases
in one box!**

**No Shipping Charge!
No Bundling Charge!
No Kidding!**

*Offer only valid in the contiguous United States.
Additional charges will apply for overnight services.



Implant-Supported Full-Mouth Reconstruction Malo Implant Bridge

TAISHI KODAMA, RDT

ABSTRACT This article describes the clinical techniques and laboratory procedures for fabricating a predictable Malo Implant Bridge involving application of an occlusal screw-retained implant superstructure on the basis of the All-on-4 concept. The Malo Implant Bridge features a removable occlusal screw-retained superstructure; fabrication of the framework with a computer-aided design/computer-aided manufacturing system allowing accurate adaptation; and use of the final tooth position model with guide temporary crowns allowing easy porcelain build-up and satisfying the patient's esthetic concerns.

AUTHOR

Taishi Kodama, RDT, is a registered dental technician in South Yarra, Australia.
Conflict of Interest
Disclosure: None reported.

ACKNOWLEDGMENT

The author received instruction regarding the All-on-4 technique, including the outline for its clinical application, from Dr. Paulo Malo. The framework is fabricated with a CAD/CAM system. The practical technique developed by the author was used in the clinical case presented here. The author would like to thank Dr. Alex Fibishenko for provision of the adequate cases and Ms. Kiyoko Ban, adviser to Noritake Dental Supply.

Recent developments in materials and techniques for implant treatment have made it possible to achieve excellent results. As a result, implant treatment, which was previously based on vague criteria, has undergone a revolution and is now based on solid theoretical guidelines.

Similarly, the superstructure systems had a marked increase in clinical safety and the probability of clinical application with the development and improvement of novel clinical approaches and materials. The success or failure of implant treatment is defined by the final esthetics. A natural-looking appearance is a major assessment criterion for patients. As information on esthetic restoration is now readily available, the esthetic demands of patients have increased. This has resulted in an increase in the tendency to attach importance to esthetics in routine clinical practice. However, as the goal of implant restoration is to return the lost

tissue and teeth to good condition, it is necessary to consider functionality in esthetic implant restoration. There have been many reports of excellent outcomes with a natural appearance of teeth and gums, even in the posterior region of the mouth as well as in the anterior region. However, to achieve good results, it is necessary to have a complete understanding of the underlying physiology and the complex methods used. Even dental technicians involved in the fabrication of prosthesis must have a good understanding of the jawbone morphology of each individual patient to determine the ideal horizontal/vertical position and direction of the implant to be placed. In addition, it is necessary to take the conditions of the alveolar mucosa into consideration.

This article presents the author's considerations regarding the implant superstructure Malo Implant Bridge through the discussion of the various steps in a dental case.

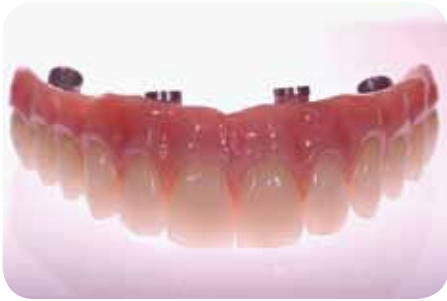

FIGURE 1. Three factors of superstructure for Malo Implant Bridge.

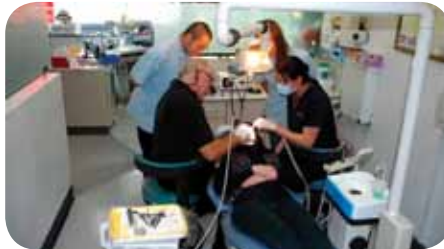

FIGURE 2. Team dental treatment is a key point for success.

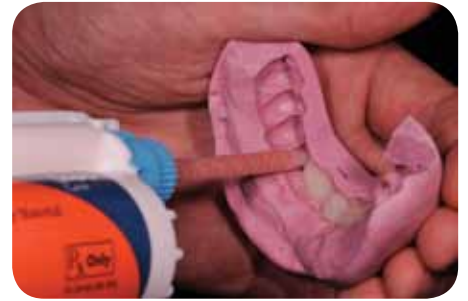

FIGURE 3A. A resin material for guide temporary crown (Integrity Temporary Crown and Bridge Material, DENTSPLY) is poured into the silicone core taken from the denture teeth.

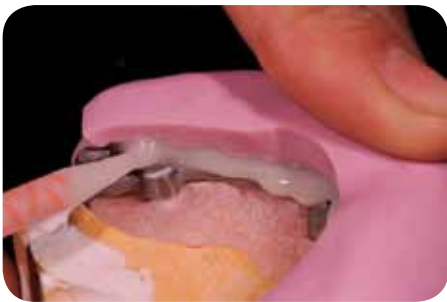

FIGURE 3B. The silicone core is replaced on the titanium framework for making up for the deficiencies before setting of the resin material.

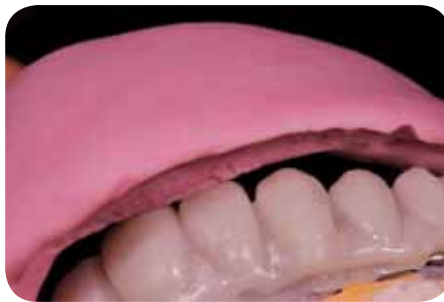

FIGURE 3C. After setting, the silicone core is removed for confirmation of whether a resin material is sufficiently filled in the entire circumference of the margins.

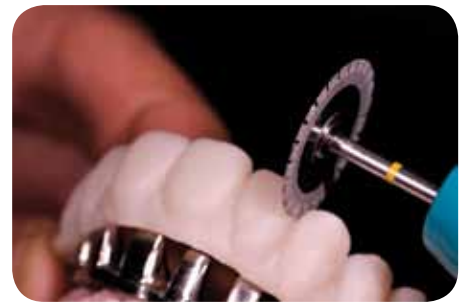

FIGURE 3D. After setting, each individual tooth is separated and the excess resin is removed for contouring of the guide temporary crowns.

Therapeutic Strategies and Treatment Flows of All-on-4 Malo Implant Bridge

1. Consultation

1. Precise operative explanation to patient and assurance of his/her understanding
2. Patient's lifestyle habits (with or without the potential of impact on implant treatment)
 - Drugs currently being taken
 - Smoker /nonsmoker

2. Patient's Facial Contour and Intraoral Examination

- Examination of both upper and lower jaws
- Panoramic radiography and computed tomography (CT)
- Understanding of intraoral conditions
- Intraoral photography
- Facial photography
- Impression-taking (preop)
- Fabrication of diagnostic model

3. Diagnosis of Individual Patients

4. Treatment Planning (Based on Diagnostic Results, Treatment Planning From the Start to the Goal Is Explained to the Individual Patients)

- Previous cases
- Esthetics
- Functionality
- Treatment period required (number of specific treatment days and visits)
- Prognosis (regular exam)
- Specific co-payment

5. Laboratory Work 1

Artificial teeth set-up for fabrication of surgical stent

6. Operation

- Placement of Novel Speedy implants
- Intraoral and facial photography after placement of surgical stent
- Impression-taking
- Bite registration

7. Laboratory Work 2

- Fabrication of master model
- Fabrication of implant-supported temporary dentures

8. Try-in 1

- Trial of wax dentures in the mouth
- Establishment of esthetics and functionality
- Occlusal adjustment
- Final adjustment based on patient's requests

9. Placement of Implant-Supported Dentures

(These dentures must be high quality in both esthetics and functionality because of replacement with Malo Implant Bridges.)

10. Laboratory Work 3

- Fabrication of silicone core from implant-supported temporary denture for fabrication of guide temporary crowns

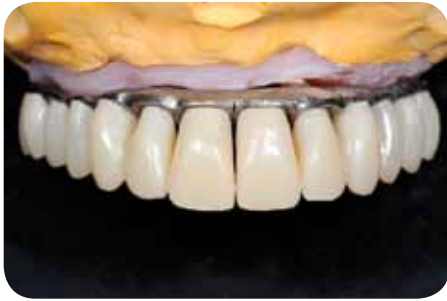

FIGURE 3E. Each contact point between the guide temporary crowns is adjusted for completion of the guide temporary crowns.

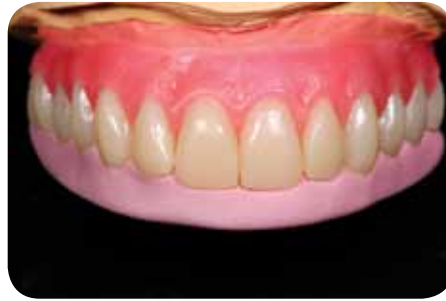

FIGURE 3F.

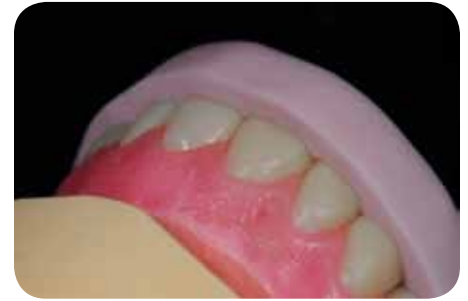

FIGURE 3G.

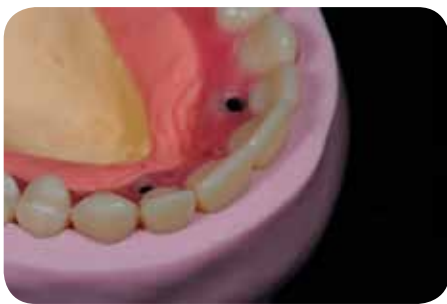

FIGURE 3H. The operator must use the silicone core taken from the guide temporary crowns for duplication of the set-up.



FIGURE 4. Titanium implant bridge fabricated by a CAD/CAM system (Stone Glass Industries).

- Fabrication of metal framework with a computer-aided design/computer-aided manufacturing (CAD/CAM) system
- Fabrication of metal-ceramic crowns

11. Try-in 2

- Try-in of biscuit-baked metal-ceramic crowns with titanium framework in the mouth
- Establishment of esthetics and functionality
- Occlusal adjustment
- Final adjustment based on patient's requests

12. Laboratory Work 4

- Final glazing of metal-ceramic crowns
- Cementation of metal-ceramic crowns on titanium framework
- Replacement of gum with resin material

13. Placement of Malo Implant Bridge in the Mouth and Finish

Superstructure for Malo Implant Bridge

The superstructure design for the Malo Implant Bridge is extremely simple. Furthermore, the steps recommended here allow excellent results without stress. Its greatest advantage is the ease of dealing with prognostic troubles. The Malo Implant Bridge consists of (**FIGURE 1**): metal framework supporting the superstructure, metal-ceramic crowns, and the gum area replaced with a resin material.

The three types of material mentioned above are best suited for the intraoral environments. In many cases, because of fracture or breakage several years after placement of All-on-4 implant-supported dentures, they are frequently replaced with the Malo Implant Bridge to achieve greater strength and a more natural-looking appearance. Recently, full-arch zirconia prostheses have become clinically available. However, in such cases, use of metal seems to have several advantages over zirconia because use of titanium as a framework material allows marked

enhancement of strength of the superstructure. In addition, fabrication of the titanium framework with a CAD/CAM system on the basis of the temporary denture and the metal copings placed on each abutment tooth allows maintenance a sufficient space to build up porcelain to duplicate the natural tooth color. All-ceramic crowns are better for duplication of the natural tooth color than metal-ceramic crowns. However, a space for porcelain build-up maintained through the framework calculated by careful design allows free build-up of porcelain metal-ceramic crowns compared to all-ceramic crowns. As a result, use of metal-ceramic crowns has advantages over use of all-ceramic crowns. The use of zirconia crowns may lead to transmission of the metal color of the titanium framework, and, therefore, opaque porcelain must be applied to the titanium abutment tooth region of the titanium framework.

However, this is not necessary with metal-ceramic crowns. The Malo Implant Bridge has an occlusal screw-retained type connection. As the required life spans of dental implants have become longer, there has been a decrease in use of removable implant superstructures. However, removable type implants are much more convenient than cemented-retained type that cannot be removed if necessary, and minimizing complex junction areas reduces the possibility of problems. In addition, there are advantages to replacement of the gum with a resin, which allows easy repair, including under conditions of fracture and breakage. Thus, the occlusal screw-retained type is often used in daily dental practice.¹⁸

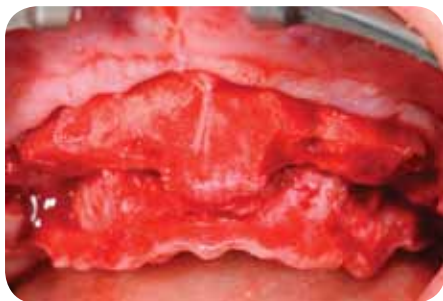


FIGURE 5A. The soft tissue and bone at the required sites were excised to confirm the bone volume.

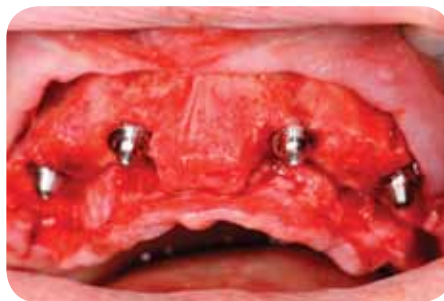

FIGURE 5B. The soft-tissue area located in the center of the picture was left intentionally as a guide to determine the anterior placement position, which will be excised after implant placement.

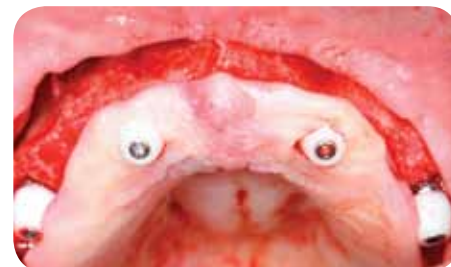

FIGURE 5C. The excised soft tissue was replaced to the original position to place healing caps.

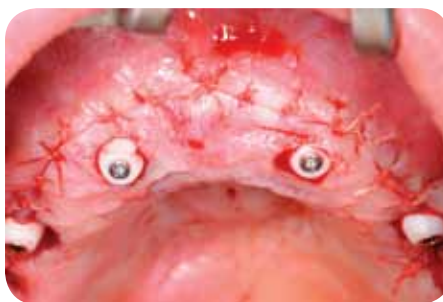

FIGURE 5D. Following completion of suturing, the impression was taken.

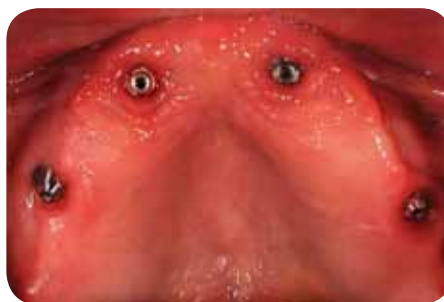

FIGURE 6A. Nobel Biocare Regular Platform Multi-Unit abutments were used.

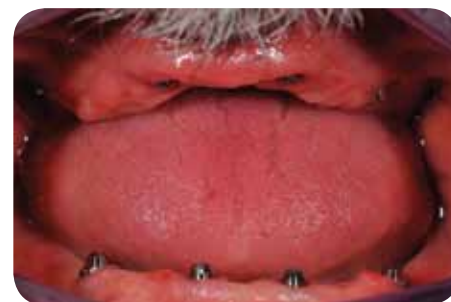

FIGURE 6B. Intraoral view.

From the Model to the Mouth

Dental technicians are more likely now to directly view the patient's mouth because of an increase in understanding of the value of such practices by dentists. The author, working in Australia, is such a dental technician (**FIGURE 2**).

However, it is difficult for technicians to participate in all stages of treatment because of time constraints associated with completing laboratory work. As laboratory work is performed on working models, dental technicians must be able to predict the color and morphology of the prosthesis once it is in the patient's mouth and whether the prosthesis fits well in the mouth.

The author's dental laboratory and the dental clinic are located in the same building, so the author often comes into contact with patients and can directly view their mouths. Therefore, the author has become aware that there are small deviations between the model and the mouth. For the wider prosthetic area, it

becomes more difficult to imagine this minor deviation three-dimensionally in the mouth. The development of a means to evaluate such minor deviations on the model would increase the accuracy of the prosthesis in the mouth and thus minimize the need for remaking of prostheses.⁷

Therefore, the paper proposes use of the final tooth position (FTP) model described below to resolve such problems.

FTP Model and Silicone Cores

To implement treatment planning for fabrication of the implant-supported occlusal screw-retained implant bridge (Malo Implant Bridge), various factors, including the occlusal vertical dimension, the occlusal plane, and the position and shape of the dental arch that can predict the final morphology (final prosthesis) in the mouth must be determined prior to implant placement at the correct position. Following implant placement, fabrication of the provisional restoration or temporary denture allows evaluation and confirmation in the mouth.

Provisional restoration is important in fabrication and in determining the prognosis of the final prosthesis. The patient must carry temporary crowns in the mouth for several weeks or months. In some cases, the patient becomes used to temporary crowns over time and complains that they were better than the final prosthesis. The larger the prosthesis to be remade, the greater the workload for the dental technician. The study model is traditionally used by technicians. In the author's laboratory, the temporary crowns are placed in the patient's mouth and an impression is taken. This impression is then used to fabricate the study model by covering with dental stone, which is used as a guide during the porcelain work.^{2,9,10,13}

However, the guide temporary crowns used in the FTP model, which are fabricated by taking the silicone core from the temporary denture placed in the patient's mouth for duplication of the shape, but a resin and not dental

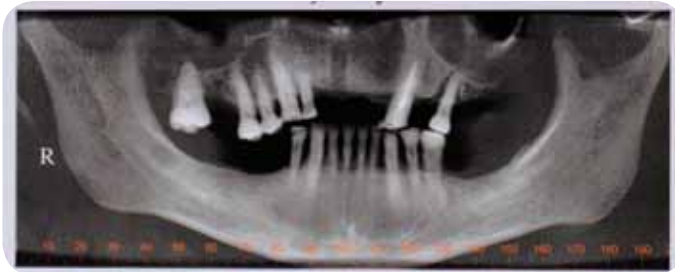

FIGURE 7A. The radiograph on initial examination.

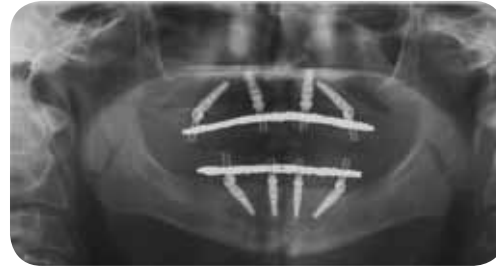


FIGURE 7B. The radiograph after implant placement.

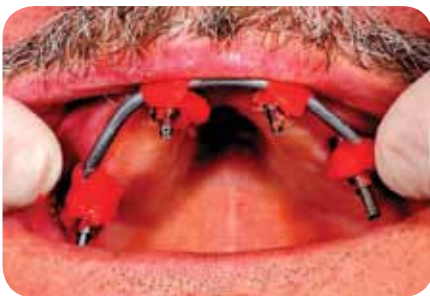

FIGURE 8A. Stainless-steel rods.

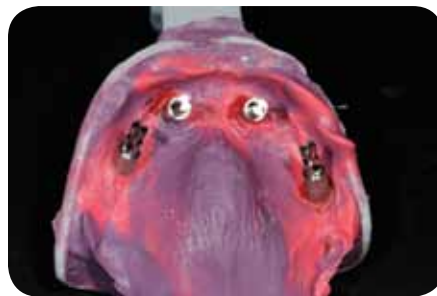

FIGURE 8B. The replica analogues were placed into the impression followed by pouring with dental stone.

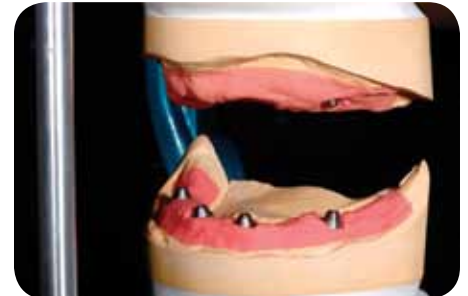

FIGURE 9. Both upper and lower working models mounted on an articulator.

stone is used only in the tooth region (FIGURES 3A-C). Each individual tooth of the temporary denture is separated to allow removal of teeth individually from the tooth preparation model (FIGURES 3D-E) for 3-D evaluation on the model. At the same time, the silicone cores are fabricated from the guide temporary crowns (FIGURES 3F-H). These silicone cores are used as guides for preparation of the framework with a CAD/CAM system and calculation of a space for porcelain build-up from abutment tooth and metal coping, and are helpful in porcelain build-up.

If these processes are performed before porcelain build-up, as the guide temporary crowns can be individually removed from the framework for evaluation, even in cases with a long-span bridge, the dental technician can concentrate only on individual teeth. This leads to a marked reduction in dimensional errors between the model and the mouth. This method can markedly reduce the chairtime, including try-in, and, thus, case patient burden.

Existence Significance of Using FTP Model in Daily Dental Practice

1. Establishment of esthetics and functionality based on patient's request

- Length
- Width
- Contour
- Incisal edge

2. Establishment of functional occlusion (adjustment and confirmation)

- Occlusal relationship with opposing teeth
- Vertical positional relation with abutment teeth

3. State observation of periodontal soft tissue (protection and recovery)

- Confirmation of self-cleansability and functionality
- Response to surgical procedure, etc.

4. Protection of remaining tooth structure, dental pulp and functional mucosa

5. Evaluation of pronunciation improved by morphological recovery

6. Communication between dentists and dental technicians

7. Communication in the dental laboratory

8. Communication with patients

Check Items for Basic Esthetics and Functionality Required in Fabrication of Implant-Supported Occlusal Screw-Retained Implant Bridge (Malo Implant Bridge)

- Recovery and current condition of gum
- Positional relationship of the teeth (relative size and shape)
- Position and length of incisal edge determined from vertical relationship and lip position
- Tooth contour in consideration of lip support
- Color and surface texture of tooth

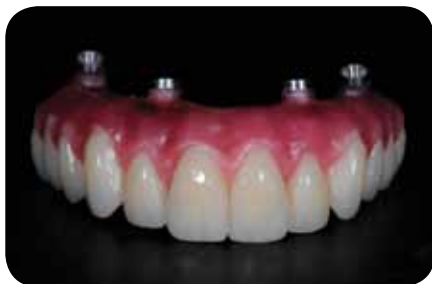

FIGURE 10. Using ready-made artificial teeth (Premium, Heraeus Kulzer), the implant-supported temporary dentures were completed.

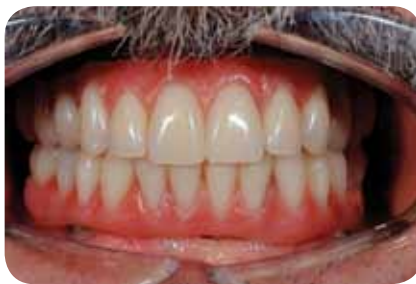

FIGURE 11. Following correction, the occlusion was readjusted. After several weeks, these dentures were shown to be satisfactory.

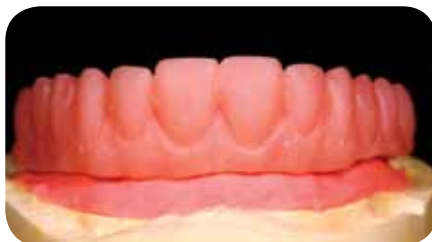

FIGURE 12. An auto polymerizing acrylic resin (GC Unifast Trad, Alpha Bond Dental) was used to duplicate the implant-supported temporary dentures.

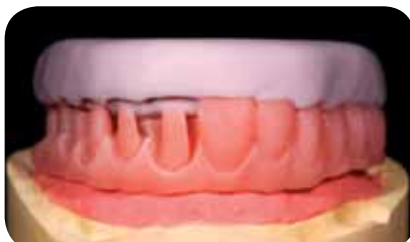

FIGURE 13. The silicone cores were taken from the duplicated implant-supported temporary dentures.

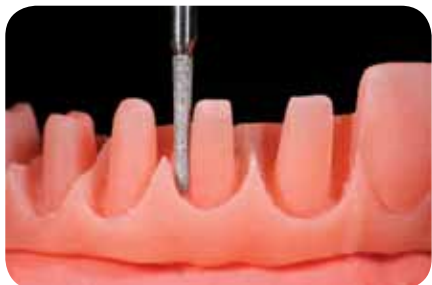

FIGURE 14A.

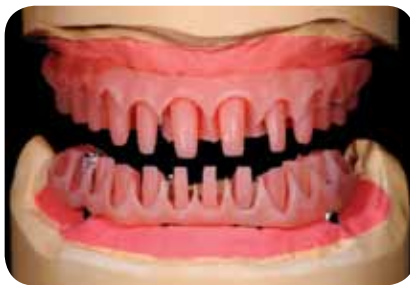

FIGURE 14B. The strength of the framework and each space for porcelain build-up were adjusted with both the upper and lower models mounted on the articulator.

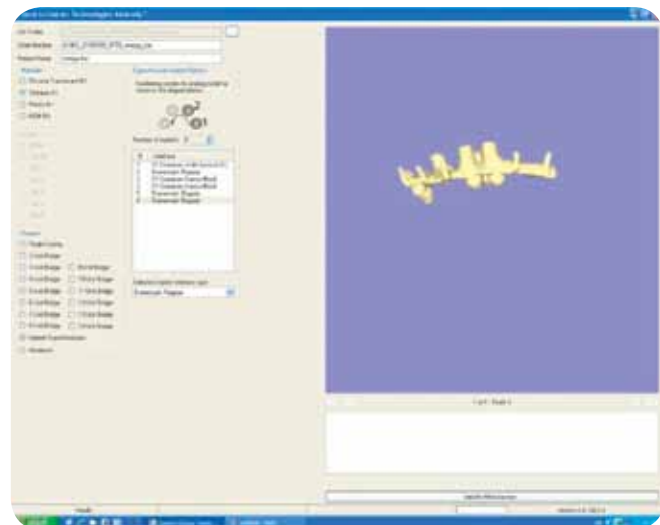


FIGURE 15. Scanning of the framework with a computer (Stone Glass Industries).

- Tooth axis determined from patient's facial contour
- Occlusal height
- Mandibular position
- Balance based on occlusal plane
- Volume of resin material used for gum replacement (determination of contour)
- Check of cleaning ability

Implant Metal Framework

The CAD/CAM approach has been established as a new method for fabrication of implant superstructures. A zirconia framework fabricated with the CAD/CAM system appears to be stronger because of its increased thickness, compared with the titanium framework shown in **FIGURE 4**. However, the titanium framework is lighter and stronger than the zirconia framework, allowing the design of thinner and smaller frameworks. Consequently, the titanium framework can minimize the burden within the patient's mouth.

Traditionally, the implant metal framework was often fabricated through the casting process with pure titanium or titanium alloys. However, the precision casting technique may involve several risks and problems. The major problems are due to mechanical deformation and include:

- 1) Deformation during impression-taking;
- 2) Setting expansion during pouring of dental stone;
- 3) Deformation (shrinkage) during waxing-up;
- 4) Thermal expansion caused by an investment material;
- 5) Casting shrinkage;
- 6) Deformation of metal framework caused by stress produced by primary and secondary soldering; and
- 7) Deformation caused by stress produced in the porcelain furnace during porcelain baking.

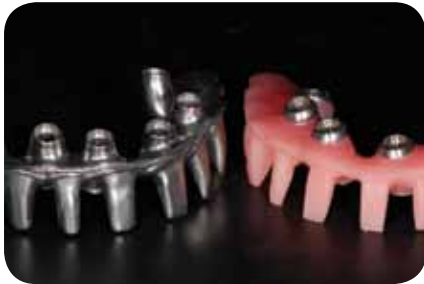

FIGURE 16. Titanium framework and resin framework. A CAD/CAM system is shown to be high accuracy.

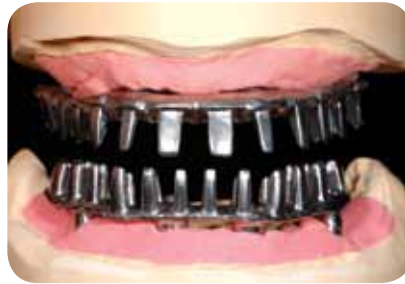

FIGURE 17. Upper and lower frameworks placed on each model.

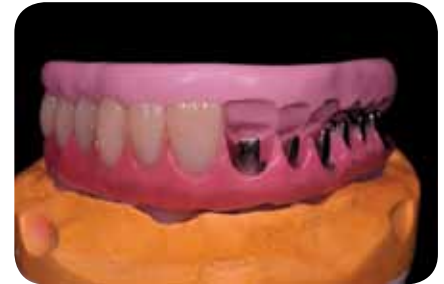

FIGURE 18.

There are several alternative approaches to avoid these risks, such as the use of a cement-retained implant prosthesis or separation of a full arch into three units (i.e., anterior and bilateral posterior regions).

However, the milling technique in which a metal block is machined has been introduced in dentistry with the development of CAD/CAM technology. CAD/CAM systems are particularly useful in cases with long-span bridges. Adaptability is crucial. It is particularly important to avoid strange sensations in the patient's mouth due to the implant as well as to achieve excellent long-term functionality of the prosthesis. Therefore, the implant bridge must be fabricated to minimize loading of occlusal force on the implants. The CAD/CAM approach can be used to resolve these problems. Even in cases with long-span bridges, the framework calculated on computer and milled from a block is highly accurate. Therefore, the dental technician can choose from the two types of material and fabrication approach:

1) The prosthesis is completed by setting up artificial teeth on the titanium framework or fabricating each individual metal-ceramic crown.

2) The prosthesis is completed by building up porcelain directly on the zirconia framework or fabricating each individual zirconia crown.

The author most frequently fabricates metal-ceramic crown type of prostheses. However, as the criteria differ between patients, the operator must choose the most adequate pros-

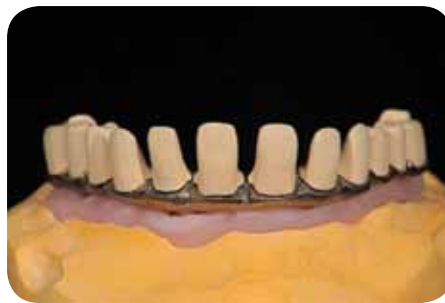

FIGURE 19A.

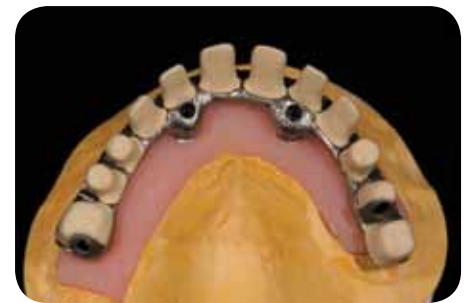

FIGURE 19B. The opaque porcelain was applied to each metal coping and baked.

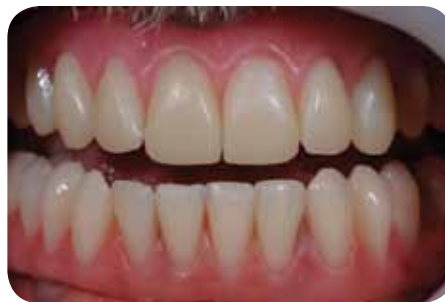

FIGURE 20A. The upper and lower guide temporary crowns were placed in the mouth to check the balance with the lips.

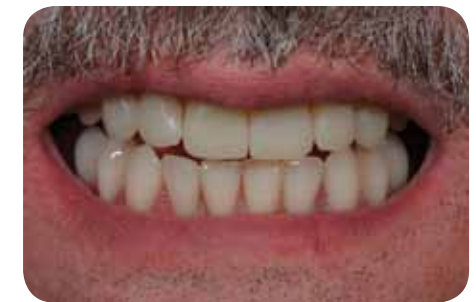

FIGURE 20B.

thetic method by taking the respective advantages and disadvantages into consideration. In all cases, an increase in the reliability of the framework supporting the implant bridge reduces the burden on the operator and simplifies the procedures required to fabricate and fit the prosthesis.

Difference in weight of almost identical morphological framework:

	<i>Maxilla</i>		<i>Mandible</i>
Ti	8.1g	Ti	6.9g
Co-Cr	20.3g	Co-Cr	18.2g
Zi	17.5g	Zi	15.1g

Case Report

A 68-year-old male patient had a prosthesis that on initial examination was shown to be inadequate with regard to both esthetics and functionality in his mouth. As the patient had a severe speech defect and tooth mobility due to periodontal disease and presented with masticatory dysfunction making it impossible of chew food, implant treatment was required as early as possible. Taking into consideration the functional requirements and the patient's desire for a natural-looking smile, it was decided to use an All-on-4

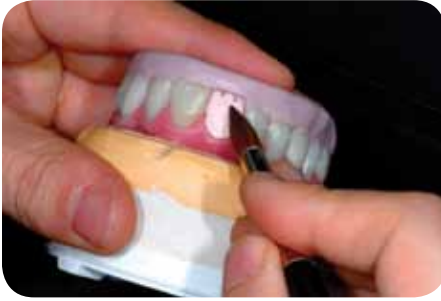

FIGURE 21A. The silicone core should always be used to build up porcelain (first baking) (Noritake Super Porcelain EX-3, Alpha Bond Dental).

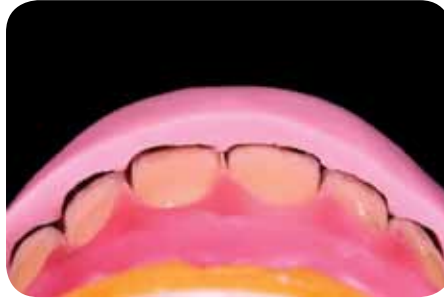

FIGURE 21B. Following first baking, the silicone core in the incisal third is used to verify a sufficient space available for building up the luster porcelain (translucent porcelain).

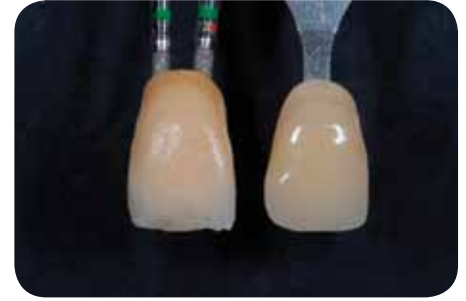

FIGURE 21C. Application and baking of internal stain. The picture shows the situation where the stain was applied and baked following first baking. In the present case, attention must be paid on selecting a slightly higher color in chroma and value than the selected shade guide for appropriate characterization and color controls (Noritake Internal Live Stain, Alpha Bond Dental).

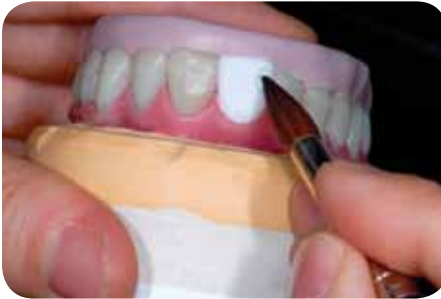

FIGURE 21D. The luster porcelain was built up. Similar to initial porcelain build-up, the silicone core must be used to facilitate porcelain build-up to each individual tooth (Noritake Super Porcelain EX-3, Alpha Bond Dental).

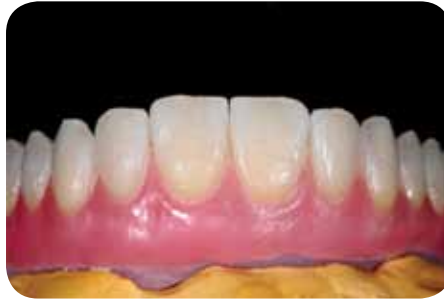

FIGURE 22A.

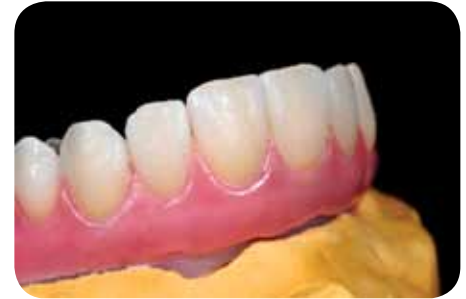

FIGURE 22B. The duplication of the guide temporary crowns allows porcelain build-up in short time. Contouring using a diamond bur can be finished in an hour and a half, even a full-arch porcelain restoration.

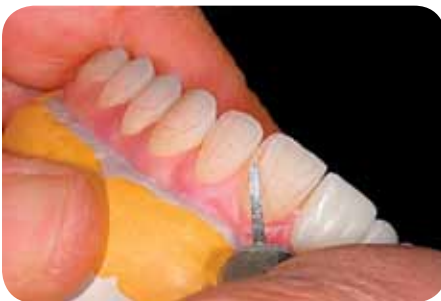

FIGURE 23A. Contouring was performed on the working model.

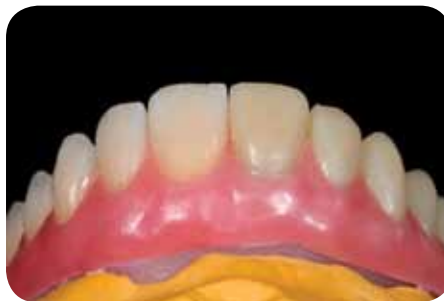

FIGURE 23B. The porcelain biscuit-baked crowns (left) and the guide temporary crowns (right) fabricated for the FTP model were compared on the titanium framework, respectively. This allows easy confirmation of the length, width, tooth axis, and position of each porcelain crown.

Malo Implant Bridge for reconstruction.

Four implants (Nobel Biocare) were placed in both the maxilla and mandible (FIGURES 5A-D), and no problems were encountered during the three-month treatment period. Nobel Biocare Regular Platform Multi-Unit abutments were used (FIGURES 6A-B AND 7A-B), and an impression was taken to fabricate the working model (FIGURES 8A-B AND 9).

The implant-supported temporary dentures were fabricated using artificial resin teeth (Premium, Heraeus Kulzer) (FIGURE 10). As these temporary dentures determine all positional relationships, the wax dentures must be tried in the mouth. All corrections must be performed in this process to utilize the temporary dentures as a template for the final prosthesis Malo Implant Bridge, and the patient's esthetic and functional demands must be satisfied. This

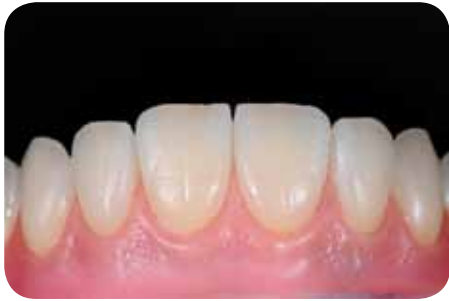

FIGURE 24A. Completion of counterering on the working model.

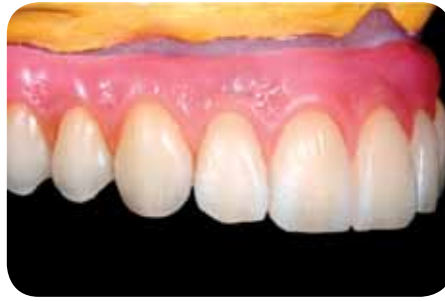

FIGURE 24B.

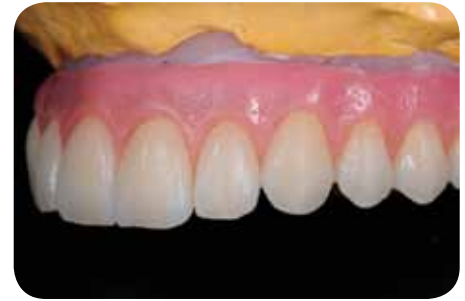

FIGURE 24C.

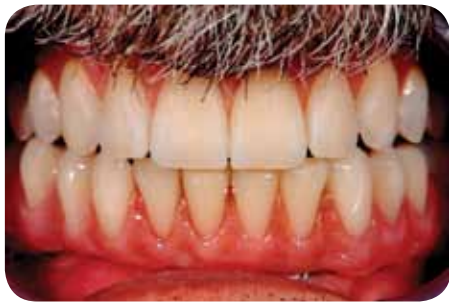

FIGURE 25A. Biscuit-bake try-in.

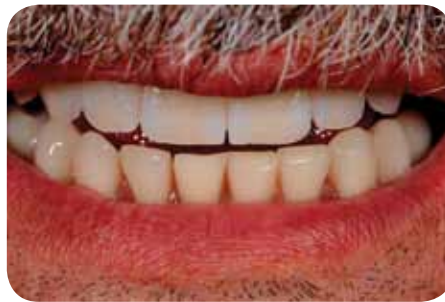

FIGURE 25B. The balance with the lips is verified.

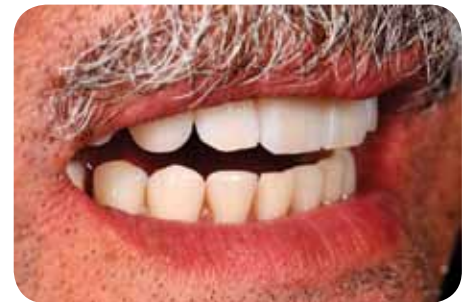

FIGURE 25C.

facilitates the subsequent procedures.

The upper and lower implant-supported temporary dentures were fabricated and placed in the patient's mouth to observe for several weeks. The maxillary lateral incisors were fractured many times during this observation period, which seemed to be due to the insufficient interocclusal space. This problem should be corrected at this stage before proceeding to the next step (FIGURE 11).

The implant-supported temporary dentures placed in the mouth were duplicated to make a replica for fabrication of a resin framework (UniFast Trad, GC). Of course, this replica after duplication can be replaced on the implant analogues on the master model (FIGURE 12).

The silicone cores were fabricated from the implant-supported temporary denture replaced on the master model to allow evaluation from various angles and used as a guideline for fabrication of the framework and porcelain build-up. This allowed verification of the required positional relationships at each step (FIGURE 13).

The framework was formed by milling from a block. Use of the prefabricated

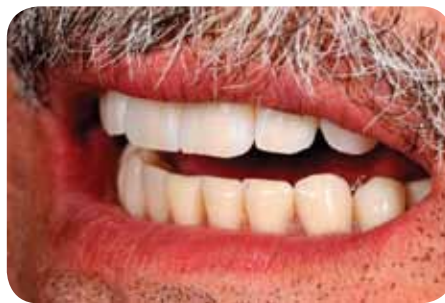

FIGURE 25D. The porcelain prosthesis fabricated with the guide temporary crowns and silicone cores had little deviation between on the model and in the mouth.

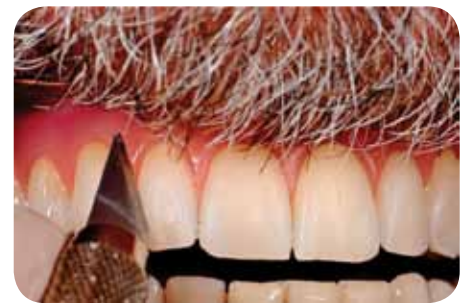

FIGURE 25E. A minor adjustment of soft tissue was performed in the mouth during try-in.

silicone core allowed formation of an accurate framework by milling while confirming the appropriate reduction and tooth axis (FIGURES 14A-B).

The resin framework was scanned with a computer (Stone Glass Industries) in the laboratory (FIGURE 15).

The titanium framework fabricated by CAD/CAM (Stone Glass Industries) was more accurate and smaller than the resin framework fabricated for scanning²² (FIGURE 16).

The titanium framework was replaced on the master model to confirm accuracy of fit (FIGURE 17). The guide

temporary crowns separated into each individual tooth were fabricated on the titanium framework using the temporary denture and silicone core for use during porcelain build-up, and the gum area was replaced with paraffin wax to confirm the balance with each crown (FIGURE 18). In addition, the guide temporary crowns were removed and wax gum only was left to confirm the space for porcelain build-up surrounding the cervical area.

The metal coping was fabricated on each individual abutment tooth designed on the titanium framework and

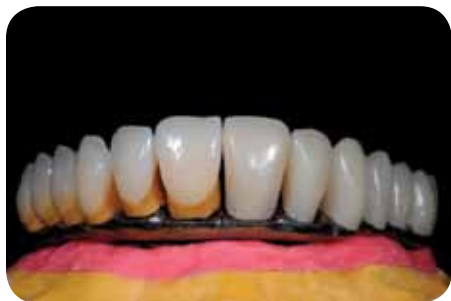

FIGURE 26A. The metal-ceramic crowns were glazed for completion. These had little deviation, compared with the guide temporary crowns on the model. The results revealed that the guide temporary crowns played a major role.

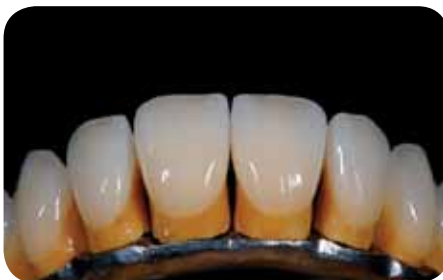

FIGURE 26B.

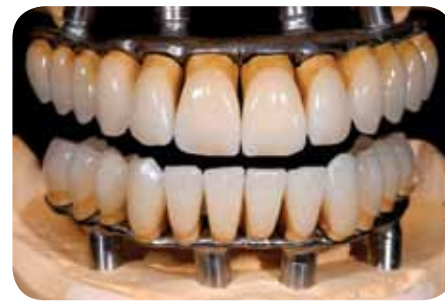

FIGURE 26C. The gum area replaced with paraffin wax was removed for the final verification of all contact points before cementation.



FIGURE 27A.

FIGURES 27A-B The pink opaque porcelain (VITA HLC C-12, Henry Schein HALAS) was applied to the titanium framework.



FIGURE 27B.

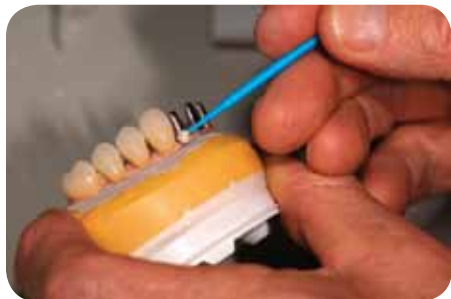

FIGURE 28A.

FIGURES 28A-B. The metal-ceramic crowns were cemented to the titanium framework (GC Fuji PLUS CAPSULE, Alpha Bond Dental).

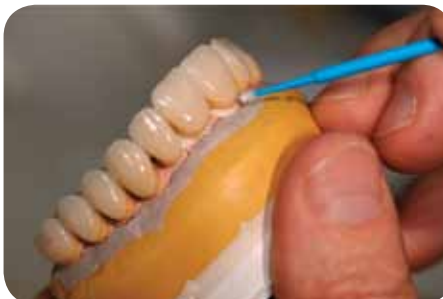

FIGURE 28B.

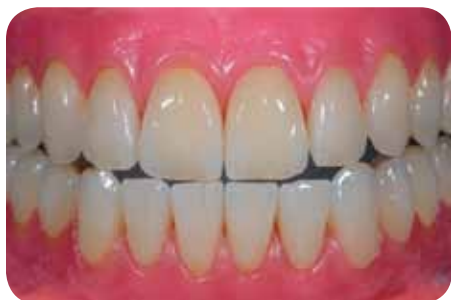

FIGURE 29. Following cementation, the gum area was replaced with paraffin wax while taking the final morphology into consideration.

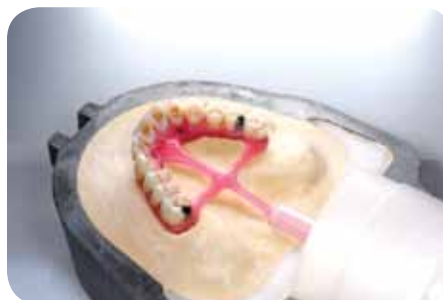

FIGURE 30. The wax gum was replaced with a gum-colored resin (Ivoclar Vivadent).

verified for fit on each abutment tooth. Then, opaque porcelain was applied to each metal coping and baked, followed by replacement on each abutment tooth. A sufficient space for porcelain build-up was maintained¹⁴⁻¹⁶ (FIGURES 19A-B).

The titanium framework was tried in the mouth. At this time, the guide temporary crowns fabricated as the FTP model was placed in the mouth to check the balance with the lips (FIGURES 20A-B).

Porcelain (Noritake Super Porcelain EX-3, Alpha Bond Dental) should be built up with the prefabricated silicone core to avoid deviation with the guide temporary crowns (FIGURES 21A-D).

Following baking of the porcelain, the entire balance of the metal-ceramic crowns was verified on the titanium framework for contouring. During porcelain build-up, use of the guide temporary crowns and silicone core allowed smooth and easy contouring work that could be completed in a short time¹⁶ (FIGURES 22A-B).

Contouring was performed on the model (FIGURES 23A-B). The porcelain work fabricated by duplication of the guide temporary crowns should have little deviation even in the mouth (FIGURES 24A-C). Biscuit-bake try-in can considerably reduce chairtime considerably, resulting in a reduction of burden on the patient (FIGURES 25A-E).

Glazing on the model was completed.^{1,9,17} The positional relationships of all contact points was verified (FIGURES 26A-C).

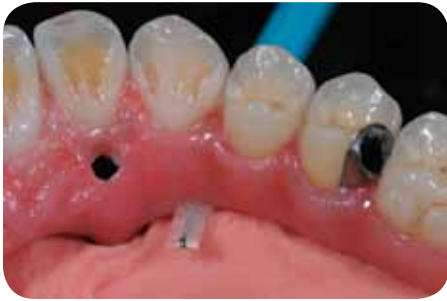

FIGURE 31A. The gum area must be replaced with a resin material while ensuring adequate cleaning ability between the edentulous interproximal area and the gum area replaced with a resin. After completion, it is necessary to check that there is an adequate cleaning space with an interdental brush on the model.

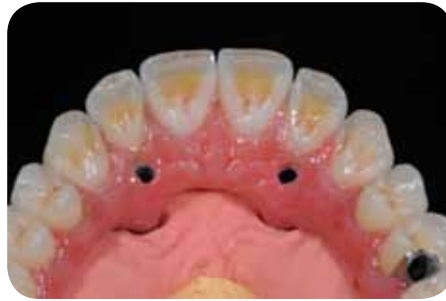

FIGURE 31B. Lingual view. Creation of the accurate anatomical morphology allowed recovery of patient's masticatory and pronunciation functions. In addition, if the access hole is located on the porcelain crown, the external wall of the access hole should be covered with metal to avoid fracture in the mouth. In the maxilla, this metal cover has no esthetic affect.

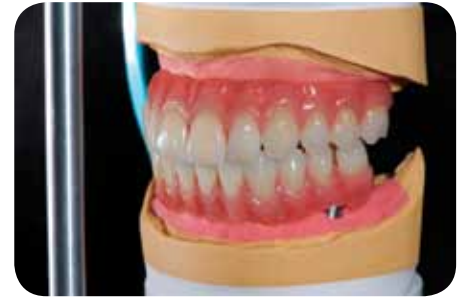

FIGURE 31C. Final check on the articulator.

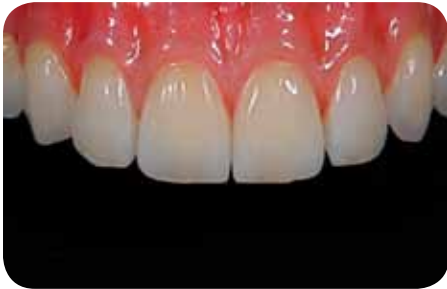

FIGURE 32A.

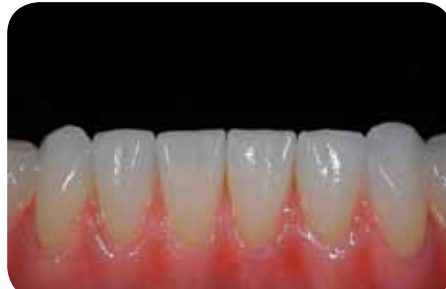

FIGURE 32B.

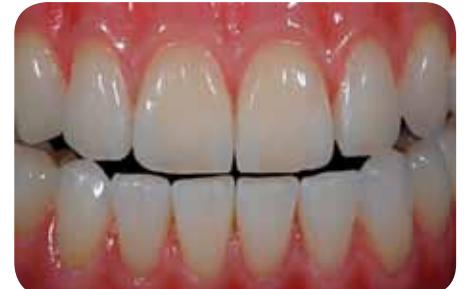

FIGURE 32C. Should the patient lift up his lip, a natural-looking implant superstructure could be seen.

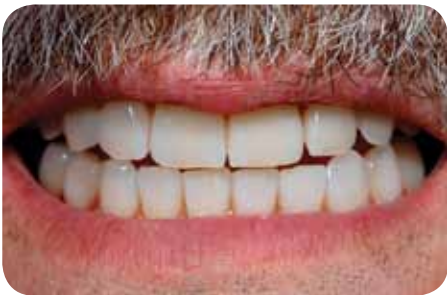

FIGURE 32D.

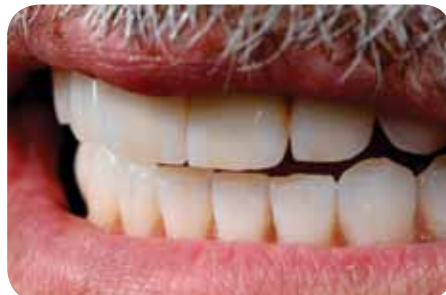

FIGURE 32E.



FIGURE 32F.

The titanium framework surface was sandblasted with alumina (Al_2O_3) to apply the pink opaque porcelain to mask the metal color of the framework in the gum area (FIGURES 27A-B).

The metal-ceramic crowns were cemented to the titanium framework (FIGURES 28A-B).

Following the final localization, the

gum area was replaced with paraffin wax. This procedure is very important as this area would be subsequently replaced with a resin^{3,4,8} (FIGURE 29).

Replacement of the gum area with a gum-color resin material (FIGURE 30) was done. In implant treatment, metal-ceramic crown fracture often results in the neces-

sity of surrounding soft-tissue repair. Replacement of the gum area with resin allows repair of the necessary site only with no damage to the surrounding area.^{11,19}

The Malo Implant Bridge was completed on the model (FIGURES 31A-C) and the final Malo Implant Bridges were placed in the mouth^{5,6} (FIGURES 32A-F).

Noritake Dental Porcelain

A large variety of Noritake dental porcelains are available, including EX-3 Press LF and CZR Press LF, in addition to the three basic types, i.e., Super Porcelain EX-3, Cerabien, and Cerabien ZR, which correspond to metal, alumina, and zirconia materials, respectively. However, even if porcelain restorations are fabricated from different materials, these products can all be used without confusion as the concepts involved in their construction are the same.

Conclusion

Recent remarkable advances in both dental care and clinical techniques have facilitated the development of many novel dental materials and treatment techniques worldwide. Dentists and dental technicians must decide which of several choices are better suited to individual cases and how they should be utilized clinically. However, this does not always have a positive impact on patients.

The most important factors for successful implant treatment are careful treatment planning and communication between dentists, dental technicians, and patients. Finally, as the patient bears the financial

burden and is the final judge of the quality of the prosthesis, the patient's opinions and desires cannot be disregarded.

The clinical laboratory procedures described here can reduce the times required for both laboratory work and at the chairside if satisfactory temporary restorations can be fabricated before the final prosthesis. The author hopes the Malo Implant Bridge based on the All-on-4 concept described here can be of service in your daily clinical practice. ■■■■

REFERENCES

1. Bengé L, Young R, An alternative technique for value management of densely sintered alumina based restoration, in Sadan A, ed, Chicago, *Quintessence Publishing*, 2001.
2. Magne P, Belsur U, Bonded porcelain restorations in the anterior dentition, Chicago, *Quintessence Publishing*, 2002.
3. Ubassy G, Analysis, the new way in dental communication. Teamwork Media Stl, Valla Carcinal Therapy.
4. Ubassy G, Shape and color — the key to successful ceramic restoration, Chicago, *Quintessence Publishing*, 1992.
5. Gutierrez Rier JJ, Flores AR, et al, Endosseous implant rehabilitation of edentulism using high-strength ceramics and component prosthesis design, Chicago, *Quintessence Publishing*, 2010.
6. Sieber C, Motivation, Bad Sckingen, VITA Zahnfabrik, 2005.
7. McLaren EA, Chang Y, The 3-D communication of shade: visual shade taking and the use of computerized shade - taking technology. *Inside Dent* 2(1):2-3, 2006.
8. Chu SJ, Devigus A, Mielezsko A, Fundamentals of color, Chicago, *Quintessence Publishing*, 2004.
9. Blatz MB, Sadan A, Kern M, Adhesive cementation of high-

- strength ceramic restorations. Clinical and laboratory guidelines, *Quintessence Dental Technology*, pages 47-53, 2003.
10. Galip G, The science and porcelain laminate veneers, *Quintessence Publishing*, 2004.
11. Coachman C, Van Dooren E, et al, Minimally invasive reconstruction in implant therapy the prosthetic gingival restoration, Chicago, *Quintessence Publishing*, 2010.
12. Wohrle PS, Cornell DF, Contemporary maxillary implant-supported full-arch restoration combining esthetics and passive fit, Chicago, *Quintessence Publishing*, 2008.
13. Yoshida A, All ceramic restorations: material selection and opacity control for esthetically superior result, *Quintessence Publishing* 30:87-100, 2007.
14. Yamamoto M, The metal ceramics. *Tokyo Quintessence Publishing*, 1982.
15. Ban K, Q&A ceram metal. Tokyo Ishiyaku Publishing, 1989.
16. Aoshima H, Ceramic example. *Tokyo Quintessence Publishing*, 1991.
17. Hayashi N, A diary through the lens. *Tokyo Quintessence Publishing*, 2005.
18. Malo P, Rangert B, Nobre M, All-on-4 immediate-function concept with Branemark system implants for completely edentulous mandibles: a retrospective clinical study, *Blackwell Publishing Inc.*, 2003.
19. Coachman C, Salama M, et al, Prosthetic gingival reconstruction in the fixed partial restoration, part 3. *Int J Periodontics restorative Dent* 30:19-29, 2010.

TO REQUEST A PRINTED COPY OF THIS ARTICLE, PLEASE CONTACT
Taishi Kodama, RDT, Omega Ceramics Dental Laboratory Pty Ltd., 5 Bond St. South Yarra, Victoria 3141, Australia.

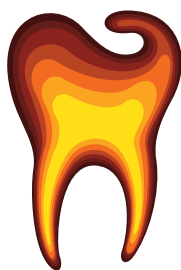

Because Your Mouth Says It All

Associate required in Alberta:

Take advantage of Alberta's economy and be part of an organization you can be proud of. Dental Choice helps to keep your career and financial goals on track. We offer ownership opportunities and a recognizable brand patients can trust. Opportunities available in Calgary and Edmonton.

FOR FURTHER DETAILS, PLEASE EMAIL US AT
info@dentalchoice.ca



Esthetic Considerations for the Treatment of the Edentulous Maxilla Based on Current Informatic Alternatives: A Case Report

MARIO H. RODRÍGUEZ-TIZCAREÑO, DDS; LIZBETH BARAJAS, DDS; MARISOL PÉREZ-GÁSQUE, DDS; AND SALVADOR GÓMEZ

ABSTRACT This report presents a protocol used to transfer the virtual treatment plan data to the surgical and prosthetic reality and its clinical application, bone site augmentation with computer-custom milled bovine bone graft blocks to their ideal architecture form, implant insertion based on image-guided stent fabrication, and the restorative manufacturing process through computed tomography-based software programs and navigation systems and the computer-aided design and manufacturing techniques for the treatment of the edentulous maxilla.

AUTHORS

Mario H. Rodríguez-Tizcareño, DDS, is coordinator and associate professor, Implant Department, Postgraduate and Research Division, Facultad de Odontología, Universidad Nacional Autónoma de México.
Conflict of Interest Disclosure: None reported.

Lizbeth Barajas, DDS, is an associate, Implant Department, Postgraduate and Research Division, Facultad de Odontología, Universidad Nacional Autónoma de México.
Conflict of Interest Disclosure: None reported.

Marisol Pérez-Gásque, DDS, is an associate professor, Implant Department, Postgraduate and Research Division, Facultad de Odontología, Universidad Nacional Autónoma de México.
Conflict of Interest Disclosure: None reported.

Salvador Gómez, is a guest professor, Implant Department, Postgraduate and Research Division, Facultad de Odontología, Universidad Nacional Autónoma de México.
Conflict of Interest Disclosure: None reported.

Creating a healthy and pleasing gingival and dental architecture combined with a facial esthetic results are the key components to achieve the complex implant prosthetic reconstruction challenge of the maxilla. The treatment planning represents the goal of a rational diagnostic phase in which the clinician establishes the treatment needs. The increased use of computer technology and the advent of high-resolution 3-D digital imaging have increased the accuracy and the ability to transfer the computed virtual treatment plan data to the surgical and prosthetic reality that marks a significant advancement in implant dentistry, leading to the development of new surgical techniques and to the fabrication of predictable,

functional treatment options and esthetic restorations.^{1,2} Pre- and postgrafting prosthetic workup with interactive computed tomography (CT) graft assessment including the transferring of virtual anatomy into usable 3-D images serve to improve the diagnostic capability to establish the basic surgical and restorative requirements such as bone condition, function, phonetics, and esthetics, as well as required material properties.^{3,5}

CT-based software programs and navigation systems have been developed to assist with surgery and presurgical implant planning. With the help of reformatted CT cross-sections, implant positions can be decided virtually based on the actual bone needs in terms of quantity. On the other hand, the current technological advances

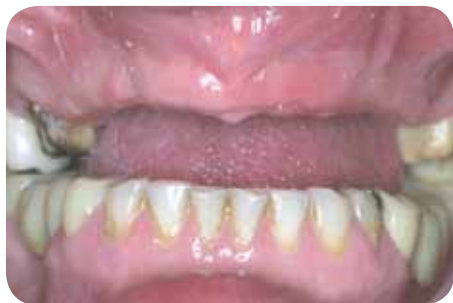

FIGURE 1A.

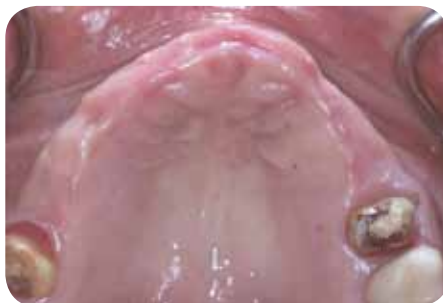

FIGURE 1B.

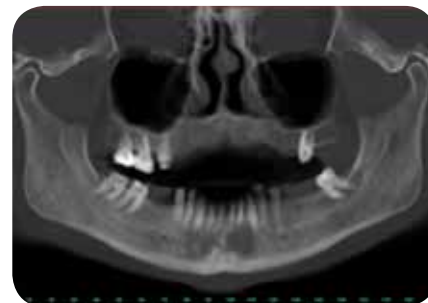


FIGURE 1C.

FIGURES 1A-C. The preliminary examination and the panoramic X-ray revealed in the maxilla severe residual resorption in the anterior region.

in computer-assisted designing (CAD) and computer-assisted manufacturing (CAM) offer a simplified approach that promotes unparalleled consistency and accuracy when they are used in combination with state-of-the-art specific treatment planning and milling tools.^{5,6} This approach includes the option of interacting with virtual anatomy in a virtual environment that offers a predictable and accurate lecture on the bone conditions, as well as the possibility of importing and drawing objects that will lead to the design. It also will drive the CAM process of custom bone graft blocks in order to restore the reabsorbed bone and to place the implants in the ideal positions, enabling the fabrication of the surgical stents that will guide the insertion procedure of the fixtures. The advantages of custom-made bone graft blocks are the close adaptation they have to the surgical site and the availability of considerable amounts of grafting material, eliminating a second surgical site since the graft doesn't have to be harvested from the patient.⁶⁷

The purpose of this report is to present a protocol used to transfer the virtual treatment plan data to the surgical and prosthetic reality and its clinical application, bone site augmentation with computer custom-milled bovine bone graft blocks to their ideal architecture form and its histological structure prior to implant placement, implant insertion based on image-guided stent fabrication, and the parallel milling manufacturing of the final prosthesis using CT-based software programs and the CAD/CAM innovative techniques currently available for the treatment of the edentulous maxilla.

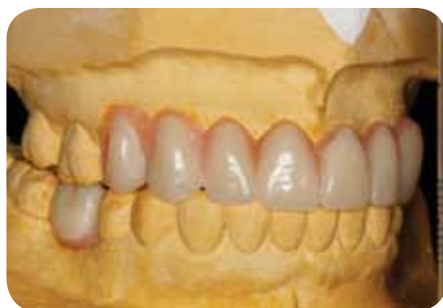

FIGURE 2A.

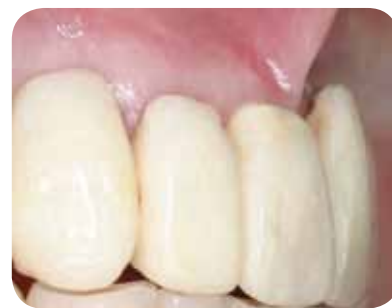

FIGURE 2B.

FIGURES 2A-B. Initial set of dental casts and clinical trial of the duplicate of the diagnostic set up to establish the rate of tooth display, lip support, speech and to establish the amount of tissue requirements to develop adequate emergency profiles.

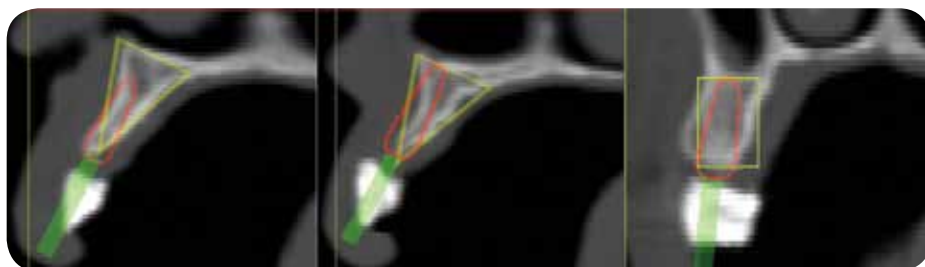


FIGURE 3. Simulation of the implant placement to visualize the amount of bone required to place the implants in the ideal position and inclination.

Case Presentation

Diagnosis and Treatment Plan Design

A healthy female 58-year-old patient, with noncontributory medical history, presented with a partially edentulous condition and maxilla collapse to the clinic of the Implant Department of the Universidad Nacional Autónoma de México. The patient reported difficulties in using her maxillary removable partial denture and was exploring the option of a fixed maxillary prosthesis. A clinical examination and radiographic assess-

ment were conducted. The preliminary examination revealed in the maxilla, severe residual resorption in the anterior region, and severe periodontal disease of Nos. 18, 19, and 31, for which they were planned for extraction (**FIGURES 1A-C**).

Working patterns casts were obtained and mounted in a semiadjustable articulator. A tooth mask was made to establish in the patient, the rate of tooth display, lip support and speech to obtain patient approval of esthetics (**FIGURES 2A-B**). After the esthetic and functional stent try-in, the patient was referred for a CT scan,

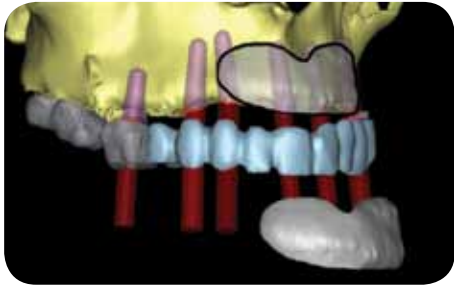


FIGURE 4. Design of the bone block that will reconstruct the missing bone.

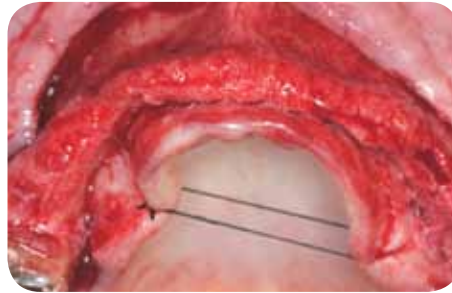

FIGURE 5. Occlusal View of the surgical site.

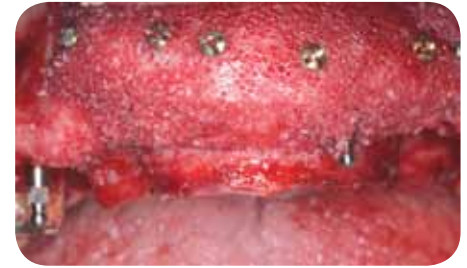

FIGURE 6. Fixation of the bovine bone graft block to the surgical site of the residual ridge with titanium bone screws.

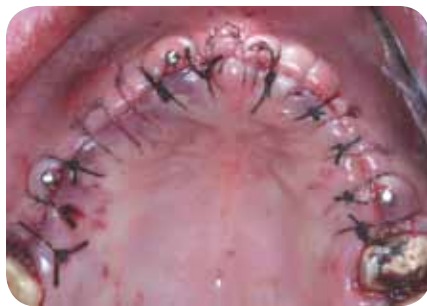

FIGURE 7. Occlusal view of the horizontal mattress sutures.

scanned with the tooth set-up in situ in order to visualize the bone condition and its relation between the actual bone dimensions and the proposed prosthetic dental contours. Pregrafting work-up with interactive CT graft assessment was performed by transferring virtual anatomy into usable 3-D images using an implant-planning software program (Mimics, Matherialise, Leuven, Belgium). Simulation of the implant placement surgery was performed to establish the amount of bone required to place the implants in the ideal position and inclination to assure the correct relation between the vestibular bone contours, the position of the implant, and the emergence profile of the restorations (**FIGURE 3**).

After discussion of different treatment options, such as conventional and implant-supported fixed or removable prosthesis, the patient consented to have an onlay bone graft in her anterior maxilla, placement of endosseous implants in the maxilla, and a fixed prosthesis. Since the bone conditions were not favorable to develop natural and esthetic emergency profiles for a fixed prosthesis, a large quantity of graft-

ing material was required to reconstruct the surgical site to place implants. Extraoral bone sites to harvest large quantities of graft such as iliac crest and calvarium bone were considered to obtain such amounts. The patient rejected this option and custom-made computed milled bone blocks that would provide the necessary amount of graft were considered to avoid an additional surgical extraoral site and the need of hospitalization of the patient.

To fabricate the computed milled custom bone graft blocks, the shape of the missing bone was traced in the third imaging software. Thereafter, the block-shaped image was refined to be milled into its final shape from a bovine bone block (**FIGURE 4**). A delayed implant placement was selected and a two-stage approach was scheduled. In a first instance, a grafting surgery was selected to restore the bone volume and, second, placing eight osseointegrated root form implants to support four screw-retained porcelain-zirconium fixed partial prosthesis distributed from the central incisor to canine and from first premolar to first molar bilaterally.

Surgical Grafting Procedure

Prophylactic antibiotic therapy (amoxicillin + clavulanic acid 125 mg) was prescribed one hour prior to surgery. The grafting surgical procedure was performed under local infiltrative anesthesia with mepivacaine chlorhydrate with epinephrine 1:100,000. The procedure was initiated with an intraoral crestal incision. A full-thickness mucoperiosteal flap was raised at the ridge crest with bilateral relieving

incisions on the buccal aspect at the second molar area (**FIGURE 5**). After the bone was completely exposed, the surgical site was extensively perforated to promote bleeding of the surgical site to provide a vascular source for the grafting material. After a hydration period of 45 minutes, the bovine bone graft block was adapted to the surgical site of the bone ridge with six titanium 1.5 x 9 mm bone screws (Biomet, Jacksonville, Fla.) (**FIGURE 6**). At this point, three mini-implants (MDI Imtec 3M, Minneapolis, Minn.) were inserted and fixed in the pre-existing residual ridge far from the surgical site to prevent micromovement of the graft to retain a provisional restoration until the graft integration, avoiding potential pressure over it. After the fixation of the graft and the insertion of the transitional implants, the voids between the block and the top of the bone ridge were filled with freeze-dried demineralized bone, 1.0 cc particulate 250-1,000 μm (Allos, ACE Surgical Supply, Brockton, Mass.) and covered by the application of a resorbable calcium phosphate barrier (CaSO_4 , ACE Surgical Supply).

Finally, the flaps were repositioned and horizontal mattress sutures were used to stabilize the flap in an optimal position without tension (**FIGURE 7**). The patient was instructed in all the postoperative indications, including a soft diet for four weeks postsurgery and hygiene. Postoperative prophylactic antibiotherapy (amoxicillin + clavulanic acid 125 mg) two times a day for seven days was prescribed, as was postoperative analgesics (Ketorolac tromethamine 10 mg) four times a day for the next three days, as needed.

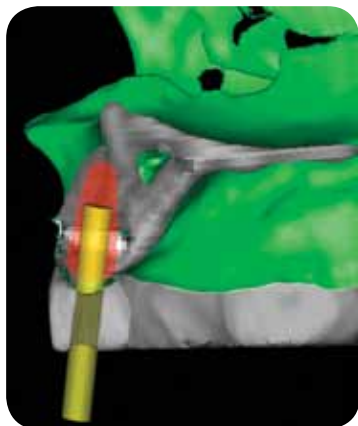


FIGURE 8. Design and refining of the surgical stent in the 3-D imaging software.

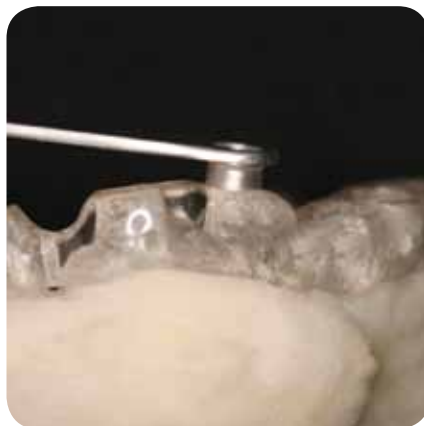

FIGURE 9. Surgical stent fabricated from an epoxy resin block.

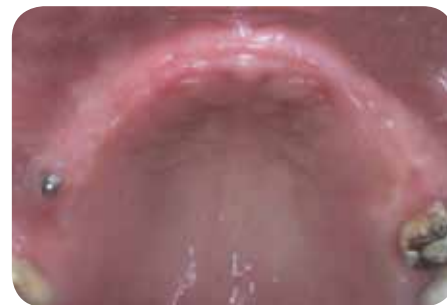

FIGURE 10. Presurgical occlusal view, in which can be appreciated an improved volume of the residual ridge.

Surgical Implant Insertion Procedure

After an eight-month period of integration of the graft, a new set of dental casts were obtained and mounted in a semiadjustable articulator. The initial set-up was adapted to the new clinical condition to evaluate again the rate of tooth display, lip support, and speech. A new CT scan was taken in order to visualize the actual bone dimensions and the relation with the proposed prosthetic dental contours. Using a 3-D imaging software simulation of the implant placement, surgery in the prototype was performed to visualize the relationship between the new vestibular bone contours and the position of the implants. With respect to emergency profile of the restorations, the implant diameter/length, position, and inclination was determined. Based on this data, the surgical stent was traced and refined in the 3-D imaging software (**FIGURE 8**). Finally, the stent was milled into its final shape from an epoxy resin block. The stent design included perforations that permit the locking of interchangeable custom-made metal cylinder guides that correspond to the diameter of each of the preparing drills to guide the drilling process (**FIGURE 9**).

Following the review of all the planning elements, the surgery was scheduled. The procedure was performed under local anesthesia with mepivacaine chlorhydrate with epinephrine 1:100,000. Antibiotics (amoxicillin + clavulanic acid 125 mg) were given one hour prior to surgery and daily for six days

thereafter. A mucoperiosteal flap was raised at the ridge crest with bilateral relieving incisions on the buccal aspect at the second molar area. The clinical findings showed preoperatively a large amount of new bone (**FIGURE 10**). After the flap raising, a stretch contact between the bovine graft and completely integrated to the pre-existing vital bone (**FIGURE 11**), the screws used for the fixation of the graft were removed and the surgical template was inserted and fixed to the bone by four 1.5 x 9 mm bone screws (Biomet) to achieve stability and to assure the direction of the osteotomies that were established and traced in the planning software during the virtual surgical procedure of the treatment planning. The implant sites were sequentially enlarged with a pilot and spiral drills, according to the standard surgical protocol. Based on the drilling sequence, surgical guides were designed as a series with steel cylinders in graduated diameters to accommodate the specified diameter of each drill to avoid errors in the direction during the preparation of the implant sites (**FIGURE 12**).

The positions selected to insert the implants were on the central, canine, premolar, and the first molar region bilaterally. Following this, eight Standard 4.1 mm x 12 mm implants (SLActive, RN. Straumann, Basel, Switzerland) were placed according to the manufacturer's instructions (**FIGURE 13**). The healing caps were placed and a one-stage approach was employed. The flaps were repositioned and horizontal mattress

sutures were used to achieve tension-free closure. The patient was instructed in all the postoperative indications, including a soft diet for one week postsurgery and hygiene. Postoperatively, prophylactic antibiotherapy (amoxicillin + clavulanic acid 125 mg) two times a day for seven days was prescribed as well as postoperative analgesics (Ketorolac tromethamine 10 mg) four times a day for the next three days, as needed.

The patient wore a complete denture during the six-month implant integration period.

Restorative Procedure

After six months of integration (**FIGURE 14**), the restorative procedures were performed. Healing abutments were removed and a preliminary impression was made to fabricate provisional restorations over provisional-milled abutments to conform the soft tissues. After insertion of the provisional restoration and soft-tissue conformation for eight weeks, final impressions were made. The transfer copings were connected to the implants and connected with a pattern resin. A custom tray was used to make the final open tray impression with vinyl polysiloxane-based impression materials. Master casts were fabricated and trimmed, and a verification jig was made to assure the accuracy for the impression. Record bases and occlusion rims were made as well. The patient returned to the impression verification; face bow transfer, and recording of maxillomandibular relations. Master casts were then mounted

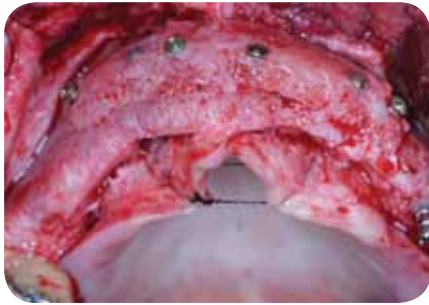

FIGURE 11. Frontal view in which it is apparent the stretch contact between the residual bone and the bovine block graft completely integrated to the pre-existing bone.

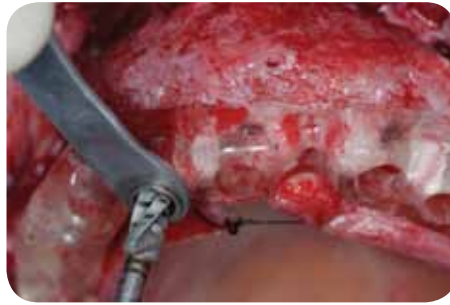

FIGURE 12. The stent design include perforations that permit the locking of interchangeable custom-made metal cylinder guides that correspond to the diameter of each of the preparing drills to guide the drilling process.

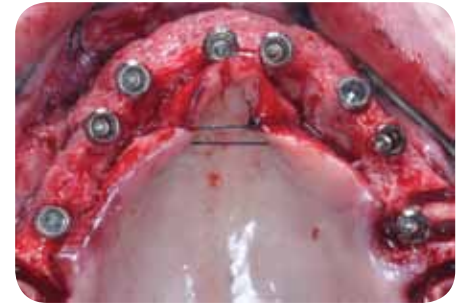

FIGURE 13. The positions selected to insert the implants were on the central, canine, premolar, and the first molar region bilaterally.

in a semiadjustable articulator. Screw-retained abutments (Synocta, Straumann, Basel, Switzerland) were connected to the implant analogs. Four screw-retained, porcelain-zirconium, fixed partial dentures were planned. The fixed partial dentures were distributed from central incisor to canine and from first premolar to first molar bilaterally.

Frameworks were waxed and replicated in a resin pattern, and then reproduced with a zirconia parallel milling system (Zirkonzahn Bolzano, Italy). In the case of the anterior sections, transversal screw retention was employed, and, in the posterior sections, conventional occlusal access screw-retained prosthesis. The stability and marginal fit of the framework were verified clinically and a porcelain shade was selected and approved by the patient. The frameworks were returned to the laboratory for the application of the porcelain. A clinical trial of occlusion and a porcelain shade was performed to allow final verification of fit, esthetics, and refinement of occlusal contacts. The porcelain was glazed, and the fixed prosthesis was screwed and torqued. The screw access was sealed with gutta-percha and a nanoparticle photopolymerized composite, (Filtek Supreme, 3M). Occlusal adjustments were made and an occlusal stent was prescribed. Oral hygiene instructions and techniques were reviewed, particularly in relation to home care of the fixed restorations. The patient was scheduled for follow-up and oral prophylaxis every three months.

Discussion

The treatment of the edentulous maxilla is one of the most challenging tasks in implant dentistry, caused by functional and esthetic implications, such as the loss of chewing efficiency and the loss of facial support that are closely related with the absence of dental structures that accelerate the aging process.^{8,9} Since the reconstruction of the edentulous maxilla must be esthetically and functionally driven, it's very important to identify the treatment considerations along with the technical resources to be employed. A fixed rehabilitation of the maxilla requires a protocol in which implants are virtually positioned according to the prosthetic requirements and not only by the bone condition available in the region.^{9,10} This approach requires an appropriate bone volume to sustain the implant and consequently provide support of the soft tissues, which is essential to achieve a pleasing prosthetic outcome. The loss of the anatomical reference structures complicates even more the data transferring that is fundamental to recreate the previous position of the teeth and their supporting structures. The selection and position of the implants must be defined by the restorative needs that can be established by a diagnostic wax-up that will guide the planning, surgical, and restorative process.^{9,11-13}

Visualization of CT scan images are supported on computer software packages that allow for 3-D viewing and interacting

using CAD technology. For an accurate visualization of the residual bone, which impacts directly over the implant position, angulation, and length, a CT scan with a radiographic reference template that reproduces the contours of the planned restorations is necessary. The CT scan shows the relation between the radiographic template with respect to the quantity and angulation of the residual bone^{9,14} (FIGURE 15).

The use of computer-assisted designing (CAD) and computer-assisted manufacturing (CAM) technology is a very useful tool when based on an accurate diagnosis. The CAD process is based in the precision of the 3-D processing software that leads the design of the grafts, the surgical stent, and drives the CAM process based on effective milling resources. The software offers as well the advantage of the visualization and the ability to evaluate bone density, and gives the option of tracing virtual structures and position implants according to the needs of the restoration. This assists the surgeon in foreseeing positioning and size of implants prior to surgery.¹⁵⁻¹⁷

By applying image-matching techniques, the original CT data of the patient is fused to the corresponding clinical condition (FIGURE 16). After visualization of CT scan images, the implants are placed in the ideal positions with respect to the virtual restoration. The bovine bone blocks are traced and designed according to the bone needs in terms of quantity and angulations.

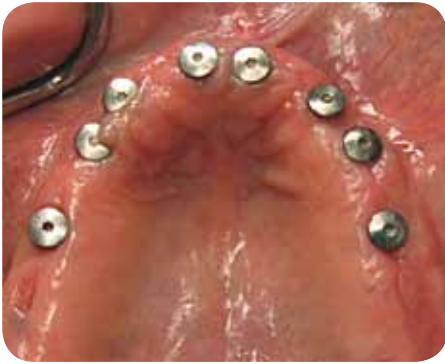

FIGURE 14. Occlusal view, after the six months of integration.

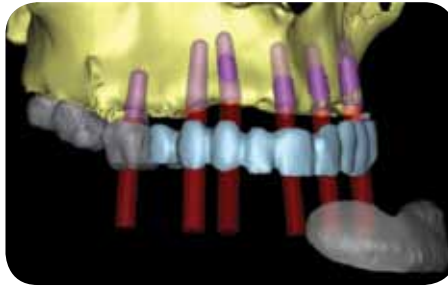


FIGURE 15. CT scan of 3-D reconstruction with the ideal positions to establish the amount of bone required to place the implants.

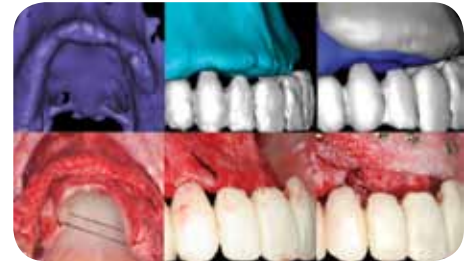

FIGURE 16. Comparison between the 3-D views of the CT scan and the clinical reality.

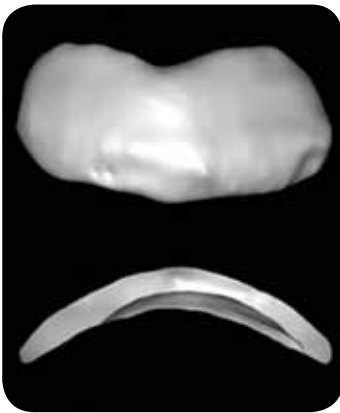

FIGURE 17A.

FIGURES 17A-B. Design and adaptation of the bovine bone block, saved in an .stl extension file to be milled in the router.

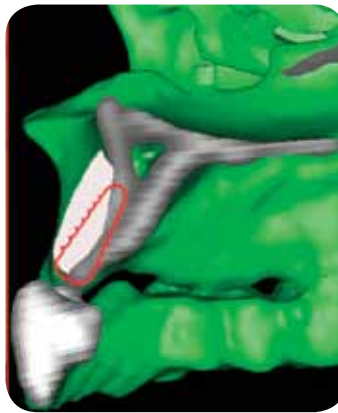

FIGURE 17B.

Finally, the adaptation is checked virtually and saved to be exported in a “.stl” extension file to the computed numeric control software of the milling router (**FIGURES 17A-B**). The router is a three-axis milling element that works in a “xyz” environment. Before starting, the milling element traces an origin point that corresponds to the intersection of the x, y, and z axes, runs the trajectories and the paths into the block of material that will be milled up to its final shape (**FIGURES 18A-D**). The use of the same router axis for planning surgery and designing the graft blocks and the surgical stent prevent errors that could occur when the data have to be interpreted or scanned.^{5,17-19}

Using 3-D imaging software, the implants were virtually positioned and, based on this data, the surgical stent was traced and milled into its final shape from an epoxy resin block with the same principle

of the bone blocks (**FIGURE 19**). It's very important to consider there may also be some limitations that could distort the planned position of the implants because CT scanners often are unable to recognize structural differences smaller than 1 mm.^{20,21} Furthermore, the adaptation to the bone crest may be altered by some factors such as the presence of pseudobone tissue that is flexible and can distort the stent stabilization. Although these advanced methods aim at improving surgical guidance, accuracy has rarely been measured objectively.^{6,22} Planning and actual placement is related more closely in terms of horizontal positioning (mesiodistal and buccolingual) and implant angulation. A series of studies by Schicho, evaluating the accuracy of a registration method used for the planning transfer, revealed mathematical mean discrepancies between the models made from the imag-

ing software and the clinical reality from 0.8 percent to 5.4 percent, with an overall mean deviation of 2.2 percent, which makes this option a suitable and sufficiently reliable method for surgical planning.²³

With regard to the desired bone volume, the grafted bone is obtained by regenerating bone tissue from custom-made bovine bone matrix blocks. There is clinical evidence the maximum obtainable increase in bone height through bone regeneration using barrier membranes without additional measures is limited to approximately 4 mm.^{18,24,25} This limit may be explained by the fact that the pluripotent osteoprogenitor cells that invade the empty space under the membrane and fill it with bone tissue must become attached to the surface of a matrix analogous to the marrow space with a pore size close to that of natural bone before they may proliferate and reach the final step of differentiation to bone-producing osteoblasts.²⁶⁻²⁸ The use of a scaffold seems to be necessary to enable regenerating bone tissue to occupy larger volumes, thus allowing for the fabrication of prefabricated bone grafts. The development of resorbable tricalcium phosphate materials with an interconnecting porous structure should improve the potential of bone proliferation²⁹ (**FIGURE 20**). The bone block graft is made of osseous bone matrix from bovine origin. The matrix is made of hidroxyapatite nanometric crystals deposited over type I collagen.

Clinical findings were very interesting. It was noted a close adaptation of the block to the vital bone and the bleeding pattern showed a good integration, and

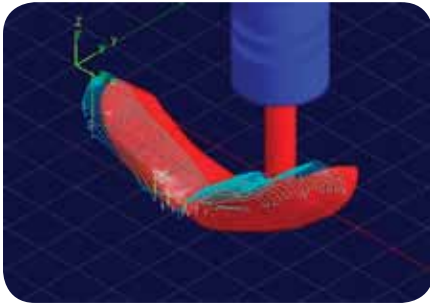


FIGURE 18A.

FIGURES 18A-D. Milling process of the bovine bone block.



FIGURE 18B.

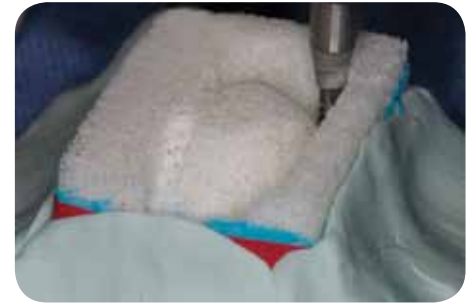

FIGURE 18C.

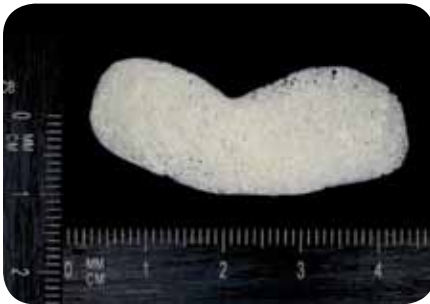

FIGURE 18D.




FIGURE 19. Milling process of the surgical stent.

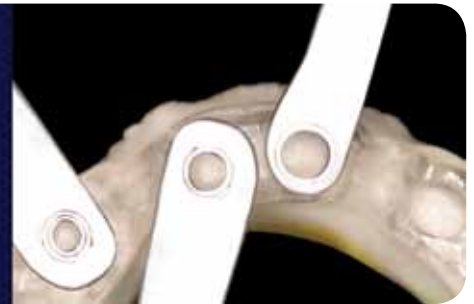


FIGURE 20. Porous structure of the bovine bone block compared with the residual crestal bone.

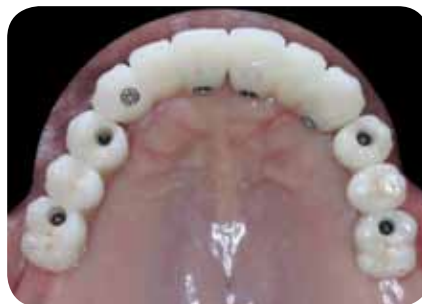

FIGURE 21A.

FIGURES 21A-B. Occlusal and front views of the final restorations.

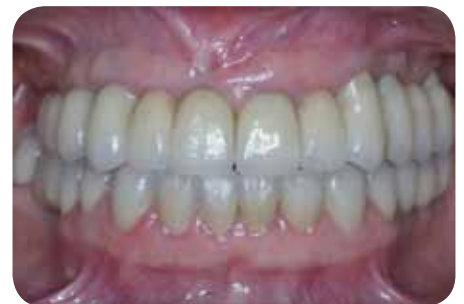

FIGURE 21B.

the CT scan revealed a close adaptation with no soft tissue between the graft and the vital bone. The densitometry measures made with the planning software revealed an average 340 Hounsfield units in the block area that correspond to a type 4 bone.⁴ Bovine bone matrix (BBM) is a natural deproteinized inorganic bone mineral with a high degree of biocompatibility.^{30,31} The material is reportedly resorbable and is structurally very similar to cancellous bone. This explains the early and consistent bone apposition observed in areas augmented with this material. As BBM undergoes slow remodeling

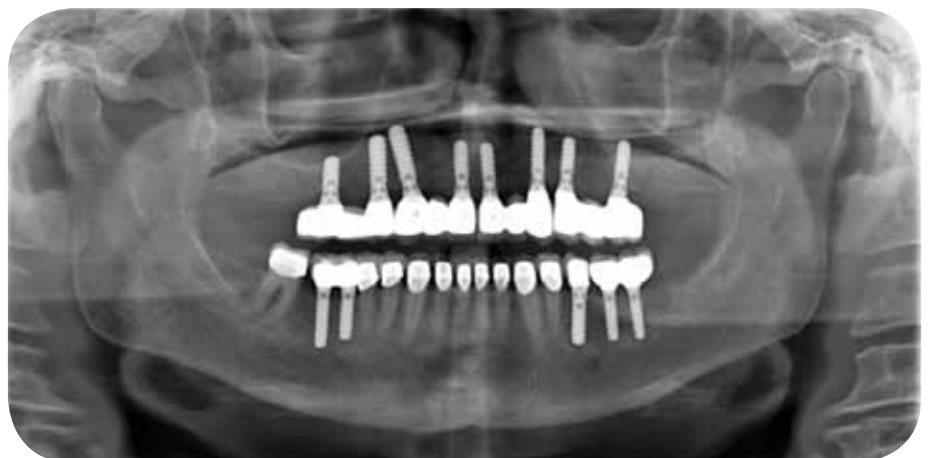

FIGURE 22. Final panoramic X-ray.

over time and becomes incorporated into the pre-existing bone, it maintains its volume over a long period of time, which offers stability of the bone height in the augmented site until the implants are functionally loaded and physiologic remodeling takes place.³²⁻³⁴ Particularly, a custom-made bone block offers the advantage of the close adaptation of the graft and the surgical bed, avoiding the need of chairside adaptation of the graft, reducing the possibility of contamination and proliferation of soft tissue between the graft and the autologous bone bed.^{10,18,35}

Detailed presurgical planning minimized potential difficulties during the prosthetic procedure. The prosthetic manufacturing process was based in a zirconium parallel milling system (Zirkonzahn Bolzano, Italy). In the anterior region, two fixed partial prosthesis from central incisor to canine with the lateral incisor as a pontic; in the posterior region, two fixed partial prosthesis from first premolar to first molar with second premolar as a pontic. A mutually protected occlusion scheme up to the first molar was developed with a flat anatomy. The literature reports that posterior cusp inclination produces maximum torque over the implant-bone interface and therefore should be substantially reduced.^{11,12,15,36}

Due to the magnitude and extension of the restoration, it was considered a retention option that could offer retrievability in case of complications that could require the removal of the prosthesis. The practice of permanently cementing implant-based prostheses may conflict with the likelihood of biologic and technical failure. For that reason, a screw-retained restoration was preferred, a transverse screw retention system was employed in the anterior zone (Synocta Transversal. Straumann, Basel, Switzerland)³⁷ (FIGURES 21A-B, 22).

Conclusion

When dealing with complex dental implant cases, exhaustive and rational preoperative treatment planning and interdisciplinary coordination are necessary for successful treatment outcomes. Presently, traditional diagnostic auxiliaries, such as conventional imaging tools and diagnostic wax-up, are not sufficient to design a realistic and accurate treatment plan. A CT-based 3-D imaging processing software, and the current technological advances in CAD-CAM, along with a good understanding of anatomy and surgical principles are the key components to promote the development of esthetic and functional restorations. The current available technology, combined with an accurate and deep understanding of the biological aspects of the tissues are fundamental to establish an ideal treatment sequence that includes the design and fabrication of grafting bone blocks to restore the lost bone and the ideal osseous profiles, the implant insertion based on image-guided stent fabrication, and the parallel milling manufacturing of the final restoration.

For these challenging tasks, the establishment of a consistent protocol that guarantees the transfer of the virtual treatment plan to the actual clinical reality is mandatory and is the key component to assure the reconstruction of osseous and gingival profiles that will promote the development of a natural dental anatomy to re-establish a pleasing and esthetic dental environment for the restoration of the edentulous maxilla. ■■■■

REFERENCES

1. Tood AD, Gher ME, et al, Interpretation of linear and computed tomograms in the assessment of implant recipient sites. *J Periodontol* 64:1243-8, 1993.
2. Tyndall AA, Brooks SL, Selection criteria for dental implant site imaging: a position paper of the American academy of oral and maxillofacial radiology. *Oral Surg Oral Med Oral Path Oral Radiol Endod* 89:630-7, 2000.
3. Schwarz MS, Rothman SLG, Rhodes ML, Computed tomography. Part II: preoperative assessment of the maxilla for endosseous implant surgery. *Int J Oral Maxillofac Implants* 2:143-8, 1987.

4. Norton MF, Gamble C, Bone classification: An objective scale of bone density using the computerized tomography scan. *Clin Oral Implants Res* 12:79-84, 2000.
5. Duret F, Blouin JL, Duret B, CAD/CAM in dentistry. *JADA* vol. 117, pages 715-20, November 1988.
6. Terzioglu H, Akkaya M, Ozan O, The use of a computerized tomography-based software program with a flapless surgical technique in implant dentistry: a case report. *Int Journal Oral Maxillofac Implants* 24:137-42, 2009.
7. Chiu W, Luk W, Cheung L, Three-dimensional accuracy of implant placement in a computer-assisted navigation system. *Int J Oral Maxillofac Implants* 21:465-70, 2006.
8. Rodríguez M, Procedimientos de diagnóstico y planificación del tratamiento estéticamente orientado, in: Rodríguez M, Fundamentos estéticos para la rehabilitación de implantes oseointegrados. Sao Paulo, Editora Artes Médicas Ltda, pages 21-48, 2006.
9. Sierra L, Rodríguez M, Metodología para la inserción de implantes dentales, in: Rodríguez M, Fundamentos estéticos para la rehabilitación de implantes oseointegrados. Sao Paulo, Editora Artes Médicas Ltda, pages 49-82, 2006.
10. Díaz H, Rodríguez M, Métodos y técnicas para el aumento de volumen de tejido óseo, in: Fundamentos estéticos para la rehabilitación de implantes oseointegrados. Sao Paulo, Editora Artes Médicas Ltda, pages 49-82, 2006.
11. Rodríguez M, Manejo protésico de tejidos blandos, in: Rodríguez M, Fundamentos Estéticos para la Rehabilitación de Implantes Oseointegrados. Sao Paulo, Editora Artes Médicas Ltda 179-202, 2006.
12. Bidez MW, Misch CE, Clinical biomechanics in implant dentistry in: Mish CE, Contemporary implant dentistry, second ed., St. Louis, Elsevier Mosby, 1999.
13. Bashutski JD, Wang HL, Common implant esthetic complications. *Implant Dentistry*, volume 16, pages 340-7, 2007.
14. Bessimo CE, Lambrecht JT, Guindy JS, Accuracy of implant treatment planning utilizing template-guided reformatted computed tomography. *Dentomaxillofac Radiol* 29:46-51, 2000.
15. Van Dooren E, Using zirconia in esthetic implant restorations. *QDT* pages 119-28, 2007.
16. Guichet DL, Caputo AA, et al, Passivity of fit and marginal opening in screw-or cement-retained implant fixed partial denture designs. *Int Oral Maxillofac Implants* 15:239-46, 2000.
17. Brief J, Edinger D, et al, Accuracy of image-guided implantology. *Clin Oral Implants Res* 26:495-501, 2005.
18. Widmann G, Bale RJ, Accuracy in computer-aided implant surgery. A review. *Int J Oral Maxillofac Implants* 21:305-13, 2006.
19. Casap N, Wexler A, Lustmann J, Image-guided navigation system for placing dental implants. *Compend Contin Educ Dent* 25:783-94, 2004.
20. Mizuki N, et al, Implant simulation using personal computer system. Characteristics of SIM/PlantTM. *Quintessence* 16:1244-9, 1997.
21. Sarment D, Al-Shammari K, Kazar CE, Stereolithographic surgical templates for placement of dental implants in complex cases. *Int J Periodontic Restorative Dent* 23:287-95, 2003.
22. Jaber M, Sarment DP, Advanced surgical guidance technology: a review. *Implant Dent* 15:135-42, 2006.
23. Schicho K, Figl M, et al, Accuracy of treatment planning based on stereolithography in computer assisted surgery. *Med*

Phys 33(9):3408-17, September 2006.

24. Ostman PO, Hellman M, Sennerby L, Direct implant loading in edentulous maxilla using a bone density-adapted surgical protocol and primary implant stability criteria for inclusion. *Clin Implant Dent Relat Rest* 7(suppl1):S60-S69, 2005.

25. Boyne PJ, Bone grafts: materials in, Osseous reconstruction of the maxilla and the mandible:surgical techniques using titanium mesh and bone - mineral. Chicago, *Quintessence*, pages 3-11, 1997.

26. Yao Z, Lafage-Proust MH, Plovet J, Increase of both angiogenesis and bone mass in response to exercise depend on VEGF. *J Bone Res* 19:1471-80, 2004.

27. Veillette CJ, Von Schroeder HP, Endothelin-1 down-regulates the expression of vascular endothelial growth factor-A associated with osteoprogenitor proliferation and differentiation. *Bone* 34:288-96, 2004.

28. Skoglund A, Hising P, Young C, A clinical and histologic examination in humans of the osseous response to implanted natural bone mineral. *Int J Oral Maxillofac Implants* 12:194-9, 1997.

29. Murphy WL, Simmons CA, et al, Bone regeneration via mineral substrate and induced angiogenesis. *J Dent Res* 83:204-10, 2004.

30. Piattelli M, Favero GF, et al, Bone reactions to anorganic bovine bone (Bio-Oss) used in sinus augmentation procedures. A histologic long-term report of 20 cases in humans. *Int J Oral Maxillofac Implant* 14:835-40, 1999.

31. Steigman M, A bovine-bone mineral block for the treatment of severe ridge deficiencies in the anterior region: a clinical case report. *Int J Oral Maxillofac Implants* 23:123-8, 2008.

32. Barou O, Mekraldi S, et al, Relationship between bone vascularization: a quantitative study. *Bone* 30:604-12, 2002.

33. Gher ME, Quintero G, et al, Bone grafting and guided-bone regeneration for immediate dental implants in humans. *J Periodontol* 65:881-91, 1994.

34. Winet H, The role of microvasculature in normal and perturbed healings as revealed by intravital microscopy. *Bone* 19:395-575, 1996.

35. Klein M, Abrams M, Computer-guided surgery utilizing a computer-milled surgical template. *Pract Periodontics Aesthet Dent* 13:165-9, 2001.

36. Weinberg L, Reduction of implant loading via therapeutic biomechanics, in: Weinberg L, Atlas of tooth-and implant-supported prosthodontics. Chicago, *Quintessence*, 67-84, 2003.

37. Tahmaseb A, De Clerck R, Wismeijer D, Computer-guided implant placement: 3-D planning software, fixed intraoral reference points, and CAD/CAM technology. A case report. *Int J Oral Maxillofac Implants* 24:541-6, 2009.

38. Buser D, Martin W, Belser UC, Optimizing esthetics for implant restoration in the anterior maxilla. Anatomic and surgical considerations. *Int J Oral Maxillofac Implants* 19(suppl):43-61, 2004.

TO REQUEST A PRINTED COPY OF THIS ARTICLE, PLEASE CONTACT
Mario H. Rodríguez-Tizcareño, DDS, Eugenio Sue #354 PB,
Colonia Polanco, Delegación Miguel Hidalgo, CP 11550, Mexico
DF, Mexico.



WESTERN PRACTICE SALES

John M. Cahill Associates

This Month's Featured Listings

BAY AREA

A-8941 SAN FRANCISCO— Two Fully Equipped ops/plumbed for 1 add'l **Only \$65k**

BN-051 HAYWARD—Well-established, family-oriented ~1,000sf w/3 ops **\$150k**

C-8901 SANTA ROSA— 40+ new pats/mo. Highly Visible! 1291sf & 3 + 1 op. **\$468k**

D-9091 ATHERTON —Turnkey operation 969 sf & 3 ops **Call for Details!**

D-965 WATSONVILLE - ~ 2,400 sf, w/ 4 ops/plumbed for 4 add'l ops. **\$420k**

D-997 SAN JOSE -Well established, FFS practice. ~ 1,008 sf w/ 3 ops + 1 add. **\$230k**

DN-062 LOS ALTOS— ~1222 sf w/3 ops. **\$250k**

NORTHERN CALIFORNIA

EC-045 SACRAMENTO - FFS, 20+ years. 1500 sf w/4 ops. Plumbed for 1 add'l op! **\$320k**

F-1013 FORTUNA—Well respected FFS GP. . 1,000 sf w/ 3 ops **\$195k**

G-883 CHICO VICINITY— Quality FFS GP. Attractive Prof Plaza. 1,990 sf w/ 5 ops **\$495k**

G-998 CHICO/PARADISE—~898sf, 3 ops. **\$275k**

H-856 SOUTH LAKE TAHOE Over 50 new patients/mo! 1568 sf & 4 ops **\$325k**

HC-054 SIERRA FOOTHILLS— Seller Retiring. 1,800 sf w/ 5 ops **\$600k**

G-1019 WILLOWS AREA—Small Community practice! ~1,600sf w/ 2 ops. **\$185k**

GN-034 PARADISE—Central Local and great views! ~1168sf w/ 3ops. **\$210k**

GN-058 YUBA CITY— Quality dental care/patient comfort, 1,704sf w/ 4 ops **\$450k**

CENTRAL VALLEY

I-9721 STOCKTON—Prof. complex 1,450 sf w/3 ops & plumbed for 1 add'l op. **\$75k.**

I-1005 SAN JOAQUIN— High-End Restoratives. 2,500+ sf w/ 6 ops **\$650k**

IN-024 MERCED - Immaculate! Absolute jewel! ~1250sf, 3 ops + 1 add'l **\$240k**

IN-032 GREATER MERCED - Prime Location! Modern equip ~1,100 sf w/ 4 ops **\$335k**

J-1000 TULARE—Real Estate Available too! ~ 1650sf w/ 4op. **\$465k and R.E. \$249k**

J-1001 LINDSEY— All American City! ~3,380sf w/5ops. **Now Only \$264k**

SPECIALTY PRACTICES

I-7861 CTRL VLY ORTHO— 2,000sf, open bay 8 chairs. FFS. 60-70 patients/day. **\$370k**

J-983 CENTRAL VALLEY ORTHO - Attractive ~1,773sf w/ 6 chairs/bays. **\$325k**

G-975 CHICO ORTHO—Denti-Cal patient base. ~ 900 sf w/ 2 + ops . **\$90k**

EN-038 ENDO/PERIO SACRAMENTO - Spectacular! 3 ops(plumber for 2 add'l) **\$680k**

GN-050 NOR CAL PERIO - **AMAZING!** Remodeled office is ~3,500 sf w/ 5 ops. **\$1m**

8 0 0 . 6 4 1 . 4 1 7 9

w e s t e r n p r a c t i c e s a l e s . c o m

DENTIST


LAWYER

BROKER

SPECIALIZING IN DENTAL PRACTICE SALES, TRANSITIONS & VALUATIONS



A. LEE MADDOX, DDS, ESQ.



MADDOX PRACTICE GROUP



KERRI MCCULLOUGH

Now with California offices in La Jolla, Los Angeles, Newport Beach and Walnut Creek

We have been involved with more than 1000 dental practice transactions.

Here are some of our current listings:

NEW LISTING - Price TBD - General Dentistry Practice in Coastal Orange County, Southern California, with four (4) operatories, fully equipped. Great location near shopping center. Modern, beautifully appointed office with high end finishes. Must see! Call our office for more information.

NEW LISTING - \$50,000 - Dental Leasehold Improvements in Westchester, Los Angeles County, Southern California with three (3) operatories and some equipment. Highly desired medical/dental building on the LA's West Side. Great opportunity for a Specialty start-up!

NEW LISTING - \$1,100,000 - This office does it all! General Dentistry / Specialty Practice in Sacramento, Sacramento County, Northern California, with two (2) suites, one consists of general dentistry, the other does Specialty work. Nine (9) total operatories, six (6) equipped, three (3) plumbed, not equipped, with sterilization room, adjustment lab, x-ray room, dark room, reception area, staff lounge, private office, and storage room. Digital xrays, paperless office. Member of most PPO/HMO plans, large monthly cap checks.

NEW LISTING - \$450,000 - General Dentistry Practice in North San Diego County, Southern California with five (5) operatories, sterilization room, adjustment lab, dark room, reception area, staff lounge, and business office. Located in a professional building. Established over 37 years, this practice refers out all specialty work. Room to grow!

\$1,160,000 - General Dentistry Practice in North Orange County, Southern California with five (5) operatories, fully equipped, sterilization room, adjustment lab, dark room, staff lounge, business office, private office. Practice has been established for 47 years. In Escrow.

PRICE REDUCTION - \$4,500,000 - Implant Practice in Orange County, Southern California. This is a large, state-of-the-art practice with an in-house, full-service lab, private office, call center, and much more all located in a beautiful professional building.

\$430,000 - Prosthodontic Practice in Walnut Creek, Contra Costa County, Northern California with three (3) operatories, fully equipped, two-desk laboratory, administrative office, and private office near a retirement community. Doctor retiring, 28 years in the same location.

\$120,000 - General Dentistry Practice in Rancho Cucamonga, San Bernardino County, Southern California, with three (3) operatories, sterilization/lab combo, reception room and much more in a busy retail center. Practice has been in business over 20 years. Call our office for more information.

\$120,000 - Dental Leasehold Improvements and Equipment in Lake Forest, Orange County, Southern California with four (4) operatories, sterilization room, reception room, staff lounge, and private office in a retail center with plenty of foot traffic.

\$300,000 - General Dentistry Practice in Brea, Orange County, Southern California, with four (4) operatories, includes equipment, sterilization room, private office in a shopping center near mall and freeway. In Escrow.

\$500,000 - General Dentistry Practice in South Orange County, Southern California with four (4) operatories, fully equipped, sterilization-lab combo, adjustment lab, staff lounge, private office, over 31 years of goodwill, doctor retiring.

NEW LISTING - \$650,000 - General Dentistry practice in North Orange County, Southern California with six (6) operatories, \$13k cap checks/union per month, 20 years in same location. Call our office for more information.

PRICE REDUCTION - \$300,000 - General Dentistry Practice in Los Alamitos, Orange County, Southern California with seven (7) operatories, sterilization room, wet lab, business office, private office, staff lounge. Located on a busy street with plenty of frontage.

\$175,000 - Leasehold Improvements in Pasadena, Los Angeles County, Southern California with six (6) Adec Chairs/Lights in a great part of town. Contact our office for more information.

PRICE REDUCTION - \$675,000 - Dental Leasehold Improvements/ Equipment and Real Estate in Santa Ana, Orange County, Southern California with seven (7) total operatories, five (5) equipped, two (2) plumbed, not equipped. Also includes sterilization area, adjustment lab, dark room, staff lounge, business office, and private office. Open floor plan that would be a great set-up for GP or Specialty practice with soothing neutral colors. A great opportunity to own real estate in Orange County. Near Western Medical Center.

\$450,000 - General Dentistry Practice in La Verne, Los Angeles County, Southern California with four (4) operatories, private office, staff lounge, sterilization/lab combo, adjustment lab, x-ray room, dark room, reception area in a retail center. Over 33 years of Goodwill. In Escrow.

\$225,000 - General Dentistry Practice in San Juan Capistrano, South Orange County, Southern California with three (3) operatories, sterilization room, adjustment lab, 2 x-ray rooms, staff lounge, private office in a business complex. 31 years of goodwill, doctor is retiring. In Escrow.

\$545,000 - Amalgam-free General Dentistry Practice in Westwood, Los Angeles County, Southern California with five (5) operatories, includes equipment, wet lab, consultation/seminar room, sterilization room. Doctor retiring. Great location across from UCLA campus in a professional building.

\$80,000 - Dental Leasehold Improvements/Equipment in Diamond Bar, Southern California, with four (4) equipped operatories, sterilization room, lab, located in a strip center, beautiful view of mountains. Great start-up opportunity for the right price.

A. LEE MADDOX, DDS, ESQ. BROKER NUMBER - 01801165

888-685-8100 | INFO@MADDOXPRACTICEGROUP.COM | WWW.MADDOXPRACTICEGROUP.COM



COMPREHENSIVE & PROFESSIONAL LEGAL SERVICES EXCLUSIVELY FOR DENTISTS

- Lease Reviews
Partnership Agreements
Practice Purchase Agreements
Corporation Formation / Dissolutions
Space Sharing Group / Solo Agreements
Associate / Independent Contractor Agreements
MSO /BSO Agents
LLC Formation and Agreements

A. LEE MADDOX, DDS

EMAIL: LMADDOX@CADENTALLAW.COM | WWW.CADENTALLAW.COM

EXPERIENCE

PROFESSIONALISM

INTEGRITY

EXPERTISE

Continuing Education Courses

Listed are C.E. courses offered by California's dental schools, local dental societies, ethnic dental societies and specialty organizations, from July through December 2012. For more information, please contact the course provider.

TOPIC	DATE	LECTURER(S)	LOCATION	COST	UNITS
ARTHUR A. DUGONI SCHOOL OF DENTISTRY dental.pacific.edu/ce1					
Hospital Dentistry	July 21-22	Paul Glassman, DDS, MA, MBA; Allen Wong, DDS, EdD	San Francisco	\$335 dentist; \$295 allied dental professionals	13.5
Participation Course with Hard and Soft Tissue Lasers	Aug. 3-4	Robert Convissar, DDS	San Francisco	\$595 (limited to 25)	12
The Essentials of Esthetics	Sept. 8	Howard Chi, DMD, MA	San Francisco	\$395 (limited to 24)	7
5th Annual Pacific Dental Hygiene Conference	Sept. 15	Casey Hein, RDH, MBA	San Francisco	\$265 dentist; \$185 allied dental professionals	7
Travel CE Program: Minimally Invasive and Maximally Effective Dentistry	Oct. 5-18	Allen Wong, DDS, EdD	China	\$435	12
Certification in Radiation Safety for Allied Dental Professionals	Oct. 6, 27	Gurminder, Sidhu, BDS, DDS, MS	San Francisco	\$625 (limited to 24)	32
Infection Control and the California Dental Practice Act	Nov. 10	Eve Cuny, BA, MS; Bruce Peltier, PhD, MBA	San Francisco	\$125	4
The Aesthetic Revolution: Setting New Standards in Cosmetic Dentistry	Nov. 16-18	Dino Javaheri, DMD; Howard Chi, DMD, MA; Michael Jacobs, DDS, BS, MS	San Francisco	\$1,095	23
Don't Just Inject, Add Some Finesse: Local Anesthesia Hands-on Workshop	Dec. 1	Alan Budenz, MS, DDS, MBA; Bernadette Alvear Fa, DDS	San Francisco	\$375 (limited to 24)	7
CALIFORNIA STATE ASSOCIATION OF ENDODONTISTS csaendo.org					
Vital Pulp Therapy	Oct. 26, 27	George Bogen, DDS	Newport Beach	\$50 CSAE member	1.5
Endo in the Implant Era	Oct. 26, 27	Richard Schwartz, DDS	Newport Beach	\$50 CSAE member	4
Autotransplantation of Teeth	Oct. 26, 27	Mitsuhiro Tsukiboshi, DDS, PhD	Newport Beach	\$50 CSAE member	3
Peer Review Endodontic Calibration Workshop	Oct. 28	TBA	Newport Beach	No Fee	5
CENTRAL COAST DENTAL SOCIETY centralcoastds.org					
Infection Control, OSHA & The Dental Practice Act	Sept. 21	Leslie Canham, RDH	San Luis Obispo	\$240	6
Evidence Based Dentistry	Oct. 26	Janet Bauer, DDS	San Luis Obispo	\$240	7
FRESNO-MADERA DENTAL FOUNDATION fmdentalfoundation.org					
New Dimensions in Endodontics	Aug. 5	Alex Fleury, DDS, MS	Fresno	\$140 FMDF member dentist; \$170 non-FMDF member dentist; \$90 RDH, RDA, Tech; \$75 associate member RDH, RDA	7
TBA	Sept. 7	TBA	Fresno	\$140 FMDF member dentist; \$170 non-FMDF member dentist; \$90 RDH, RDA, Tech; \$75 associate member RDH, RDA	7

TOPIC	DATE	LECTURER(S)	LOCATION	COST	UNITS
FRESNO-MADERA DENTAL FOUNDATION <i>CONTINUED</i>					fmdentalfoundation.org
TBA	Sept. 7	TBA	Fresno	\$140 FMDF member dentist; \$170 non-FMDF member dentist; \$90 RDH, RDA, Tech; \$75 associate member RDH, RDA	7
TBA	Oct. 5	TBA	Fresno	\$140 FMDF member dentist; \$170 non-FMDF member dentist; \$90 RDH, RDA, Tech; \$75 associate member RDH, RDA	7
Oral Cancer Update	Nov. 9	William Carpenter, DDS; Sol Silverman, DDS	Fresno	\$140 FMDF member dentist; \$170 non-FMDF member dentist; \$90 RDH, RDA, Tech; \$75 associate member RDH, RDA	7
HARBOR DENTAL SOCIETY					harbordentalsociety.org
What's New in Local Anesthesia and Sedation	Sept. 13	Stanley Malamed, DDS	Lakewood	\$175 ADA member; \$60 hygienist; \$40 dental assistants/front office	7
Oral Surgery for the GP	Oct. 11	Alan L. Felsenfeld, DDS	Lakewood	\$75 ADA member; \$60 hygienist; \$40 dental assistants/front office	3
OSHA, Infection Control, California Dental Practice Act Law	Nov. 15	Marcella Oster, RDA	Lakewood	\$175 ADA member; \$60 hygienist; \$40 dental assistants/front office	7
Staff Appreciation Night — Program TBD	Dec. 6	TBD	Lakewood	\$75 ADA member; \$60 hygienist; \$40 dental assistants/front office	3
KERN COUNTY DENTAL SOCIETY					kerncountyds.org
Infection Control, Dental Practice Act, OSHA Compliance	July 20	Nancy Andrews, RDH	Bakersfield	\$200 member dentist; \$300 non-member dentist; \$75 auxiliary	6
Contemporary Restorative Dentistry	Sept. 21	Nesam Baba, DDS	Bakersfield	\$200 member dentist; \$300 non-member dentist; \$75 auxiliary	6
Treating the Medically Compromised Patient	Oct. 26	James Garibaldi, DDS	Bakersfield	\$200 member dentist; \$300 non-member dentist; \$75 auxiliary	6
LOMA LINDA UNIVERSITY SCHOOL OF DENTISTRY					dentistry.llu.edu
Advances in Restorative Dentistry	July 8	Gerald Denehy, DDS, MS; Douglass Roberts, DDS, MS	Loma Linda	\$175 dentist, \$125 auxiliary	7
Treatment vs. Prevention: New Insights on Common Oral Conditions	Sept. 30	Jim Grisdale, DDS	Loma Linda	\$175 dentist, \$125 auxiliary	7
Contemporary Management of Traumatic Dental Injuries	Oct. 7	Anthony J. Diangelis, DMD, MPH	Loma Linda	\$175 dentist, \$125 auxiliary	7
Infection Control and California Dental Practice Act	Dec. 2	Nancy Andrews, RDH, BS; Bette Robin, DDS, JD	Loma Linda	\$175 dentist, \$125 auxiliary	7
LOS ANGELES DENTAL SOCIETY					ladental.com
Detecting Dental Fraud	Sept. 18	Stewart Balikov, DDS	Los Angeles	\$65 ADA member	3
Advanced Adhesion (Biomimetic) Dentistry	Oct. 16	David Alleman, DDS	Los Angeles	\$65 ADA member	3
A Night with LADS Experts	Nov. 13	Alexander Waldman, DMD; Harel Simon, DMD; Fanny Yacaman, DDS	Los Angeles	\$65 ADA member	3

TOPIC	DATE	LECTURER(S)	LOCATION	COST	UNITS
MARIN COUNTY DENTAL SOCIETY mcdsweb.org					
Caries	Sept. 18	John D.B. Featherstone, MSc, PhD	San Rafael	\$49 member/staff; \$98 non-member/staff	2
BLS/CPR	Sept. 27, Oct 11, Nov 29	Certified CPR Instructors	San Rafael	\$75 member/staff; \$150 non-member/staff	3.5
California Dental Practice Act	Oct. 16	Art Curley, Attorney at Law	San Rafael	\$49 member/staff; \$98 non-member/staff	2
TBA	Dec. 11	TBD	San Rafael	\$49 member/staff; \$98 non-member/staff	2
MONTEREY BAY DENTAL SOCIETY mbdsdentist.com					
The Latest in Periodontics and Dental Implants	Aug. 24	Hessam Nowzari, DDS, PhD	Monterey	\$280 member; \$130 auxiliary	7
Introduction to Biomimetic Dentistry — How to Get Bonded and Stay Bonded!	Oct. 5	David Alleman, DDS	Monterey	\$280 member; \$130 auxiliary	7
NAPA-SOLANO DENTAL SOCIETY napasolanodentalsociety.org					
Precision, Productivity and Profitability of Implant Prosthetics in Private Practice	Oct. 19	Robert Vogel, DDS	Napa	\$295	7
Dental Law, Infection Control and OSHA	Nov. 21	Tom Terry	Fairfield	\$130	6
NORTHERN CALIFORNIA DENTAL SOCIETY ncdsonline.org					
Implants and Dentures — valuable information you won't want to miss!	Sept. 28	Robert E. Gillis Jr., DMD, MSD	Red Bluff	\$125 member; \$225 non-member; \$55 auxiliary	7
Getting the Staff Out of Your Team and The Passion Centered Practice	Oct. 19	Gary Zelesky	Red Bluff	\$125 member; \$225 non-member; \$55 auxiliary	7
The Art of Dental Therapeutics; Dental Drugs and Over-the-Counter Dental Products	Nov. 2	Peter L. Jacobsen, PhD, DDS	Red Bluff	\$125 member; \$225 non-member; \$55 auxiliary	7
ORANGE COUNTY DENTAL SOCIETY ocds.org					
The Bite Is Right...Occlusal Principles For The Restorative and Implant Practice	Sept. 11	Gary Solnit, DDS	Irvine	\$79	2.5
The Physician-Dentist Synergy In the Treatment Of Sleep Disorders	Oct. 9	Steven Olmos, DDS and Paul A. Selecky, MD	Irvine	\$79	2.5
Putting It All Together...Advanced Esthetics-Space Appropriation & Dentofacial Treatment With Interdisciplinary Dentofacial Therapy	Nov. 13	Brian Vence, DDS	Irvine	\$79	2.5
OSTROW SCHOOL OF DENTISTRY OF USC dent-web02.usc.edu/ce/index.asp <small>CONTINUES ON NEXT PAGE</small>					
Clinical Intravenous Sedation	July 13-15, 20-22	Stanley Malamed, DDS and faculty	Los Angeles	\$12,450 dentist	42
Avoiding and Managing Complications Associated with Implant Therapy: Lecture and Impact Panel	July 14	Bach Le, DDS, MD, FICD and faculty	Los Angeles	\$395 dentist; \$285 auxiliary	8
Esthetic Full-Mouth Implant Reconstruction: Advanced Prosthodontic Techniques for Challenging Patients (Module I - Lecture)	July 20	Harel Simon, DMD	Los Angeles	\$295 dentist; \$215 auxiliary	7
Esthetic Full-Mouth Implant Reconstruction: Advanced Prosthodontic Techniques for Challenging Patients (Module II - Lecture)	July 21	Harel Simon, DMD	Los Angeles	\$295 dentist; \$215 auxiliary	7
Esthetic Full-Mouth Implant Reconstruction: Advanced Prosthodontic Techniques for Challenging Patients (Module I, II & III)	July 20-22	Harel Simon, DMD, and faculty	Los Angeles	\$1,995 dentist; \$1,695 auxiliary	21
Esthetic Full-Mouth Implant Reconstruction: Advanced Prosthodontic Techniques for Challenging Patients (Module III — Hands-On)	July 22	Harel Simon, DMD, and faculty	Los Angeles	\$1,875 dentist	7

TOPIC	DATE	LECTURER(S)	LOCATION	COST	UNITS
OSTROW SCHOOL OF DENTISTRY OF USC CONTINUED			dent-web02.usc.edu/ce/index.asp		
Esthetic Full-Mouth Implant Reconstruction: Advanced Prosthodontic Techniques for Challenging Patients (Module III - Hands-On)	July 22	Harel Simon, DMD, and faculty	Los Angeles	\$1,875 dentist	7
38th Annual Review of Continuing Education in Dentistry — Maui, Hawaii	July 23–26	Stanley Malamed, DDS and Ken Reed, DMD	Maui, Hawaii	\$595 dentist	16
Simplifying Anterior Restorations: Problem Solving in the Esthetic Zone (Part I & II - Lecture & Hands-On)	July 27–29	Abdi Sameni, DDS, and faculty	Los Angeles	\$1,995 dentist	21
Simplifying Anterior Restorations: Problem Solving in the Esthetic Zone (Part I - Lecture)	July 27	Abdi Sameni, DDS, and faculty	Los Angeles	\$295 dentist; \$225 auxiliary	7
Clinical Intravenous Sedation	Aug. 3–5, 10–12	Stanley Malamed, DDS and Ken Reed, DMD	Los Angeles	\$12,450 dentist	42
The Artistic Dentist: Excellence in Direct Anterior and Posterior Composites	Aug. 17–18	Jose-Luis Ruiz, DDS, FAGD, and faculty	Los Angeles	\$1,345 dentist; \$795 auxiliary	14
New Approaches for Antimicrobial Treatment of Periodontal Disease	Aug. 24	Jorgen Slots, DDS, DMD, PhD, MS, MBA	Los Angeles	\$285 dentist; \$215 auxiliary	7
Mastering Bone Grafting for Esthetic Implant Site Development (Module I — Lecture and Hands-On Workshop)	Aug. 25	Bach Le, DDS, MD, FICD and faculty	Los Angeles	\$1,245 dentist; \$645 auxiliary	8
Mastering Bone Grafting for Esthetic Implant Site Development (Module II - Cadaver Workshop)	Aug. 26	Bach Le, DDS, MD, FICD and faculty	Los Angeles	\$1,765 dentist; \$1,045 auxiliary	7
Fundamentals of Implant Surgery and Restoration	Sept. 7–9, Oct. 6–7, Nov. 10–11	Homayoun H. Zadeh, DDS, PhD, and faculty	Los Angeles	\$4,395 dentist; \$2,195 auxiliary	56
USC Ruth Ragland 26th Dental Hygiene Symposium	Sept. 8	Diane Melrose, RDH, and faculty	Los Angeles	\$195 dentist	7
What We Know and Do Not Know About Dental Implants	Sept. 14	Jan Lindhe, LDS, OD, DMD and Hessam Nowzari, DDS, PhD	Los Angeles	TBD	7
Functional Crown Lengthening — Enhancing Restorative Treatment with Periodontal Surgery	Sept. 15	Ziv Simon, DMD, MSc and faculty	Los Angeles	TBD	7
The USC Fifth International Restorative Dentistry Symposium	Sept. 21–22	Abdi Sameni, DDS, and International Speakers	Los Angeles	\$495 dentist; \$375 auxiliary	14
Team Driven Diagnosis, Treatment Planning and Acceptance for a Successful Esthetic Practice	Sept. 28–29	Jose-Luis Ruiz, DDS, FAGD, and faculty	Los Angeles	\$595 dentist; \$425 auxiliary	14
Emerging Diseases, Infection Control and California Dental Practice Act	Sept. 15	Joyce Galligan, RN, DDS; Patricia Galligan, JD, LL.M in taxation	Los Angeles	\$195 dentist; \$155 auxiliary	6
Pain Medications Update for Dentists Treating Chronic Pain and TMD	Sept. 28–29	Glenn Clark, DDS, MS and faculty	Los Angeles	\$495 dentist; \$355 auxiliary	14
The USC Fifth Geriatric Dentistry Symposium	Oct. 12–13	Roseann Mulligan, BA, DDS, MS, FADPD, DABSCD and faculty	Los Angeles	\$445 dentist; \$325 auxiliary	14
Esthetic Periodontal Surgery for the General Practitioner (Module I - Lecture)	Oct. 19	Ziv Simon, DMD, MSc	Los Angeles	\$295 dentist; \$225 auxiliary	7
Esthetic Periodontal Surgery for the General Practitioner: A Hands-On Course (Module I & II - Lecture and Hands-On)	Oct. 19–21	Ziv Simon, DMD, MSc	Los Angeles	\$1,845 dentist	21
Supra-Gingival Dentistry Workshop: Easy, Predictable Porcelain Veneer, Onlays and Full Crowns	Oct. 26–27	Jose-Luis Ruiz, DDS, FAGD, and Boris Keselbrener, DDS	Los Angeles	\$1,895 dentist	14

TOPIC	DATE	LECTURER(S)	LOCATION	COST	UNITS
OSTROW SCHOOL OF DENTISTRY OF USC CONTINUED				dent-web02.usc.edu/ce/index.asp	
"Prepress" Porcelain Veneers	Nov. 3-4	Domenico Cascione, CDT, Sillas Duarte, DDS	Los Angeles	\$1,195 dentist; \$395 auxiliary	14
Esthetic Full-Mouth Implant Reconstruction: CAD/CAM Restorations and Computer Guided Technology (Module I - Lecture)	Nov. 9	Harel Simon, DMD	Los Angeles	\$295 dentist; \$215 auxiliary	7
Esthetic Full-Mouth Implant Reconstruction: CAD/CAM Restorations and Computer Guided Technology (Module II - Lecture)	Nov. 10	Harel Simon, DMD	Los Angeles	\$295 dentist; \$215 auxiliary	7
Esthetic Full-Mouth Implant Reconstruction: CAD/CAM Restorations and Computer Guided Technology (Module III - Hands-On)	Nov. 11	Harel Simon, DMD, and faculty	Los Angeles	\$1,875 dentist	7
Esthetic Full-Mouth Implant Reconstruction: CAD/CAM Restorations and Computer Guided Technology (Module I, II & III - Lecture and Hands-On)	Nov. 9-11	Harel Simon, DMD, and faculty	Los Angeles	\$1,995 dentist; \$1,695 auxiliary	21
The USC Eleventh International Endodontic Symposium	Nov. 16-17	Ilan Rotstein, DDS, faculty and international speakers	Los Angeles	\$495 dentist; \$355 auxiliary	14
Pediatric Oral Sedation Certification Program	Nov. 14-18	Stanley Malamed, DDS, and faculty	Los Angeles	\$3,190 dentist; \$590 auxiliary	21
A Contemporary Approach to Diagnosis, Treatment Planning and Therapy in Periodontics	Nov. 30	Ziv Simon, DMD, MSc, and faculty	Los Angeles	\$285 dentist; \$195 auxiliary	7
Live Surgeries at USC: Sinus Augmentation Via Crestal Approach in Patients with a Residual Bone Height of 2 to 4 mm	Dec. 1	Hessam Nowzari, DDS, PhD, Kang Min Ahn, DDS, PhD	Los Angeles	TBD	7
Implant Therapy for Edentulous Patients	Dec. 8-9	Homayoun H. Zadeh, DDS, PhD, and faculty	Los Angeles	\$1,495 dentist; \$795 auxiliary	16
PACIFIC COAST SOCIETY OF ORTHODONTISTS				pcsoortho.org	
PCSO 2012 Annual Session	Oct. 5 - 7	Various	Monterey	\$255	17.5
PCSO 2012 Post Annual Session	Oct. 8-9	Tim Wheeler, DMD, PhD and Peter Ngan, DMD	Monterey	\$250	6
PUNJABI DENTAL SOCIETY				pdsociety.com	
California Law, Infection Control and Risk Management	July 29	Att. Patrick Wood, Rodney M. Stine, Gail Harris	Montebello	\$79	7
Esthetic Dentistry	Aug. 26	Foroud Hakim, DDS, MBA, BS	San Jose	\$89	7
Endodontics for General Dentist	Sept. 30	James Jesse, DDS	Montebello	\$79	7
Tips, Tricks and Advances in Prosthetics	Oct. 28	Gregori Kurtzman, DDS	San Jose	\$89	7
Minimally Invasive Dentistry	Nov. 18	Ron Kaminer, DDS	Montebello	\$79	7
SACRAMENTO DISTRICT DENTAL SOCIETY CONTINUES ON NEXT PAGE				sdds.org	
CPR: Basic Life Support for the Healthcare Professional	Aug. 4	SDDS Instructors	Sacramento	Contact SDDS	4
Predictable Anterior Aesthetics with Implant Dentistry	Sept. 11	Jeff Brucia, DDS	Sacramento	Contact SDDS	2
HR Audio Conference - Document, Discipline and Discharge	Sept. 13	Mari Bradford, California Employers Assn.	Sacramento	Contact SDDS	1
Restorative Dentistry	Sept. 14	Lou Graham, DDS	Sacramento	Contact SDDS	5-7 (TBD)
Fraud and Embezzlement	Sept. 20	Craig Fechter, CPA	Sacramento	Contact SDDS	2
The Political Wrangling of Patient Care	Oct. 9	Dan Walters, Political Columnist, Sac Bee	Sacramento	Contact SDDS	2
Licensure in a Day: CA Dental Practice Act, Infection Control and OSHA Refresher	Oct. 12	TBA	Sacramento	Contact SDDS	6

TOPIC	DATE	LECTURER(S)	LOCATION	COST	UNITS
SACRAMENTO DISTRICT DENTAL SOCIETY CONTINUED					sdds.org
CPR: Basic Life Support for the Healthcare Provider	Nov. 3	SDDS Instructors	Sacramento	Contact SDDS	4
Pay Me or Pay Uncle Sam (Maximize Your Profits, Minimize Your Tax Liability)	Nov. 7	John Urrutia, CPA	Sacramento	Contact SDDS	TBD
Forensic Case Files	Nov. 13	Jim Wood, DDS	Sacramento	Contact SDDS	2
HR Audio Conference — Wages & HR Traps	Nov. 15	Mari Bradford, California Employers Assn.	Sacramento	Contact SDDS	1
SAN FERNANDO VALLEY DENTAL SOCIETY					sfvds.org
Hot Topics in Aesthetic and Restorative Dentistry	Sept. 12	David Hornbrook, DDS	Van Nuys	\$175 member; \$90 auxiliary; \$75 retired member; \$300 non-member	7
Fighting Dental Disease: Crugs, Bugs and Dental Products	Oct. 10	Peter Jacobsen, DDS, PhD	Van Nuys	\$175 member; \$90 auxiliary; \$75 retired member; \$300 non-member	7
Biomimetic and Minimally Invasive Dentistry	Nov. 7	Randy Shoup, DDS	Van Nuys	\$175 member; \$90 auxiliary; \$75 retired member; \$300 non-member	7
SAN FRANCISCO DENTAL SOCIETY					sfds.org
Complications of Dental Treatment	Aug. 16	Mehran Hossaini, DMD	San Francisco	\$74 ADA member dentist/staff; \$114 non-ADA member dentist	2
Infection Control/Bloodborne Pathogens and Hazardous Communication Refresher	Aug. 24	Marcella Oster, RDA	San Francisco	\$95 ADA member dentist/staff; \$140 non-ADA member dentist	4
California Dental Practice Act	Aug. 24	Marcella Oster, RDA	San Francisco	\$60 ADA member dentist/staff; \$90 non-ADA member dentist	2
CPR Renewal	Aug. 29	Adrian Curry, EMT	San Francisco	\$65 ADA member dentist/staff; \$100 non-ADA member dentist	4
Evidence Based Differential Implant Treatment Planning	Sept. 13	Steven Sadowsky, DDS	San Francisco	\$74 ADA member dentist/staff; \$114 non-ADA member dentist	2
CPR Basic Life Saving	Sept. 22	Adrian Curry, EMT	San Francisco	\$95 ADA member dentist/staff; \$140 non-ADA member dentist	4
CPR Renewal	Nov. 28	Adrian Curry, EMT	San Francisco	\$65 ADA member dentist/staff; \$100 non-ADA member dentist	4
Infection Control/Bloodborne Pathogens and Hazardous Communication Refresher	Nov. 30	Marcella Oster, RDA	San Francisco	\$95 ADA member dentist/staff; \$140 non-ADA member dentist	4
California Dental Practice Act	Nov. 30	Marcella Oster, RDA	San Francisco	\$60 ADA member dentist/staff; \$90 non-ADA member dentist	2
Annual Meeting and Installation	Dec. 6	Speaker TBA	San Francisco	\$74 ADA member dentist/staff; \$114 non-ADA member dentist	2
SAN GABRIEL VALLEY DENTAL SOCIETY CONTINUES ON NEXT PAGE					sgvds.org
Advancements in Endodontics	Sept. 18	George Bruder, DDS	Alhambra	\$65 member; \$100 non-member	3
Medical Emergencies	Oct. 9	Tom Lenhard, DDS	Alhambra	\$65 member; \$100 non-member	3

TOPIC	DATE	LECTURER(S)	LOCATION	COST	UNITS
SAN GABRIEL VALLEY DENTAL SOCIETY CONTINUED					sgvds.org
Implants	Nov. 13	Saj Jivraj, DDS	Alhambra	\$65 member; \$100 non-member	3
Dental Compliance Demystified (California Dental Practice Act/Infection Control)	Sept. 13	Tom Terry	Lodi	TBD	4
Rejuvenate Your Practice — It's Easier Than You Think!	Nov. 15	Virginia Moore and Debbie Castagna	Stockton	TBD	2
SANTA BARBARA VENTURA COUNTY DENTAL SOCIETY					sbvcds.org
How to Grow, Manage and Sell Your Dental Practice	Sept. 18	Jason Wood, Esq	Oxnard	\$75	3
Biomimetic Dentistry	Nov. 16	David S. Alleman, DDS	Oxnard	\$185	7
Infection Control and Dental Practice Act	Dec. 14	Noel Kelsch, RDH and Jason Wood, Esq	Oxnard	\$150	4
SANTA CLARA COUNTY DENTAL SOCIETY					sccds.org
September General Monthly Meeting "Evidence Based Ridge Preservation: The Use of Site Analysis to Customize Treatment and Maximize"	Sept. 13	Henry Greenwell, DMD	Campbell	Free SCCDS member; \$35 staff or guest	2
October General Monthly Meeting "Everything I Know About Endodontics, I Learned After Dental School"	Oct. 11	Jim Bahcall, DMD, MS	Campbell	Free SCCDS member; \$35 staff or guest	2
November General Monthly Meeting "Oral Precancerous Changes"	Nov. 8	Nita Wu, DMD, MPH, PhD	Campbell	Free SCCDS member; \$35 staff or guest	2
December General Monthly Meeting "TBA"	Dec. 13	David Rothman, DDS	Campbell	Free SCCDS member; \$35 staff or guest	2
STANISLAUS DENTAL SOCIETY					stanislausdental.org
Biomimetic Dentistry	Oct. 19	David S. Alleman, DDS	Modesto	\$100 CDA member; \$75 hygienist; \$50 dental assistant; \$200 non-CDA members	5
TRI-COUNTY DENTAL SOCIETY					tcds.org
Infection Control, CA Dental Practice Act & OSHA	Sept. 21	Nancy Andrews	Riverside	\$90 member; \$110 non-member. After Sept. 10: \$110 member; \$130 non-member	7
Diagnostic Challenges in Endodontics	Nov. 15	Rajiv Bhagat, DDS	Riverside	\$45 member; \$55 non-member. After Nov. 1: \$65 member; \$75 non-member	2
TULARE-KINGS DENTAL SOCIETY					tkdentalsociety.com
Infant Oral Health	Aug. 17	Jeffrey Wood, DDS, UOP	Visalia	TBD	7
California Dental Practice Act and "Infection Control"	Sept. 14	Leslie Canham, RDA, CDA	Visalia	TBD	4
UCLA SCHOOL OF DENTISTRY CONTINUING EDUCATION CONTINUES ON NEXT PAGE					dentistry.ucla.edu/continuing-education
UCLA Hawaii 2012: Esthetic Dentistry and Periodontics	July 2-6	Ron Jackson, DDS; Jimmy Eubank, DDS, and others	Poipu, Hawaii	\$798 dentist; \$395 hygienist; \$295 auxiliary	30
Pit & Fissure Sealants: RDA Required Course	July 14-15	Cara Batson, RDA; Charlene Flowers-Taylor, RDA	Los Angeles	\$575	16
UCLA Aesthetic Continuum	July 19-22, Aug. 16-19, Sept. 13-16	Jimmy Eubank, DDS; Brian LeSage, DDS, and others	Los Angeles	\$6,995	90
Sleep Medicine Intensive One Week Mini-Residency	July 23-28	Robert Merrill, DDS, MS and Dennis Bailey, DDS	Los Angeles	\$6,995	45

TOPIC	DATE	LECTURER(S)	LOCATION	COST	UNITS
UCLA SCHOOL OF DENTISTRY CONTINUING EDUCATION			dentistry.ucla.edu/continuing-education		
TMD/OFP Mini-Residency	Aug. 3-4, Sept. 14-15, Oct. 12-13, Nov. 9-10, Dec. 14-15	Robert Merrill, DDS, MS	Los Angeles	\$3950	60
Sleep Medicine Mini-Residency	Aug. 10-11, Sept. 7-8, Oct. 5-6, Nov. 2-3, Nov. 30-Dec. 1	Robert Merrill, DDS, MS and Dennis Bailey, DDS	Los Angeles	\$5995	60
Infection Control: RDA Required Course	Aug. 11	Cara Batson, RDA, and Charlene Flowers-Taylor, RDA	Los Angeles	\$250	8
Dentoalveolar Surgery	Aug. 25	Earl G. Freymiller, DMD, MD and Alan L. Felsenfeld, DDS	Los Angeles	\$198 dentist; \$98 auxiliary	7
Pediatric Clinical Tips for the General Practitioner	Sept. 8	Daniela Rodriguez Silva, DDS, MS	Los Angeles	\$198	7
Guidelines to Implementing Practice-based Research into your Dental Practice	Sept. 22	Francesco Chiappelli, PhD	Los Angeles	\$198	7
Certification in Pediatric Oral Sedation	Sept. 27-29	Christine Quinn, DDS, MS and Steven I. Ganzberg DMD	Los Angeles	\$2995 dentist; \$225 auxiliary	26
California Dental Practice Act & Infection Control	Sept. 29	Andy Wong, DDS	Los Angeles	\$135 dentist; \$95 auxiliary	4
Dental Ethics for a Changing Profession	Sept. 29	Gary Herman, DDS	Los Angeles	\$198	7
Re-Certification in Pediatric Oral Sedation	Sept. 29	Christine Quinn, DDS, MS and Steven I. Ganzberg DMD	Los Angeles	\$295	8
Periodontal Surgery Workshop	Oct. 6-7	Paulo Camargo, DDS, MS and Philip Melnick, DMD	Los Angeles	\$998	16
Practical Occlusion for Esthetics & Function	Oct. 12-14	Jimmy Eubank, DDS and Philip Kroll, DDS	Los Angeles	\$4495	20
UCLA Alumni Lecture & Breakfast	Oct. 6	Richard Hirschinger, DDS	Los Angeles	no cost for UCLA School of Dentistry alumni; \$98 non-alumni	3
8th Annual Endodontic Distinguished Lecture	Oct. 13	Ove Peters, DDS and others	Los Angeles	\$295	7
Recent Advances in the Detection and Management of Pre-Cancer Lesions	Oct. 13	Diana V. Messadi, DDS, MMSc, DMSc	Los Angeles	\$135	4
RDAEF Module 2	Oct. 20-21, Oct. 27-28, Nov. 3-4, Nov. 10-11, Dec. 1-2, Dec. 8-9, Dec. 15-16	Richard Stevenson, DDS	Los Angeles	\$4,995 auxiliary	128
Complete Dentures: Back to the Future	Oct. 27	Eleni Roumanas, DDS and Kumar Shah, BDS	Los Angeles	\$198	7
HIV Infection: An Update on Management and Emerging Issues	Oct. 27	Fariba S. Younai, DDS	Los Angeles	\$198 dentist; \$98 auxiliary	7
1st Annual Byoung-In Suh Distinguished Lecture in Restorative Dentistry Maximizing Predictability and Longevity in Adhesive Dentistry	Nov. 3	Byoung-In Suh, PhD and Edward McLaren, DDS and others	Los Angeles	\$198	7
Interpersonal Skills and Clinical Psychology	Nov. 3	Craig D. Woods, DDS, MA	Los Angeles	\$198 dentist; \$98 auxiliary	7
The Diagnostic Box: Esthetics, Occlusion, Comprehensive Care	Nov. 9-11	Jimmy B. Eubank, DDS and Todd Schoenbaum, DDS	Los Angeles	\$3995	24
Medical Emergencies for the Dental Team	Nov. 10	Steven I. Ganzberg DMD	Los Angeles	\$198	7

TOPIC	DATE	LECTURER(S)	LOCATION	COST	UNITS
UCLA SCHOOL OF DENTISTRY CONTINUING EDUCATION <i>CONTINUED</i>			dentistry.ucla.edu/continuing-education		
Infection Control: RDA Required Course	Nov. 17	Cara Batson, RDA, Charlene Flowers-Taylor, RDA	Los Angeles	\$250	8
Your Patient's Medical History: What you Don't know can hurt you	Nov. 17	Earl G. Freymiller, DMD, MD, and Alan L. Felsenfeld, DDS	Los Angeles	\$198	7
Hot Topics in Dentistry	Dec. 1	Richard Stevenson, DDS and Dennis Bailey, DDS and others	Los Angeles	\$198; \$59 qualifying Delta dentists	7
UNIVERSITY OF CALIFORNIA SAN FRANCISCO — FRESNO CAMPUS			fresno.ucsf.edu/continuing_ed		
The End: To Decay, Complications, Sensitivity, Discomfort & Open Contacts	July 20	Todd Snyder, DDS	Fresno	\$155 dentist; \$129 RDH/CDT; \$109 RDA; \$96 resident	7
Endodontics for the General Practitioner	Aug. 17	Mo Kang, DDS	Fresno	\$155 dentist; \$129 RDH/CDT; \$109 RDA; \$96 resident	7
Technology Overview	Oct. 12	TBA	Fresno	\$155 dentist; \$129 RDH/CDT; \$109 RDA; \$96 resident	7
OSHA Review & Infection Control	Nov. 16	Morgan Lawson	Fresno	\$112 dentist; \$107 RDH/CDT; \$97 RDA; \$82 resident	4
Pharmacology Review	Dec. 14	Joel Weber, PharmD	Fresno	\$112 dentist; \$107 RDH/CDT; \$97 RDA; \$82 resident	4
UNIVERSITY OF CALIFORNIA SAN FRANCISCO SCHOOL OF DENTISTRY			dentistry.ucsf.edu/cde		
Evidence-Based Management of Dental Diseases	July 21	John Featherstone, MSc, PhD, Mark Ryder, DMD	San Francisco	TBD	7
Oral Surgery Contemporary Issues	Sept. 7-8	MA Pogrel, DDS, MD	Yosemite	TBD	8
WESTERN LOS ANGELES DENTAL SOCIETY			westernlads.org		
Periodontic Benefits of Orthodontic Therapy	Sept. 11	Kevin Badii, DDS	Culver City	\$75 ADA member dentist; \$120 non-member dentist; \$60 non-dentist	3
Composites	Oct. 30	Sillas Duarte, DDS, MS, PhD	Culver City	\$75 ADA member dentist; \$120 non-member dentist; \$60 non-dentist	3
WESTERN SOCIETY OF PERIODONTOLOGY			wsperio.org		
Variety of Topics	Nov. 10-11	Variety of Speakers	Scottsdale, AZ	TBD	9

Specializing in the Selling and Appraising of Dental Practices



**CALIFORNIA
PRACTICE SALES INC.**

Serving California Since 1974

**"Your local Southern
California Broker"**

Phone (714) 639-2775
(800)697-5656

Fax (714) 771-1346

E-Mail: jknipf@aol.com
rpalumbo@calpracticesales.com
WWW.CALPRACTICESALES.COM



John Knipf & Robert Palumbo

LOS ANGELES COUNTY

ARCADIA - (GP) Modern designed fee for service off. w/ 50 yrs of gdwll. 3 ops & 2 chair in open bay. NET OF \$255K. ID #4137.
CULVER CITY - 40+ yrs of gdwll this fee for service practice is located on one story med/dent bldg. 4 ops. NET \$126K. ID# 4129
LOMITA - Established in 2007 in a single retail building w/ heavy traffic flow. Seller works 3 dys/wk. Grossed ~\$222K in 2011. ID#4087.
LOS ANGELES - General Practice w/ 18 yrs gdwll in free standing bldg with 5 spacious ops. Monthly revenues of \$30K/mo. ID# 4113.
LOS ANGELES (GP) - State-of-the art off w/ 34 yrs gdwll on one of the busiest blvds. Has 4 eq. ops w/. Dentrix software. ID#4147
RESEDA (GP) - Corner location with excellent signage. Has over 17 years of goodwill. Grossed \$729K in 2011. NET OF \$215K. ID#4175.
SAN GABRIEL (Spec./GP) - 2 practices bundled here that can be sold together or separately. Corner location w/ great signage. ID#4139.
SANTA CLARITA - GP nestled up against the mountains with a beautiful view. Consists of 4 eq. ops & 2 plmbd in 1 story bldg. ID#4133.
TARZANA - Located in 3 story Med bldg. 5 eq ops. Seller works 2.5 days/wk. Grossed \$447,681 in 2011. NET OF \$136K ID #4157.
TORRANCE - Leasehold & Equip Only! Modern designed office established ~10.5 yrs ago w/ 3 eq ops in 1,215 sq.ft. ste. ID #4125
W. HOLLYWOOD - Located in Prestigious bldg w/ mountain views. 3 ops. 48 yrs of gdwll. Grossed approx.\$1,031,093 in 2011. ID#4153.
WESTLAKE VILLAGE - Equip & Charts! Beautiful office set up for Paperless / Digital. Located on 2nd floor of Med bldg. ID #3211.

ORANGE COUNTY

ANAHEIM (GP) - Turn-key practice located in busy shopping center. Established in 1999. State-of-the-art facility w/ 4 eq. ops. ID #4171.
HUNTINGTON BEACH (GP) - Long established practice in 1 story shopping center w/ 4 eq. ops. Grossed \$430K in 2011. ID #4145.
IRVINE - Located in busy shopping cntr w/ lots of foot traffic. Modern designed w/ 4 eq. ops. Over 10 years of goodwill. ID #4053.
IRVINE - Great opportunity for GP or Specialist!! Leasehold & Equip Only! 5 eq. ops. located in busy large shopping center. ID #3401.
LAGUNA HILLS - General practice located in 2 story busy shopping center. 19 yrs gdwll. 4 eq. ops. NET OF \$269K . ID # 4155.
LAGUNA NIGUEL - Turn key office located in busy shopping center w/ 3 eq ops in 1,119 sq. ft. suite. Digital office. ID#4163
LAKE FOREST - Turn key practice w/ 3 spacious eq ops, 1 plmbd not eq in a 1,200 sq ft ste. Busy shopping center. ID #4123.
ORANGE - Fee for service practice open 4 days/wk located in a single story med center w/ 4 eq. ops., on a 1,040 sq. ft. suite. ID #3531.

RIVERSIDE / SAN BERNARDINO COUNTIES

CATHEDRAL CITY - Leasehold & Equip Only! Bank owned location. Consists of 7 spacious eq. ops. Corner location. ID # 4173.
LA QUINTA - Price Reduced. Leasehold & Equip Only! Located in strip shopping center W/ 3 eq. ops, 1,000 sq. ft. ste. ID#4063
LOMA LINDA - Office is 1,100 sq. ft. w/ 4 eq. ops. Has Easy Dental, Pano & Ceph. 12 yrs gdwll. Grossed ~\$900K in 2011. ID#4131.
MORENO VALLEY (GP) - Turn-Key practice in busy shopping center w/ 3 eq. ops., & 2 plmbd. Established in 2005. ID #3311.
RANCHO MIRAGE (GP) Consist of 3 eq. ops., 1 chair in open bay. Great traffic flow and visibility. Grossed ~\$497K in 2011. ID# 4091.
TEMECULA (GP) - Fee for service practice w/ over 20 yrs of gdwll. Consists of 1,999 sq. ft. suite w/ 6 fully eq. ops. ID #4143.

SAN DIEGO COUNTY

POWAY - This beautiful office consist of 5 eq. ops. Remodeled a year ago. High income patients. NET \$380K. ID# 4119. **SOLD**
SAN DIEGO - Family GP w/ multiple specialties. Off of Freeway 8 and 15. 40 years of goodwill. Grossed ~\$760K in 2011. ID#4107.


VENTURA COUNTY

PORT HUENEME (GP) - Absentee Owner Practice. Established in 1980. Consists of 3 eq. ops, in a 920 sq. ft. suite. ID #4167
VENTURA COUNTY (GP) - Modern designed state-of-the-art practice in single story building. Grossed ~761,436 in 2011. ID #4151

Need CE Credits? View Upcoming Continuing Education Opportunities

<http://www.calpracticesales.com/blog>

Call us about Debt Consolidation & Retirement Planning
VISIT OUR WEBSITE WWW.CALPRACTICESALES.COM
CA DRE#00491323

John Knipf
President  (Neff)

Also serving you: Robert Palumbo, Executive V. P. /Partner, Alice C. King, V.P.,
Greg Beamer, V.P., Tina Ochoa, V.P., & Maria Silva, V.P.

How to Place a Classified Ad

The *Journal* has changed its classified advertising policy for CDA members to place free classified ads online and publish in the *Journal*. Only CDA members can place classified ads. Non-CDA members can place display ads.

All classified ads must be submitted through cda.org/classifieds. Fill out the blank fields provided, including whether the ad is to appear online only or online and in the *Journal*. Click "post" to submit your ad in its final form. The ad will be posted immediately on cda.org and will remain for 60 days.

Classified ads for publication in the *Journal* must be submitted by the fifth of every month, prior to the month of publication. Example: Jan. 5 at 5 p.m. is the deadline for the February issue of the *Journal*. If the fifth falls on a weekend or holiday, then the deadline will be 5 p.m. the following workday. After the deadline closes, classified ads for the *Journal* will not be accepted, altered or canceled. Deadlines are firm.

Classified advertisements available are: Equipment for Sale, Offices for Sale, Offices for Rent or Lease, Opportunities Available, Opportunities Wanted, and Practices for Sale.

For information on display advertising, please contact Corey Gerhard at 916-554-5304 or corey.gerhard@cda.org.

CDA reserves the right to edit copy and does not assume liability for contents of classified advertising.

OFFICES FOR RENT OR LEASE

OFFICE FOR RENT OR LEASE — New modern dental office for lease. Approx. 1,000 sq. ft. Professionally designed and built dental office. 3 equipped ops with dental chair units and X-ray units. Great location in the heart of Silicon Valley. Contact dmengdds@gmail.com or 408-839-4090.

OFFICE FOR RENT OR LEASE — Great opportunity in Newark, CA to start a new practice or to relocate an existing practice (ideal for a new graduate or specialist). Everything is present to start the practice. Dental equipment

and dental instruments are included. 1332 sq. ft. comprised 4 ops, private office, waiting room, business office, lounge, sterilization room, dark room, 2 lavatories & lab. All ops are fully equipped with x-ray, pano, nitrous oxide, air, vacuum, amalgam separator, intra-oral cameras, autoclave, hand pieces & more. Please call 510-792-1456 for more info and appointment for inspection.

OFFICE FOR RENT OR LEASE — Dental specialist wanted to share a beautiful, modern, high-tech 2,254 sq. ft. office with a general dentist in Downtown San Diego, next to Petco Park.

CONTINUES ON 530

When Looking to Invest in Professional Dental Space Dental Professionals Choose



Linda Brown

30 Years of Experience
Serving the Dental Community
Proven Record of Performance

- Dental Office Leasing and Sales
- Investment Properties
- Owner/User Properties
- Locations Throughout Southern California

For your next move,
Contact Linda Brown:
Direct Line: (818) 466-0221
Fax: (818) 593-3850
E-mail: LindaB@TOLD.com
website: www.TOLD.com
CA DRE #: 01465757

TOLD
partners INC.
INDUSTRIAL/COMMERCIAL REAL ESTATE
CA DRE #: 01132455

CLASSIFIEDS, CONTINUED FROM 529

Great opportunity for those who have an existing patient pool, or starting to build their patient pool. The office was built in 2007 with state of the art equipment. Office has 2.5 ops, 2 rest-rooms, office, consultation room, kitchen, lab, sterilization rooms, and reception area. 2 fully plumbed ops, but there is room for 6. Willing to plumb and equip more ops if needed. Save on overhead. Rent/percentage of production is negotiable. Working days are negotiable as well. Must bring own patients. Please email d2thfixr@yahoo.com or call 619-237-0409 if interested.

OPPORTUNITIES AVAILABLE

OPPORTUNITY AVAILABLE — Looking for front office staff. Candidate must be organized, self-sufficient and provide excellent patient care. Experience with collecting payments, and scheduling appointments is preferred. Must have excellent verbal & written communication skills and proficient with computers. Dental and/or medical billing is preferred but not required. Part-time leading into full-time. Email resume to viaalfonse@gmail.com or fax to 408-244-9553.

OPPORTUNITY AVAILABLE — We are a multi-specialty dental office with multiple locations in Northern California. We are looking for a Periodontist to join us on a part-time basis. Excellent opportunity to grow. Please email your resume to bayareadentist2009@gmail.com.

OPPORTUNITY AVAILABLE — Seeking dentist for Ontario, CA dental office. Email anna.arias@hotmail.com or mail to: HR, Arias & Paniagua, DDS, 2448 S. Vineyard Ave, Ste. 107, Ontario, CA 91761. Please, no walk-ins.

OPPORTUNITY AVAILABLE — Looking for an associate general dentist. Part-time/full-time. New graduates welcome. Possible opportunity to buy-in or ownership of practice. Base salary and percentage of production. Negotiable. Contact goveloso@gmail.com or 909-215-4732.

OPPORTUNITY AVAILABLE — Associate dentist with experience needed for busy multispecialty office 2-3 days a week. Must be a team player with great communication skills who excels in providing quality care proficiently. Please email resumes to healthysmilela@gmail.com.

OPPORTUNITY AVAILABLE — We are a multi-specialty dental office with multiple locations. We are looking for an Endodontist to join us on a part-time basis. Excellent opportunity to grow. Please email your resume to bayareadentist2009@gmail.com.

OPPORTUNITY AVAILABLE — Searching for a part-time general dentist at a cosmetically-driven state in the art office in town. Located in a very desirable area with good parking. You have an opportunity to treatment plan and complete treatment on all your patients. We also do Invisalign and

SINCE 1987

Nor Cal **GOLDEN STATE PRACTICE SALESsm**
Specializing In Northern & Central California Practice Sales & Consulting

James M. Rodriguez, MA, DDS

44 Holiday Drive, P.O. Box 1057, Alamo, CA 94507

DRE Licensed Broker # 957227

- ❖ **MARIN COUNTY** - Coll. \$332K, 3 ops, between Sausalito and San Rafael. **SOLD**
- ❖ **PERIODONTAL - S.F. EAST BAY** - Established 30 plus years. Well known and respected in dental community. Seller will stay on contractually for introduction to established referral base.
- ❖ **CENTRAL CONTRA COSTA - DANVILLE** - Established family practice priv/ins UCR, \$1.2M collections, 4 operatories. **SOLD**
- ❖ **SOUTH LAKE TAHOE** - For Lease. 5 ops. Not equipped. No upgrades or additions needed. Call for details.
- ❖ **DUNSMUIR - SHASTA** - Dental office bldg for sale. Call for referral.
- ❖ **CENTRAL VALLEY** - 3 ops., collections \$725K. **PENDING**

*Practice Sales - Presale Complimentary Consultations and Valuation Estimates
Practice Appraisals and Forensic Services - Independent Practitioner Programs*

Each Transaction Handled Personally From Start To Finish

Buyer Consultant Service Available

STRICT CONFIDENTIALITY OBSERVED

925-743-9682

Integrity-Experience-Knowledge-Reputation

e-mail: gspsjimrod@sbcglobal.net

CONTINUES ON 534



The new Delta Dental policy is worse than I originally reported!

*Timothy G. Giroux
DDS/Broker*

Two months ago I discussed the effect of the new Delta Dental policy with respect to how it might affect practice value. My premise at that time was confined only to existing Delta patients who were being “up-billed” and paying the difference out-of-pocket for dental treatment performed by a “Premier” provider. This is just a small part of a larger problem. Several years ago, without full disclosure to “Premier” providers, Delta instituted a “PPO Plus” plan that is indistinguishable to the “Premier” provider. The “Premier” providers on the “PPO Plus” provider list were paid according to their “Premier” fee schedule. These “Premier” practices correctly assumed that all was well as they were always paid according to their fee schedule for all the Delta Plans that they subscribed to. (Most practices have up to twenty different Delta providers.) The situation was undetectable by the “Premier” practices.

Guest what?

Delta is now informing providers that those “PPO plus” plans were not really “Premier” plans. Your name as a “Premier” provider was placed on the list because Delta did not have enough providers to keep subscribers/employers happy (usually the school districts.) So, Delta basically collected a lower premium to be competitive, paid out on a higher fee schedule knowing that it was ultimately unsustainable, and is now pulling the plug by refusing to pay the fee schedule to an associate or new owner of a “Premier” practice.

The owners of “Premier” practices were never notified of this decision. Most of them are still unaware that this could be a problem for their practices. Some have tried to run reports or have made inquiries to Delta, but have not received any definitive answers as to what this might mean for their practices. This policy could result in a 25% reduction of the fee schedule for this group of patients. The problem varies practice-by-practice, depending on the local employers.

Once the policy decision was made, wouldn't it have been prudent to explain and disclose the situation to the provider at the start of the contract and even supply a report estimating the financial effect on the practice based on the 1099's issued for the patient base in this “PPO Plus” category?

While I still believe that this issue should not decrease the value of the practice for the reasons stated in my previous article, the local market has always dictated the sales price. It is really too early to know if this policy will affect the practices already in transition. My understanding of the new policy is Delta is requiring all providers accept all PPO, PPO Plus and Premier fee schedules. The “PPO Plus” fee schedule is now approximately 25% less than the “Premier” fee schedule. On the positive side for Buyers, they will be placed on the regular PPO provider list and this might help generate new patients for the practice to help offset the decrease in revenues. Of course, this offset only works if the practice is capable of accepting additional patients at the lower fee schedule. It is imperative that Buyers have an understanding and a business plan to maximize their practice potential.

What to do?

Minimally, we should demand that Delta provide information to every “Premier only” practice estimating the potential loss of income to the practice if this policy is enforced.

Ideally, we should demand that Delta not enforce this policy on practices of long-term and loyal providers, and maybe only on first-time providers in scratch-start practices. Usually these doctors are more than happy to generate as many patients as possible upon starting their new practice.

I believe the “Premier” providers have every right to feel betrayed, especially if we do see that this policy adversely affects practice values. Many dentists are considering a class action suit outside of organized dentistry even as we write this.

We are doing everything possible to stay on the forefront of this situation. Fortunately for you, there are dental attorneys who are working diligently to help steer all of us through this current issue.

Timothy G. Giroux, DDS owns **Western Practice Sales** and is a member of the nationally recognized dental organization, ADS Transitions. You can stay informed as this issue unfolds by visiting our website: westernpracticesales.com or contacting our office at **800-641-7179**.



HENRY SCHEIN®

PROFESSIONAL PRACTICE TRANSITIONS



“DENTAL PRACTICE BROKERAGE”

Making your transition a reality.

For more information regarding the listings below:

VISIT OUR WEBSITE AT:
WWW.PPTSALES.COM
 (Practice Opportunities)

Practice Sales • Mergers
 Partnerships • Appraisals
 Patient Record Sales

More information is available on our website regarding practices listed in other states, articles, upcoming seminars and more.

- **ANAHEIM:** For Sale-General Dentistry Practice. This 3 op had \$253,000 in collections in 2011. There are 3 ops in this 864 sq. ft. office with 1.5 days of hygiene. Owner works 3 days per week. No welfare or HMO's. Laser, Dentrix Software and Intra-Oral Camera.
- **BISHOP:** For Sale-General Dentistry Practice and Building. After 29 years in the same location this retiring dentist is selling both his practice and building. Collections were \$1,000,243 in 2011 with \$387,000 Adjusted net income. There are 6 days of hygiene in this 5 op 1,800 sq. ft. building. 100% financing is available for both building and practice.
- **CHICO:** For Sale-General Dental Practice. The collections in 2011 were \$1,209,207. There are 7 days of hygiene in this 5 operator, 2,400 sq. ft. office. Equipment includes Laser, Intra-Oral camera, new Cone Beam X-ray and Dentrix software. This excellent practice has 1,824 active patients with 12 new patients a month.
- **CHULA VISTA:** For Sale-General Dentistry Practice and Building. **DECEASED DENTIST** as of March 25th, 2012. This beautiful 11 op. office located in a highly visible prime area in Chula Vista, had collection of \$1,684,000 in 2011 and \$1,730,000 in 2010. There are 5 days of hygiene with approx. 30 new patients per month. Lasers, Intra-Oral Camera, Pan-Ceph, etc. Practice has been in this location since 1998. 100% financing available for practice and building. Staff will stay. #14394
- **EAST BAY:** For Sale-ENDODONTIC PRACTICE. The adjusted net income was \$186,000 in 2011 in this 3 operator, 1000 sq. ft. office. Includes Microscope, X-ray Scanner and PBS software. Transfer of referral base should be excellent. Ideal office for new endodontist or as a satellite practice for established practitioner. Dr. is retiring.
- **EL DORADO HILLS:** For Sale-General dentistry practice. Gross Receipts of \$834K with an adj. net of \$389K, 53% overhead. Office has five equipped operators in 1485 sq.ft. Pano, Intra-oral Camera, Dentrix, 5 days of hygiene. Owner retiring.
- **FOUNTAIN VALLEY:** For Sale-General Dentistry Practice. Gross Receipts \$284,000 with only 47% overhead. Practice has been in its present location for the past 37 years. There are two equipped operators in this 5 op office. E2 2000 software. Doctor is retiring.
- **FREMONT:** For Sale-(General Dentistry Practice Facility and Equipment Sale) Beautiful Central Fremont office in upscale professional building. This is a facility sale with 4 fully equipped treatment rooms, panoramic x-ray, intra-oral camera and nitrous oxide plumbed throughout. Very modern design and efficient layout in approximately 1,400 sq. ft. Seller is relocation to a larger facility. Patients and goodwill are not included.
- **FRESNO:** For Sale-General Dentistry Facility. One of the best opportunities this year. This 3 op dental office comes equipped. It is in a great location and has about 200 active patients. Owner is in the process of completing his Orthodontic training and only works in the office 5 days a month. Complete picture of the office and an inventory list of included furniture and fixtures are available. Everything included for only \$85,000 You can't afford to pass this up. #14383
- **FRESNO:** For Sale-General Dentistry IV Sedation Practice. (MERGER OPPORTUNITY) Owner would like to merge his practice into another high quality general dentistry or IV sedation practice. The merger would be into Buyers office. Seller would like to continue to work as either a partner or associate after the merger. 2010 collections were \$993K with a \$422K adjusted net income. There are 7 days of hygiene. #14250.
- **GLENDALE:** FACILITY SALE-General Dentistry Office Space & Leasehold Improvements Sale- Office located in a medical plaza, 1760 sq. ft. 7 operatories, computerized equipment approximately 5 years old. Two 5-year options available. #14373
- **GRASS VALLEY:** For Sale-General Dentistry Practice. GR of \$307,590 (3 days/wk) with adjusted net income of \$105K. 3 Ops. refers out most/all Ortho. Perio, Endo, Surgery. Intra-Oral Camera, Diagnodent, EZ Dental Software. Good Location. Owner retiring. #14337.
- **GRASS VALLEY:** For Sale-General Dentistry Practice. GR 545K 3 days/wk (4 avail). 3 hygiene days/week. 5 Ops (6 Avail) 1,950 sq ft. Refers out most/all Ortho, Perio, Endo, Surgery. Office has Laser, Intraoral Camera, Pano, & Dentrix Software. Owner retiring. #14372.
- **GRASS VALLEY:** For Sale-General Dentistry Practice. Gross Receipts \$491K with an adjusted net income of \$130K. Overhead 73%. Office leased 1,555 sq ft. 4 equipped operatories 5 available. Laser, Intra-Oral Camera, Cerac, & Eaglesoft software. Owner would like to retire. #37108.
- **GREATER CHICO:** For Sale-General Dentistry Practice. Gross receipts in 2010 were \$584K, with an adjusted net income of \$152K. Approx 1,100 active patients. 4 operatories, Pano, Intra-Oral Camera. Easy dental software. Leased office 1,200 sq. ft. Owner is retiring. #14359.
- **HAWAII (MAUI):** For Sale-General dentistry practice. Gross Receipts of \$636K. Office has four equipped operatories in 1198 sq.ft. Pano, Laser, I.O. Camera, Fiber Optics, 2 ½ days of hygiene. Owner retiring: Don't miss this opportunity to live and work in paradise. #20101
- **HAYWARD:** For Sale-General Dentistry Practice. This practice consists of 1,600 sq ft with 4 treatment rooms in an excellent location. 2010 Gross was \$501,000 with a \$228K adjusted net income. Dental Vision software, Average age of equipment is 8 yrs. Approximately 1,200 active patients.
- **IRVINE & COSTA MESA:** For Sale-General Dentistry practice combined. Gross receipts combined \$781K with adjusted net of \$396K. Both office spaces are leased with 4-5 ops in each. Both are 1,600 sq. ft. Irvine is equipped with Intra-Oral Camera, Pano & Dentrix. Costa Mesa is equipped with Laser, Intra-Oral Camera, Pano and Dentrix. #14355.
- **LANCASTER:** For Sale-General Dentistry Practice. This 4 operator office is located in 2,360 Sq Ft on the second floor of an attractive Medical Dental office building. Gross receipts were \$676,000 with a \$174K adjusted net income. Dentist is retiring after 39 years. 4 days of hygiene. Additional operatories could be added to existing space. Great location.#14376.
- **LEMOORE/HANFORD AREA:** For Sale-General Dentistry Practice & Building. Owner has worked in this location since 1971. Gross Receipts were \$378K with \$139K adj. net income. There are 3 equipped operatories and 3 days of hygiene. Purchase of the building is optional to the Buyer. 100% financing is available for both building and practice. Excellent opportunity for new grad or satellite practice. #14375.
- **LINDSAY:** For Sale-General Dentistry Practice & building. Gross Receipts \$330K with adjusted net income of \$219K. Office space 1,489 sq. ft., 4 equipped operatories, Intra-Oral Camera, Soft-Dent software, 3-hygiene days a week. Owner retiring. #14363
- **MILLBRAE:** For Sale-General Dentistry Practice. This beautiful, well-established office is located on the main thoroughfare of the North Peninsula, offering great exposure that generates 25-30 new patients per month. 5 treatment rooms (6th plumbed) in approx. 1,500 sq. ft. equipped with Digital Pan, Digital Imaging and Intra-Oral Camera. 2011 gross receipts of \$651,000 with \$230,000 adjusted net income. Owner is retiring. Don't delay, this won't last long! #14395
- **MODESTO-TRACY-STOCKTON AREA:** For Sale-Pediatric Practice. \$677,000 in collections in 2010 with a \$357,000 net income. This 3-chair office is located in approximately 1,250 sq. ft & has recently been remodeled. Patient Base software. Office equipped for NO2 & IV sedation. Practice has operated in its present location for 20 years.

CALIFORNIA / NEVADA REGIONAL OFFICE

HENRY SCHEIN PPT INC.

California Regional Corporate Office

DR. DENNIS HOOVER, Broker

Office: (800) 519-3458 Office (209) 545-2491

Fax (209) 545-0824 Email: dennis.hoover@henryschein.com

5831 Stoddard Road, Ste. 804 Modesto, CA 95356

Henry Schein PPT Inc., Real Estate Agents

and Transitions Consultants

Dr. Tom Wagner (916) 812-3255 N. Calif.

Jim Engel (925) 330-2207 S.F./Bay Area

Mario Molina (323) 974-4592 S. Calif.

Thinh Tran (949) 533-8308 S. Calif.

HENRY SCHEIN®

PROFESSIONAL PRACTICE TRANSITIONS



Dr. Dennis Hoover
Western Regional Manager
& Corporate Broker
CA R.E. Lic. #0123804
NV R.E. Lic. #0053890 • NV R.O. Lic. #0000301



Dr. Thomas Wagner
Transitions Consultant
CA R.E. Lic. #01418359



Jim Engel
Transitions Consultant
CA R.E. Lic. #01898522



Thinkh Tran
Transitions Consultant
CA R.E. Lic. #01863784



Mario Molina
Transitions Consultant
CA R.E. Lic. #01423762

- **NEWPORT BEACH:** For Sale-General Dentistry Practice. Practice has operated at its present location since 1986. Located in a highly affluent Newport Beach community. Three (3) hygiene days per week. Leased office space with 4 ops. in 1,450 sq. ft. Pano & Practice Works software. #14354.
- **NORTHERN CALIFORNIA:** For Sale-Endodontic Practice. This Endodontic practice is located in an upscale professional office complex. The owners condominium occupies 1,770 sq ft. There are 4 equipped treatment rooms with an additional 5th room available. Gross Receipts were \$638K with \$239K adjusted net income. Owner will stay for transition to introduce buyer. Owner is retiring. #14251
- **NORTHERN CALIFORNIA:** For Sale-Pediatric practice. Owner has operated in same location for 32 years. Approx 1,760 active pts, 1,160 sq ft panoramic X-Ray, Dexis Digital and Dentrix software in this 5-chair office. 2009 Gross Receipts \$713K with 48% overhead. Owner retiring. Call for Details.
- **NORTHERN FRESNO:** For Sale-General Dentistry Practice. This is a perfect starter or satellite practice. Excellent location in North Fresno. Gross Receipts in 2010 were \$173K. Approximately 450 active patients. 3 operatories. Dentrix software. Leased office 1,200 sq. ft. Owner has been accepted to an Endodontic Residency after starting practice 1 1/2 years ago.
- **NORTH OF SAN FRANCISCO:** For Sale-PERIODONTAL PRACTICE. Owner retiring: Great opportunity for a Periodontist with experience in dental implant placement. This well-appointed practice is located in a 1,300 sq. ft. office with 4 operatories along the busy 101 corridor north of San Francisco. 2011 gross receipts of \$558,000. DSN software. Buyer will be the only full-time periodontist in an area with the population of approximately 60,000. #14396
- **OCEANSIDE:** For Sale-Modern looking office. 4 op, office space and equipment only. Belmont chairs. Gendex x-ray system, intraoral camera approx 1200 sq ft. Low overhead-Rent is \$1,900/month, and it's a 5 year lease. Staff is available for rehire-front desk \$15/hr, assistant 13/hr. Update all the computer systems after purchasing the office in 07. Computers and monitors in every room. #14346
- **PLUMAS COUNTY:** For Sale-3 equipped ops. Space available for 4th op. 1,245 sf office in good location. Gross Receipts \$475K. Practice in present location over 50 years. Owner is retiring. #14318
- **ROSEVILLE:** For Sale-General Dentistry Practice. Great Location. 2009 GR \$900K with an adjusted net income of \$300K. 1,975 sq. ft. with 4 ops, 8 days hygiene/wk. Digital, Intra-Oral Camera, Dentrix, Trojan, fiber optics, P & C chairs - all less than 5 years old. Owner is retiring. #14327
- **SACRAMENTO:** Must be sold immediately. Well-established General Dentistry practice is desirable N. Sacramento location. Office is 1950 sq. ft. with 4 ops, plus fully functional dental lab, porcelain oven, casting, splints) which can be converted into 2 additional ops., Digital x-rays and digital Pan, Practice Works software, 2010 Net receipts \$1,967,047. Don't assume anything about the purchase price. Inquire immediately. Purchase price is totally negotiable.
- **SACRAMENTO:** For Sale-General Dentistry Practice. Gross Receipts \$546K with adjusted net income of \$159K. Office is 2,400 sq ft with 7 operatories. Practice has been operating in the same location for the past 50 years. Pano, Softdent software. Owner to retire. #14374
- **SACRAMENTO/ROSEVILLE:** For Sale-One of many partners is retiring in this highly successful General Dentistry Group Practice. Intra-Oral Camera, Digital Pano-Dexis, electronic charts, owner Financing. Call for further information. #14334
- **SAN BERNARDINO:** For Sale-General Dentistry Practice. GR \$972K. Practice has been in its present location for the past 35 years. Leased 4,500 sq ft of office space- 12 equipped operatories. Dentrix software, Pano and Cerac. Accepts HMO. Multi-specialty practice. Owner to relocate. #14377
- **SAN DIEGO:** For Sale-General Dentistry Practice. 6 ops, Intra-Oral camera, Eagle Soft Software. Office square feet 2,300 with 3 years remaining on lease. 2009 Gross Receipts \$1,448,520, with an adjusted net income of \$545K. Doctor would like to phase out then retire. #14331
- **SAN FRANCISCO:** For Sale-General Dentistry Practice. This 1000 sq. ft. office is located in the heart of the financial district. It is a corner office with each of the 4 operatories looking out at the incredible views on Golden Gate side of the bay. The 2011 collections were \$1,200,000 with a low overhead. The practice averages approximately 15 new patients a month.
- **SAN LUIS OBISPO:** For Sale - Two Doctor General Dentistry Practice. Gross receipts \$1,537,142 for 2010 with an adjusted net income of \$691K. The office has 2,331 sq. ft. with 8 equipped operatories. Pano, E4D, and Dentrix software. Practice started in 1990 and has been in its present location since 1998. Approx. 3000 active patients. Great location with nice views. #14353.
- **SANTA BARBARA:** For Sale-General Dentistry Practice. Wonderful opportunity to live and work in one of California's most desirable areas. 2010 Gross receipts were \$974,000 with a \$370,00 adjusted net income. Six days of hygiene. Dentrix software, Intra-Oral Camera and Panoramic X-Ray. Owner is retiring. #14382
- **SANTA CLARA:** For Sale - BUILDING ONLY: This building is located just west of Westfield Mall and Santana Row. The building has two units. One side is designed and plumbed for dentistry and the other was a law office. There is 3,776 sq. ft. of office space. The dental office is approximately 1,800 sq. ft. with 6 operatories. The building has been recently re-roofed. Excellent opportunity for a startup practice or for the dentist that needs more space. Financing available through various dental lenders. #14368
- **SANTA CRUZ:** For Sale-General Dentistry practice. Gross Receipts \$300K with a 57% overhead. Office is 1,140 sq. ft. 3 equipped operatories. Intra-Oral Camera, Pano, Digital X-Rays, and Dentrix software. Practice has been in its present location since 1980. Owner retiring. #14358.
- **SANTA CRUZ:** For Sale-General Dentistry practice. This excellent practice is centrally located in a professional complex. Office is approx. 1,885 sq. ft. 4 operatories with room for one additional. There are approx. 2000 active patients with 6 days of hygiene per week. Practice Pano, Intra-Oral Camera and Easy Dental software. Owner is retiring. Reasonable lease available. #14361
- **TORRANCE:** For Sale-General Dentistry practice. This excellent practice is centrally located in a professional complex. Office is approx. 1,885 sq. ft. 4 operatories with room for one additional. There are approx. 2000 active patients with 6 days of hygiene per week. Practice Pano, Intra-Oral Camera and Easy Dental software. Owner is retiring. Reasonable lease available. #14320
- **TORRANCE:** For Sale - General Dentistry Practice. Gross Receipts \$413K with an adjusted net income of \$203K. 50% overhead. Practice has been in its present location for the past 25 years. The office has been tastefully remodeled. Office is 800+ sq. ft. with 3 equipped operatories. 4 -hygiene days per week. Doctor is to retire. #14369
- **VICTORVILLE:** For Sale - General Dentistry Practice. This practice is worked just on a three day a week schedule. There are 3 operatories with 10 off-street parking spaces. Practice has high visibility. The practice was acquired from previous owner in 2002. #14393

CALIFORNIA / NEVADA REGIONAL OFFICE



CLASSIFIEDS, CONTINUED FROM 530

implants (optional, if you are not comfortable or certified). We will be expanding to a second office on the Westside of Oahu. There is an opportunity for full-time work in the future. Please email cover letter and CV. New grads welcome IF you are confident, dynamic and do extremely high-quality work. Contact 925-956-2002.

OPPORTUNITY AVAILABLE — Busy children's dental office seeking a female dentist to see children. Must be able to explain treatment thoroughly to parents and be patient to work with children. We are a busy office and we need to add couple of new doctors. A doctor with a Denti-Cal provider number is a plus. Please email your resume to dentalkc@gmail.com.

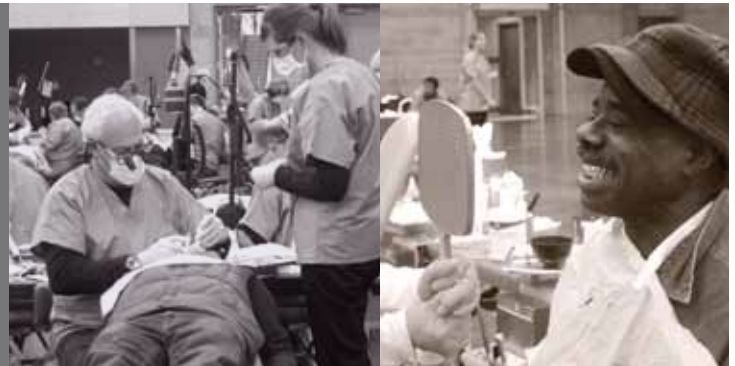OPPORTUNITY AVAILABLE — We are a state-of-the-art dental office located in historic Jackson Square across from the Transamerica Building in downtown San Francisco. We have an experienced and supportive dental team in place. We are looking for a dentist to share our space that is a team player, has great communication skills, and is excited by an office that is geared towards quality as well as growth and expansion. We have room for one more dentist who either has an established following or is looking to develop a general dental practice. If you are confident with your qualifications, passionate, and motivated, we would love to meet you. Please contact 415-776-4133.

OPPORTUNITY AVAILABLE — General dentist needed part-time/full-time in Sun City and Perris, Riverside CA. Minimum 2-3 years experience needed. Strong diagnostic and clinical skills are required including, but not limited to, fixed and removable prosthetics. For immediate consideration, please email your resume to dentalcorp@yahoo.com.

OPPORTUNITY AVAILABLE — Are you looking for a position that will allow you to use all of your skills in a fun, fast-paced environment? Busy Dental practice is seeking an office manager. Full-time position. Associate's Degree in business, or equivalent. At least three years of experience in a dental office is required.

CONTINUES ON 536

We're all part of the solution.



CDA and the CDA Foundation, together with national partner America's Dentists Care Foundation, are launching CDA Cares, free dental clinics to provide oral health services and education to the state's most vulnerable citizens who, for many reasons, lack access to dental care.

Providing treatment to thousands of people in one weekend requires an army of volunteers as well as the generosity of corporations both large and small. We'd like to thank those who understand the need and have stepped up to answer it.

To donate, volunteer or learn more, visit cdfoundation.org/cdacares

cda cares
California Dental Association Foundation
in partnership with America's Dentists Care Foundation



CARROLL & COMPANY

**"MATCHING THE RIGHT DENTIST
TO THE RIGHT PRACTICE"**

Complete Evaluation of Dental Practices & All Aspects of Buying and Selling Transactions



Serving you: Mike Carroll & Pamela Gardiner

3071 MID-PENINSULA GP

Well-established **PENDING** GP in desirable neighborhood. 1,400 sq. ft. facility. Ownership in building available.

3073 LOS GATOS FACILITY

Great location with Beautiful State-of-the-Art Dental Office with 6 fully-equipped ops in approximately 2,000 sq. ft. of a magnificent designed setting. There is one additional private op plumed and ready to go. Equipment includes the 4 chairs, 4 stools, new Vacuum & Compressor, Ultra Sonic, Trash Compactor, large TV in reception area, Spectacular Water Fall in Hall Way and 2 swing through X-Rays. Owner willing to provide long term lease and or options to renew. Asking \$195K.

3072 SOUTH BAY GP

Owner retiring from well est. 4 op GP in desirable commercial/residential mix neighborhood. Highly visible location near well travelled intersection. ~1,300 sq. ft. facility with **PENDING** parking lot, across from shopping plaza. Experienced & well trained, long term staff. 1,400 active patients (all fee-for-service) and 7 full days of hygiene. Ave. GR \$840K+. Owner willing to help Buyer for a smooth transition. Asking only \$503K.

3062 SOUTH BAY OMFS

Established and well-respected OMFS available. Located in desirable professional & residential mix neighborhood 2 blocks from large mall. 1,080 sq. ft. office w/3 fully-equipped ops. Seller preparing to retire. 2010 GR \$377K+. Asking \$240K.

3049 SAN JOSE GP

Well-located, across from O'Connor Hospital, general practice in 2,118 sq. ft. state-of-the-art facility w/ 3 fully-equipped ops. 2 pvt. offices (1 can be plumbed for 4th op). Asking \$195K.

3069 NAPA VALLEY ENDO

Endodontic practice now available in Napa Valley. Gorgeous state-of-the-art 1,450 sq. ft. facility w/4 fully-equipped ops & microscope in every room. **SOLD** Excellent referral sources and upside opportunity.

3059 SANTA CRUZ COUNTY GP & BDG

Charming practice tucked among soaring redwoods in Santa Cruz County. 2010 GR \$595K+ w/3 doctor days. All fee-for-service. Owner retiring and willing to help for a smooth transition. This is a great turn key practice and opportunity to own a hidden gem. Practice asking price \$373K, building is also available.

3064 SAN JOSE GP

Now available. Great turnkey opportunity. Beautiful 1,500 sq. ft. facility with 4 fully equipped ops. State-of-the-art fully networked office, Dentrix software, digital x-ray & recently purchased dental & office equipment. Avg. GR \$328K+ with 4 doctor-days. Owner willing to help in transition. Asking \$220K.

3061 SAN JOSE DENTAL FACILITY

Dental facility ideal for Pediatric or easily converted to GP. Gross lease with utilities included expires July 2013 with 5 year option to renew. **SOLD** Modern, tastefully designed, approximately 1,321 square feet. Asking \$95K.


3067 MID-PENINSULA GP

Gorgeous modern, highly visible GP in 3,000 sq. ft. office w/7 fully equipped ops. Approx. 1,600 active pts. & avg. 16 new pts./month. 4 doctor-days/week. 5 years avg. GR \$991K+. Asking \$808K.

UPCOMING LISTING:

3068 MONTEREY COUNTY GP

2,000 sq. ft. state-of-the-art office w/6 modern, fully-equipped ops. & w/digital x-ray. Long term & loyal staff. Approx. 1,500 active patients all fee-for-service. 3 year avg. GR \$1.7M, 2011 GR on schedule for \$1.8M.



Contact Us:

Carroll & Company
2055 Woodside Road, Ste 160
Redwood City, CA 94061

Phone:

650.403.1010

Email:

dental@carrollandco.info

Website:

www.carrollandco.info

CA DRE #00777682

CLASSIFIEDS, CONTINUED FROM 534

Responsibilities include, but are not limited to, managing office personnel, collections, verifying insurance, verifying eligibility and benefits, obtaining authorizations, keeping the office organized, and managing day-to-day operations of office. Please only email cover letter and resume to shodhandentistry@gmail.com.

OPPORTUNITY AVAILABLE — Established Dental Practice in San Jose is seeking a part time associate. This is a long-term position. Minimum 5 years of experience in delivering treatment is needed. Practice renders dental care six days a week. Services on some Saturdays are required. Basic dental surgery skills and experience in endodontics is needed. Please email resume to IrinaMisra@Gmail.com.

OPPORTUNITY AVAILABLE — Current Endodontist going on maternity leave as of May 2, 2012. Looking for a part-time Endodontist to fill the position for 1-2 days per week for 3 months. Great compensation. Contact 925-680-4444.

OPPORTUNITY AVAILABLE — Get out of the crowded city make great money and get excellent additional training, working with me in my rapidly growing offices. We do all areas of dentistry and pride ourselves on our outstanding gentle care. With over 100 new patients a month we are growing too fast to keep up. We are proving that taking excellent care of patients can bring great dividends. Come work with a great team, with great equipment in our chartless office in the beautiful part of California. Experi-

ence is always helpful, however, as long as you are willing to learn, a lot of experience is not necessary. Contact 530-533-8204.

OPPORTUNITIES WANTED

IN HOUSE PERIODONTIST AND IMPLANT SURGEON AVAILABLE FOR YOUR OFFICE IN THE GREATER SAN FRANCISCO BAY AREA — Implant Surgery/Bone Grafting/Perio Surgery/3rd Molar Extractions/Surgical Extractions; Email: bayareaperio@gmail.com or call 617-869-1442.

OPPORTUNITY WANTED — After over 20 successful years, I sold my upscale, private practice and I am looking to relocate to Southern CA. Let me e-mail you my list of

CONTINUES ON 538

Everything a dentist needs, for less.

You can start saving today. Check out the details at cdaendorsedprograms.com





Professional Practice Sales

Specialists in the Sale and Appraisal of Dental Practices
Serving California Dentists since 1966
 How much is your practice worth??
Selling or Buying, Call PPS today!

**Practices
Wanted**

NORTHERN CALIFORNIA
(415) 899-8580 – (800) 422-2818
Raymond and Edna Irving
Ray@PPSsellsDDS.com
www.PPSsellsDDS.com
California DRE License 1422122

SOUTHERN CALIFORNIA
(714) 832-0230 – (800) 695-2732
Thomas Fitterer and Dean George
PPSincnet@aol.com
www.PPSDental.com
California DRE License 324962

- 6008 MENDOCINO COAST'S FORT BRAGG** 2011 collected \$725,000. 4-days of Hygiene. 4-ops (each with own computer), digital radiography. Great family community.
- 6018 SAN JOSE'S CAMPBELL** Successful practice in esteemed Group. Seller averages net production of \$440,000 (excludes Hygiene), collections of \$430,000 and Profits of \$200,000. Group performs at \$3.8 Million/year level.
- 6020 PEDO PRACTICE - ATTRACTIVE NORCAL FAMILY COMMUNITY** 2011 Collected \$455,000 on 26 hour work week with Profits of \$208,000. 2012 is trending \$600,000. \$230,000 invested here. Beautiful office. Full price \$240,000.
- 6022 SAN FRANCISCO'S NORTH BAY - SEBASTOPOL DENTAL OFFICE** 8 miles west of Santa Rosa. Beautiful office in great family community. Total investment of \$230,000. Asking \$65,000.
- 6023 LOS GATOS - "SOLD"** 2011 collected \$240,000 on 3-days. 6-year office has \$215,000 invested. Adec delivery systems, Adec cabinets, digital radiography, digital Pano and paperless charting.
- 6024 PERIO PRACTICE – SAN FRANCISCO'S SOUTH BAY** Collected \$600,000 in 2011 on 19-hour week with 7 weeks off. Great second office or excellent base to build upon.
- 6025 CENTRAL MARIN COUNTY** Well established, collected \$490,000 in 2011 on 3-day week. 3-Ops. 2+ days of hygiene.
- 6026 SACRAMENTO** Collected \$825,000 on 3-day week with no marketing. Great foundation which could be developed into a busier practice.
- 6027 PLEASANTON** Well cared for practice with conservative Owner. Collected \$500,000 with Profits of \$260,000 in 2011. Office remodeled 3-years ago at cost of \$60,000. Beautiful!
- 6028 BERKELEY'S ALTA BATES MEDICAL VILLAGE** 2011 collected \$525,000. Collections first 4-months of 2012 totaled \$210,000. 3-chair office. Busy Hygiene schedule.

- 3193 PALM DESERT** Grossing \$400,000+. Great Location.
- 3237 ANAHEIM HILLS** Solo group member wanted-Hi-identity-HiTech share beautiful space.
- 3250 ANAHEIM** NW Disneyland. Part time Seller. 2 days wk. Hi identity corner. Grossing \$370K in '09. 1,800 sq. ft. 5 Ops equipped. Low rent.
- 3283 PALMDALE/LANCASTER** Hi growth area. GP Gross \$1.5 mil. 40% Net. Small town! 5 min from Bakersfield. RE available.
- SMALL TOWN** Minutes from Bakersfield. Modern RE. Practice Grosses \$20-to-\$40K per month. Bargain.
- APPLE VALLEY/HESPERIA** Gr \$700 to \$800 Free Std Bldg Avail Absentee.
- 3287 SOUTHERN CALIFORNIA - "SOLD"** \$6 Million per year. Prestigious Hi identity location. 12,000 sq.ft. \$1.00/sq.ft. \$30K Cap/mo. Requires substantial net worth. Nets \$1+ Million.
- 3290 SANTA PAULA, NEAR FILLMORE** Hi identity location. Gross \$400,000+. Established 2006. 5-ops, 3 equipped. Beautiful office. Steady growth.
- 3297 SOUTH BAY** Location Only. Free standing Dental bldg on main street.
- TEMECULA/HEMET HMO.** Gr. \$700,000 part time. 8 ops fantastic location Million Dollar corner. Full Price \$565K.
- ORANGE** Grosses \$30K+/mth. 5 ops. Beautiful. Rent \$2,000. FP \$250K.
- HEMET/TEMECULA HMO.** Absentee owner. Grosses \$700K. PPS says Buyer will do \$1.5 Million within 18 months. Special Situation.
- TORRANCE** Special Diamond Location. Hi Identity. Will Gr \$500K first year. \$125K FP.
- VICTORVILLE-APPLE VALLEY-HESPERIA AREA** Estb 20 yrs. Gr \$700K+. Net approx \$300K. More vol avail. 8 op. Hi identity shop ctr. FP \$650K. Serious Seller. Can do \$1 Million.
- SANTA ANA** Super Hi identity intersection. 50,000 to 75,000 auto/day. 5 ops. Grossing \$40-to-\$60K/mth. Net \$200,000 to \$300,000. Great opportunity to build Million Dollar office here.
- LANCASTER** Estb 50 years - Hi identity central location, low overhead. Gross \$480,000 by part time owner. Seller can work back per new owner. Five operatories.
- ORANGE COUNTY** Beautiful office. Right buyer will gross \$2 million first year. Financing in place. Need Entrepreneur who has team of specialists in place or Dentist with multiple talents. HMO/PPO/Ins/Cash. Includes 9 days hygiene. 10,000 charts. As stated, right team will do \$2 million first year.
- BEVERLY HILLS** Implant Center \$1,450,000; 3 ops - 1,450 sq.ft. Beautiful facility access to neighbors CT Imaging Center. Full price \$995,000 a bargain - BH most prestigious Dental building. Pride of ownership - Pros would work back for transition. Moving to Desert.
- HAWAIIAN GARDENS** Hispanic practice. Grossing near \$500,000. Beautiful 5 ops in shopping center.
- TEMECULA - HEMET** Grosses \$700,000 part time. 8-ops. Million dollar location.
- CORONA HMO** Gross \$70-to-\$80K month absentee. Low overhead.
- MARINO VALLEY** Gross \$600K. Beautiful office. Low Overhead. Absentee Owner.
- SAN FERNANDO VALLEY** \$1,000,000 opportunity to do \$2,000,000. Very valuable R.E. Hi identity. Rent or purchase R.E.
- APPLE VALLEY CLASSIC** \$600,000+. Low overhead.

**SELL YOUR ORANGE COUNTY OR LA PRACTICE
 GROSSING \$500K AND ASK PPS FOR A PRACTICE
 NETTING \$500K OR MORE.**

****FOUNDERS OF PRACTICE SALES****

115+ years of combined expertise and experience!
 3,000+ Sales -- 10,000+ Appraisals

****CONFIDENTIAL****

PPS Representatives do not give our business name when returning your calls.

****BUYERS AND SELLERS SAY****

**"We have dealt with other firms -
 we like YOUR professional expertise.**

We will recommend YOU to all our colleagues. Thank you."

CLASSIFIEDS, CONTINUED FROM 536

advanced CE courses I have attended, as well as testimonials and photos from my previous patients. This will let you get to know a little bit about me, as well as the high quality of restorative and cosmetic dentistry I can provide. I have an excellent chair side manner; my patients and staff really know I care. I have my CA license, and can quickly be wherever needed when the right opportunity arises. I am looking for a long-term relationship in a high quality, patient centered office. Email tamjag@aol.com or call 949-922-5987.

SEEKING ASSOCIATE POSITION IN SF/ BAY AREA — Experienced in all phases of dentistry, great chair side manner, highly motivated and production driven. Please contact for CV. Email bariennejaddmd@aol.com or call 858-583-4627.

OPPORTUNITY WANTED — Seeking dental insurance company auditor position. I have over 40 years clinical experience and over 2 years of quality control auditor experience for a multi-state dental insurance company. References available upon request. All licenses are current. Contact jc4usc@verizon.net or 626-335-6550.

PRACTICES FOR SALE

PRACTICE FOR SALE — Beautiful practice for sale just blocks from Kai'mana Beach in the Diamond Head area of Honolulu. This is a very exclusive area. Huge patient base with 5+ walk-ins scheduling each day with visible location. Contact me to discuss confidentiality agreement before I give you more information at 925-956-2002.

PRACTICE FOR SALE — Coastal Pismo Beach, 5 cities practice. Excellent location with high visibility. Over 37 years of goodwill. Collections in 2011 of \$1.1 Million, production \$1.4 Million, no HMO's, FFS and insurance. Attractive remodeled 2,000 sq. ft. with 4 ops fully equipped and 2 more available. Pano, upgraded digital X-rays, going paperless, Laser. Located in small shopping center with lots of foot traffic and walk-ins. 75 NP's/month, average 4.5 days/week. Owner retiring. Contact 805-709-6117 or gethealthy528@yahoo.com.



PRACTICE SALES AND LEASING



Paul Maimone
Broker/Owner

GOOD TO SEE YOU @ THE CONVENTION. THANKS FOR STOPPING BY!

ANTELOPE VALLEY — (7) op comput. G.P. in a free stand bldg. Bldg. also available. Newer eqt., digital x-rays, Annual Gross Collect \$1.5M. Cash/Ins/PPO pts. 20-30 new pts/mos. **NEW BAKERSFIELD #21** - (10) op G.P. & Bldg. on a main St. (3) ops fully eqt'd. (3) ops part eqt'd & (4) add. plumbed. Store front. Collects ~\$500K/yr. Cash/Ins/PPO/<1 % Denti-Cal. **REDUCED COVINA #2** - (4) op comput. G.P. (3) ops eqt'd/ 4th plumbed. 2011 Gross Collect ~ \$220K on a 2 day wk. Mixed patient base. **REDUCED AGAIN! BRING ALL OFFERS!**
COVINA #3 - (3) op comput. G.P. Cash/Ins/PPO. Gross Collect \$242K+ on an easy (3) day wk. Located in a small prof/medical/dental bldg. w off street parking. Seller retiring. **SOLD**
GLENDORA - (3) op comput. G.P. Cash/Ins/PPO very small % Denti-Cal pt. base. Very low overhead office with a very high % net. 2011 Gross Collect \$296K+. Seller moving. **REDUCED HACIENDA HTS.** - (2) op G.P. in a Shop Ctr. Cash/Ins/PPO. 2011 Collect \$164K p.t. **NEW L.A. (SILVERLAKE - ATWATER)** - (3) op G.P. located in a centrally located retail store front w exposure. (28) years of Goodwill. Cash/Ins/PPO. Gross Collect \$140K p.t. **SOLD**
NEWPORT BEACH - (5) op comput. G.P. 4 ops eqt'd/5th plmbd. In a prof. bldg. on the Marina. Cash/Ins/PPO small % cap. Dentrax & Shick. Collects \$400K+ on a (2) day wk.
NORTHRIDGE - (6) op comput. G.P., (5) ops eqt'd. (6th) partially eqt'd. In a remodeled prof. bldg. Cash/Ins/PPO/HMO pts. Approx. \$3K/mos in cap cks. Annual Gross Collect \$400K+. **NEW OXNARD #6** - Turnkey w charts. (4) ops/3 eqt'd Comput/networked/digital. Gorgeous! **NEW PORT HUENEME #1** - (3) op comput G.P. in a Strip Ctr w exposure. Cash/Ins/PPO & small % HMO. Collect \$220K/yr p.t. No advert. Associate run. Owner/Operator can do better. **SOLD**
PORT HUENEME #2 - Turnkey w charts. (4) op/3 eqt'd. G.P. Digital. Strip Ctr. **REDUCED RESEDA #6** - (3) op comput G.P. located in a prof. bldg. Gross Collect. ~ \$150K/yr p.t. Cash/Ins/PPO pts. Digital X-rays & Dentrax. Great starter or 2nd office. **BRING ALL OFFERS**
RIVERSIDE - Clean & well maintained (3) op G.P. in a Shop. Ctr. Retiring DDS works (2-3) relaxed day/wk. Cash/Ins/PPO small % Denti-Cal. Annual Gross Collect \$180K. **PENDING SANTA BARBARA #3** - (3) op comput. G.P. in a prof/med/dental bldg. Cash/Ins/PPO. 8-10 new pts/mos. Gross Collect. \$250K+ on a (4) day wk. Digital x-ray. Seller retiring. **REDUCED So. TULARE COUNTY - PORTERVILLE AREA** - (6) op comput. G.P. in a major Shop. Ctr. Exposure/visibility/signage. Cash/Ins/PPO/Kids Denti-Cal pts. Gross Collect. \$500K+/yr. **NEW UPLAND #3** - (5) op comput G.P. & Specialty Pract. in a free stand bldg. Gross Collect \$525K-\$625K/yr. Digital x-ray. Excell opp. for G.P. who likes to do Endo. **BACK ON MARKET**
UPCOMING PRACTICES: Anaheim, Beverly Hills, Camarillo, Corona, Montebello, Northridge, Panorama City, Pasadena, SFV, San Diego, Thousand Oaks, Torrance, & Vista.

D&M SERVICES:

- Practice Sales and Appraisals
- Practice and Equipment Financing
- Expert Witness Court Testimony
- Pre - Death and Disability Planning
- Practice Search & Matching Services
- Locate and Negotiate Dental Lease Space
- Medical/Dental Bldg. Sales & Leasing
- Pre - Sale Planning

P.O. Box #6681, WOODLAND HILLS, CA. 91365

Toll Free 866.425.1877 Outside So. CA or 818.591.1401 Fax: 818.591.1998

www.dmppractice.com CA DRE Broker License # 01172430

CA Representative for the National Association of Practice Brokers (NAPB)



LEE SKARIN
AND ASSOCIATES

Dental Practice Sales

QUESTIONS MOST OFTEN ASKED BY . . .



... SELLERS

1. Can I get all cash for the sale of my practice?
2. If I decide to assist the Buyer with financing, how can I be guaranteed payment of the balance of the salesprice?
3. Can I sell my practice and continue to work on a part-time basis?
4. How can I most successfully transfer my patients to the new dentist?
5. What if I have some reservation about a prospective Buyer of my practice?
6. How can I be certain my Broker will demonstrate absolute discretion in handling the transaction in all aspects, including dealing with personnel and patients?
7. What are the tax and legal ramifications when a dental practice is sold?

... BUYERS

1. Can I afford to buy a dental practice?
2. Can I afford not to buy a dental practice?
3. What are ALL of the benefits of owning a practice?
4. What kinds of assets will help me qualify for financing the purchase of a practice?
5. Is it possible to purchase a practice without a personal cash investment?
6. What kinds of things should a Buyer consider when evaluating a practice?
7. What are the tax consequences for the Buyer when purchasing a practice?



Lee Skarin & Associates, Inc.
Offices

CA DRE #00863149
(805) 777-7707
(818) 991-6552

1800-SKARIN#1
1-800-752-7461

LEE SKARIN & ASSOCIATES gives straightforward answers to these important questions as well as others you may have – by phone or in person – **without obligation!**

Lee Skarin & Associates have been successfully assisting Sellers and Buyers of Dental Practices for nearly 30 years in providing the answers to these and other questions that have been of concern to Dentists.

Call at anytime . . . for a no obligation
response to any or all of your questions.
GO AHEAD AND CALL – IT'S PAINLESS!



LEE SKARIN
AND ASSOCIATES

ADVERTISER INDEX

California Practice Sales	calpracticesales.net	528
CariFree	carifree.com	488
Carroll & Company Practice Sales	carrollandco.net	535
CDA Membership	cda.org/member	471
CDA Practice Support Center	cdacompass.com	468-469
D&M Practice Sales and Leasing	dmpractice.com	538
Dental Choice	dentalchoice.ca	508
Golden State Practice Sales	925-743-9682	530
Implant Direct	implantdirect.com	495
Keller Laboratories	kellerlab.com	496
Lee Skarin and Associates, Inc.	leeskarinandassociates.com	539
Maddox Practice Group	maddoxpracticegroup.com	518
Misch Implant Institute	misch.com	482
Professional Practice Sales of the Great West	415-899-8580	537
Professional Practice Transitions	pptsales.com	532-533
Select Practice Services, Inc.	betterobin.com	543
The Dentists Insurance Company	tdicsolutions.com	458, 464
TOLD Partners, Inc.	told.com	529
Ultradent Products	ultradent.com	544
Herman Ostrow School of Dentistry of USC	jobs.usc.edu	463
Western Practice Sales/John M. Cahill Associates	westernpracticesales.com	487, 517, 531

FOR ADVERTISING INFORMATION, PLEASE CONTACT COREY GERHARD AT 916-554-5304.

DR. BOB, CONTINUED FROM 542

French! Of course, you would have been required to outbid a private collector in London who picked up the artifact for a mere \$22,600 (USD). Somewhere in the world are 31 other Napoleon teeth and as any fervid collector knows, what goes around, comes around. Keep an open wallet!

More recently, eBay was the scene of a mad bidding war over a purported tooth of Elvis Presley's, halted only when the bidding rose to more than \$1 million in a matter of hours. The fact that the "tooth" was nothing more than a common porcelain crown with no Presley root attached may have had a bearing. In this case, the provenance might be worth more than the artifact.

Meanwhile, up in Canada, a dentist named Michael Zuk, successfully bid \$31,200 for a tooth of John Lennon's. From the photo of it that was featured all over the Internet, Lennon was lucky to get rid of it at any price. If John had foreseen this intraoral gold mine, he could have netted a cool \$1 million from the balance of his dentition before his untimely demise.

The point is, this marketing of human body parts has got to stop somewhere. The payment for good quality human blood has been accepted for years. Viable hearts have been exchanged successfully for undisclosed prices, as have kidney and partial liver donations. If your face starts giving the lie to your claimed age, you can get a refurbished one that's worse for the price of an Aston Martin DBS Volante.

According to *Time*, the sovereign state of Pennsylvania was planning on paying organ donors \$300 toward funeral expenses. Donate an organ of your choice in prime condition, die and the funeral home and your relatives can wrangle over who gets the cash.

Detractors understandably feel this devaluates the human body into a spare parts commodity. They may be right. *Time* points out, "that everything in life that is risky or bad disproportionately affects the poor."

The well-established organ donor program has, up till now, only accepted organs from the recently deceased. What's to stop a needy person who is not officially dead, *Time* postulates, from peddling a kidney for \$5,000 or a major slice of his or her liver?

Needy person: How much you give me for this left arm? Hardly been used. I'm right-handed, you know.

Organ Depot: Low Blue Book on a left arm is \$1,625. Throw in the Rolex knock-off that's on it and we'll make it \$1,650.

AW: Deal!

We leave the morality of this scenario up to you. The thing is, we have this jar of perfectly good extracted teeth — some of them, anyway — waiting for a fresh-

man dental student to pick up for practice preps. The rest of them could be patched up into more or less serviceable organs of mastication, especially if your diet is tofu based. It seems to us that the people responsibly implanting chunks of titanium into human jaws could, if they just tried, figure a way of getting our previously owned teeth back into service.

If that is a premature expectation, perhaps Sotheby's or eBay might be interested in the very good chance that one or more of these teeth could have formerly been used to smile or eat by a precelebrity who just hasn't hit the charts yet. Postpaid, including Mason jar ... \$10,000.



Missing a Journal?

All issues back to 1998
are available at cda.org

No password required.



Celebreteeth for Sale



To dentists submerged in teeth all their professional lives, a tooth is a tooth, is a tooth.

Robert E.
Horseman,
DDS

→ ILLUSTRATION
BY VAL B. MINA

What do Napoleon, Elvis Presley and John Lennon have in common other than the fact they were all males who donned their pants one leg at a time?

Only one of them wore a comical hat, was acclaimed Empereur des Francais and met his waterloo coincidentally at Waterloo. One of the others suffered a chronic pelvic dysplasia and was crowned King of Rock & Roll; the remaining one wore round, steel-rimmed spectacles and considered himself as Le Spouse de Ono. Two of them played guitars and needed haircuts; the same two appeared separately in motion pictures and graced "The Ed Sullivan Show" during which adolescent girls routinely lost consciousness.

The cohesive factor is they were all celebrities and are now deceased, having left the stage, if not the spotlight, at the ages of 51, 42 and 40 respectively. This means that to a certain section of the populace, anything these gentlemen wore, sat in, slept upon, ate or drank from, whether in mint condition,

or salvaged from a rubbish bin is a priceless *object d'art* to be possessed at any price.

Obviously, the more personal the artifact, the more valuable. To dentists submerged in teeth all their professional lives, a tooth is a tooth, is a tooth. But a celebrity tooth, even one in a frightful state of preservation, is quite a different bouillabaisse. Imagine the pride of possession of an actual tooth over which once sluiced a succulent ragout one riotous night at Graceland, one that formerly graced the chops of someone famous enough to be ridiculed on *Saturday Night Live!*

In 2005, a scramble to acquire one of Napoleon's teeth occurred at an auction, attracting aficionados from as far away as New York! This was a tooth that participated in a humiliating failure by its owner to invade Russia. It could have been yours; how much better than an autograph you can't even read because it's inscribed in

CONTINUES ON 541

Dental Practice Sales & Transitions

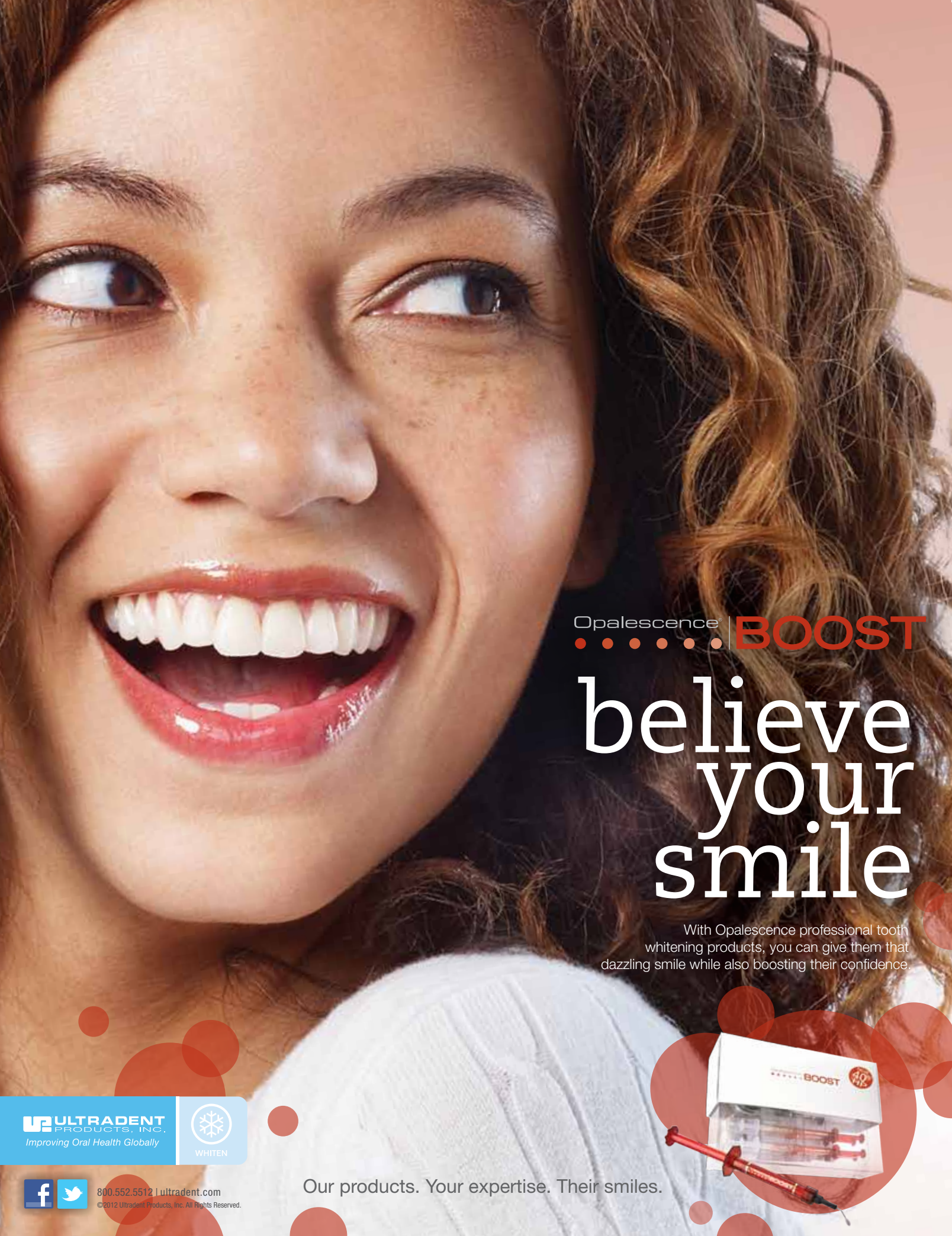

BETTE ROBIN, DDS, JD
DENTIST • ATTORNEY • BROKER

Loma Linda Dental 83 Southwestern Law 95



Select Practice Services, Inc.
Dental Practice Sales and Transitions
877.377.6246 • www.BetteRobin.com
17482 Irvine Blvd., Ste. E • Tustin, CA 92780



Opalescence | **BOOST**

believe your smile

With Opalescence professional tooth whitening products, you can give them that dazzling smile while also boosting their confidence.



ULTRADENT
PRODUCTS, INC.
Improving Oral Health Globally



WHITEN



800.552.5512 | ultradent.com

©2012 Ultradent Products, Inc. All Rights Reserved.

Our products. Your expertise. Their smiles.