

Interdisciplinary Treatment Planning and Digital Workflow Integrating Digital Smile Design and Orthodontic Aligners: *A Case Report*

Rafael de Liz Pocztaruk, PhD
Newton Sesma, PhD
Karina Pinfaudi Amorim, DDS
Christian Coachman, DDS, CDT

Abstract

An interdisciplinary approach in dentistry is important for comprehensive, complete, and effective patient care because patients are becoming more discriminating, increasing demands for more accurate diagnoses and more detailed treatment plans. The clinical report presented here describes an esthetic rehabilitation using a digital smile design protocol for diagnosis, planning, and execution with a fully digital workflow and performed by an interdisciplinary team. At the first clinical appointment, all examinations, photographs, and videos required for the facially guided smile plan were obtained. With this information, the need for an interdisciplinary team to carry out the rehabilitation, which involved clear orthodontic aligners (Invisalign) as well as periodontal and prosthetic treatment, was verified. The final project planned by the team was forwarded to a digital planning center that transformed the 2D design into 3D and made guides for all stages of the treatment. These procedures and the use of a digital workflow made the treatment more predictable and reliable, and the result of the treatment was directly related to the planning and execution integrating all the specialties involved.

Key Words: computer-aided design, crown lengthening, dental technology, veneers, orthodontics, periodontology, prosthodontics

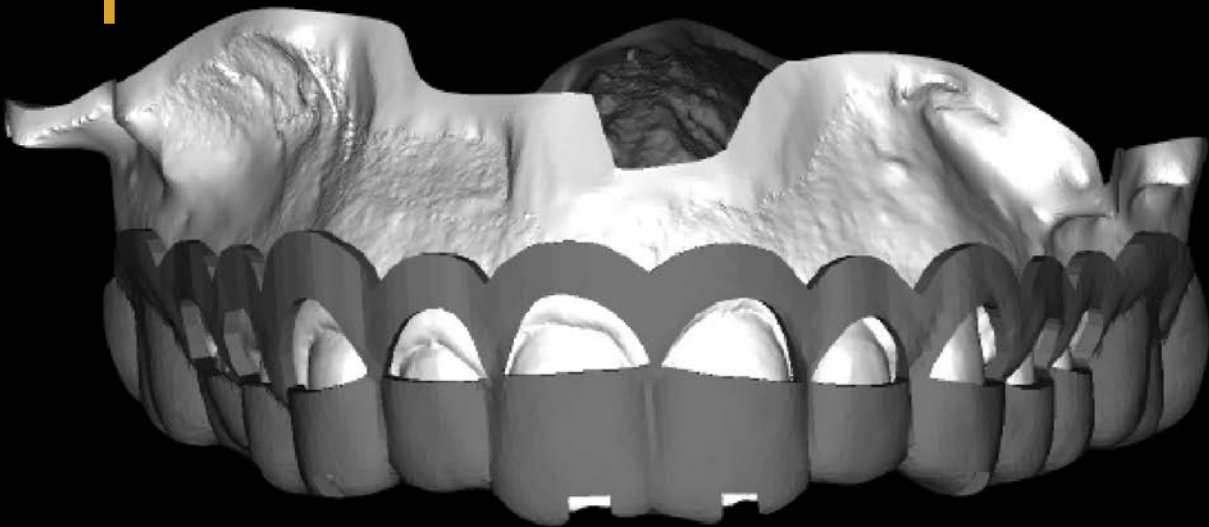


Learning Objectives

After reading this article, the participant should be able to:

1. Understand the key benefits of using an interdisciplinary team and improving communication among team members with the use of a digital planning center and digital workflow.
2. Understand the process of transforming a 2D design into a 3D design for making guides for all stages of a multidisciplinary treatment plan to make the treatment more predictable and accurate.
3. Understand the use of defined planning to simulate the treatment outcome as a motivational and instructional patient tool.

Disclosures: The authors did not report any disclosures.



|| Thus, a preresorative orthodontic treatment guided by the smile design will allow simulations of treatment integrated with the face and with dental movements to make dental preparations less invasive and preserve the dental structure. ||

||| *A mock-up presentation was prepared for several analyses, such as for whether the occlusion would interfere with the trajectory of the anterior guide.* |||

Introduction

An interdisciplinary approach must be implemented in dentistry because of the increasing complexity of the skills and knowledge necessary to effectively provide patients with care.¹ This approach is extremely important to ensure a correct diagnosis, expand treatment options, and attain a higher quality of the work.² Thus, a team composed of different specialties in which each member contributes their knowledge and skills to solve problems, diagnose patients' conditions, and plan and execute therapies must be organized.³

Highly organized communication among team members is necessary for all aspects to be equally expressed and interpreted.⁴ Technological resources such as the digital smile design (DSD) protocol facilitate dialogue among professionals who are members of the team and between professionals and patients^{5,6} so that everyone involved in the treatment follows the same project and has the same ultimate goal.

Facial analysis and facial references are extremely important components of smile design because they guide the rehabilitative treatment.⁷ These references must be in accordance with esthetic principles,⁸ as they are directly related to better facial harmony.^{9,10} DSD utilizes facial references to guide the dental design. In addition, a comprehensive approach to rehabilitative planning and treatment provides results with higher levels of esthetics and function and thus patient health.⁹

Based on this information, orthodontics is a specialty in dentistry that can contribute to more effective patient treatment.¹⁰ By combining the advantages of digital resources¹¹⁻¹³ with the advantages of orthodontic aligners such as Invisalign (Align Technology; San Jose, CA),^{14,15} treatment plans can be visualized through ClinCheck software, which predicts the possible movements that the aligners will perform. Thus, a prerestorative orthodontic treatment guided by the smile design will allow simulations of treatment integrated with the face and with dental movements to make dental preparations less invasive and preserve the dental structure.

Through facial and dental analyses, it is possible to combine photos (jpeg files), digital models (STL files), and cone beam computed tomography (CBCT) (DICOM file) to simulate the final result and carefully observe possible limitations or risk factors by using interdisciplinary planning software integrated into the digital orthodontic, periodontal, and restorative planning.

This case report describes an interdisciplinary treatment plan with a comprehensive approach to esthetic rehabilitation. It demonstrates a facially guided treatment using DSD and clear orthodontic aligners, crown enhancement, and ceramic laminates, all performed within a digital workflow.

Case Report

The patient, a 32-year-old woman in good general health, was referred to a dental clinic specifically for esthetic rehabilitation. She was dissatisfied with a nonesthetic smile, specifically with the size and cant of the teeth and the gingival smile. She requested ceramic veneers. A complete examination was performed, including radiographic, clinical, film, and photographic examinations, and the DSD protocol was performed with initial documentation (Figs 1 & 2).

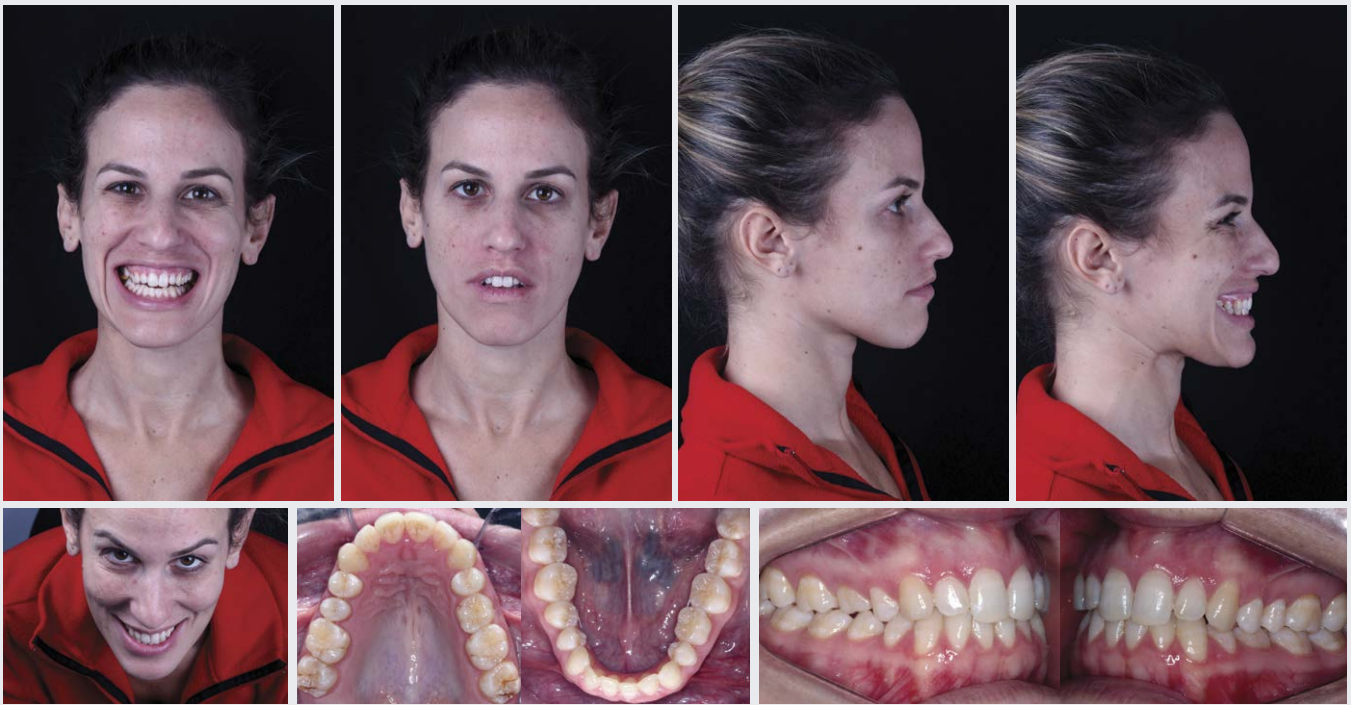

Figure 1: The pretreatment situation. Frontal view of patient's smile and lips at rest; facial profiles with lips at rest and smiling. Patient at 12 o'clock position. Maxillary and mandibular arch occlusal views; intraoral left and right lateral views.

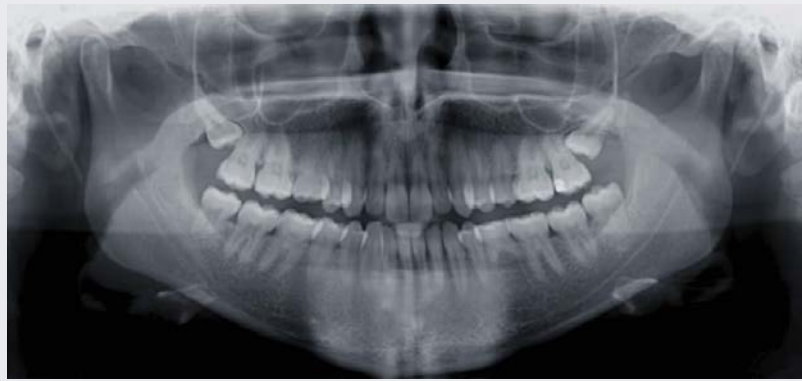

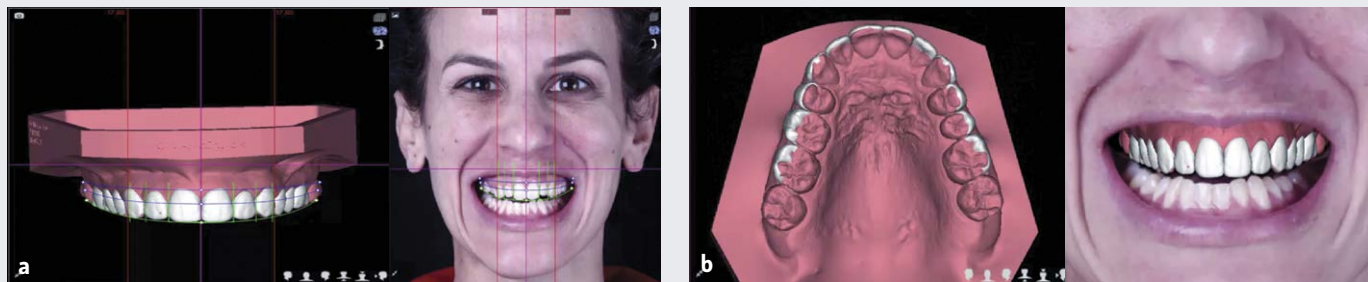
Figure 2: Pretreatment panoramic radiography.

Analysis & Diagnostics

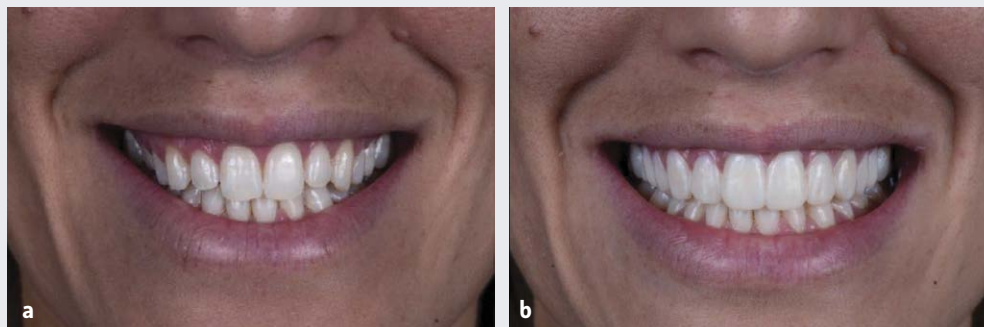After examination by all team members and observation of facial references to guide the patient's new smile design, and taking into consideration the patient's good periodontal status, the need was identified for an interdisciplinary approach including orthodontic and periodontal (crown lengthening) treatment and prosthetic rehabilitation. As part of the treatment, orthognathic surgery was also proposed to the patient; however, she did not consent to this or to having conventional orthodontic treatment performed, which led to the team changing the plan.

Communication

DSD was then performed in 2D for treatment predictability and for better communication among the team members and the patient. The smile design project was sent to the planning center (DSD Planning Center; Madrid, Spain). With the help of NemoSmile Design software (Nemotec; Madrid, Spain), a virtual wax-up guided by the 2D drawing was performed on the 3D digital model (Figs 3a & 3b), and the functional analysis of overbite was made in the virtual articulator within the software. This STL file was printed with a 3D printer (Form 2, Formlabs; Somerville, MA). For this model, a silicone barrier was fabricated for making a motivational mock-up with bis-acrylic resin to present to the patient for her final approval (Figs 4a & 4b).



Figures 3a & 3b: Frontal views of facial reference lines, dental reference lines, and smile design model. Occlusal view of the new smile design model and enlarged view of smile with the new smile design.



Figures 4a & 4b: Test of new smile design in the mouth with motivational mock-up through a barrier of silicone and bis-acrylic resin. Frontal views before and after the mock-up.

Diagnosis

The patient was diagnosed with the need for orthodontic movements to be performed using clear orthodontic aligners (Invisalign), crown lengthening, and veneer restorations. A mock-up presentation was prepared for several analyses, such as for whether the occlusion would interfere with the trajectory of the anterior guide. The mock-up was presented to the patient, and she was given explanations about all the planning and all the necessary observations regarding possible difficulties, such as some orthodontic movements, misalignment of the upper and lower midlines, possible occurrence of ankylosed teeth, and third molar extractions, as well as treatment time, sequence, and value. After all the analyses and the conversation, the patient accepted the treatment plan.

Treatment

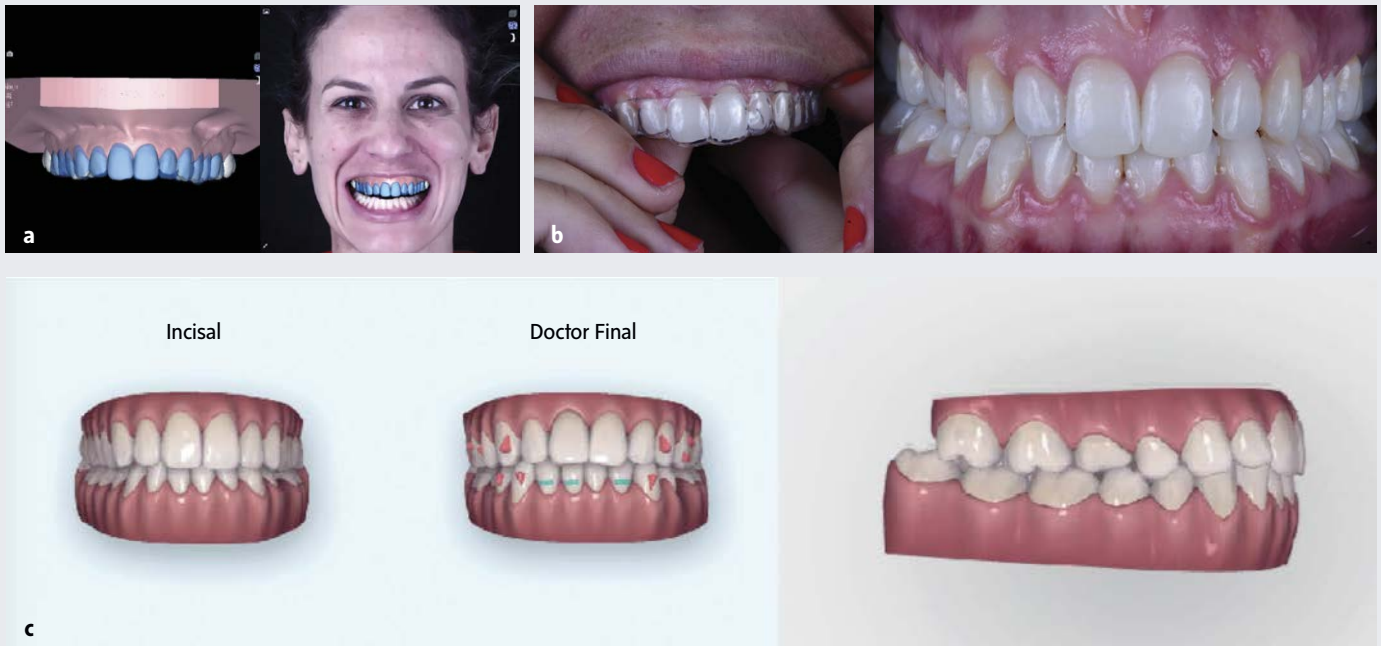Orthodontics

Thus, rehabilitation began with orthodontic treatment (Figs 5a-5c). The DSD project for orthodontic movement guided by the smile design was carried out through collaboration between ClinCheck software and NemoSmile Design. A total of 22 aligners were used to complete the orthodontic treatment. The purpose of the treatment was to expand the arches and align the teeth with consideration to the final restorations.

Then, a minimally invasive preparation would be performed to receive the veneers. To accelerate the orthodontic movement and reduce the treatment time,^{16,17} a technique introduced by Murphy¹⁸ in 2006 was performed. The micro-osteoperforation procedure (Excellerator RT, Propel Orthodontics; Milpitas, CA), which consists of bone perforations, was performed. The purpose of this type of procedure was to induce inflammatory markers such as chemokines and cytokines, which are responsible for osteoclast recruitment, bone remodeling, and osteoclast maturation in the area.^{16,17,19} Thus, the procedure allowed the patient to change aligners every three days. On conclusion of the orthodontic treatment, digital quality control was performed to evaluate whether the aligner treatment objectives had been reached. This was done by superimposing the images from the initial file onto the postorthodontic treatment file with ClinCheck.

Periodontal Procedures

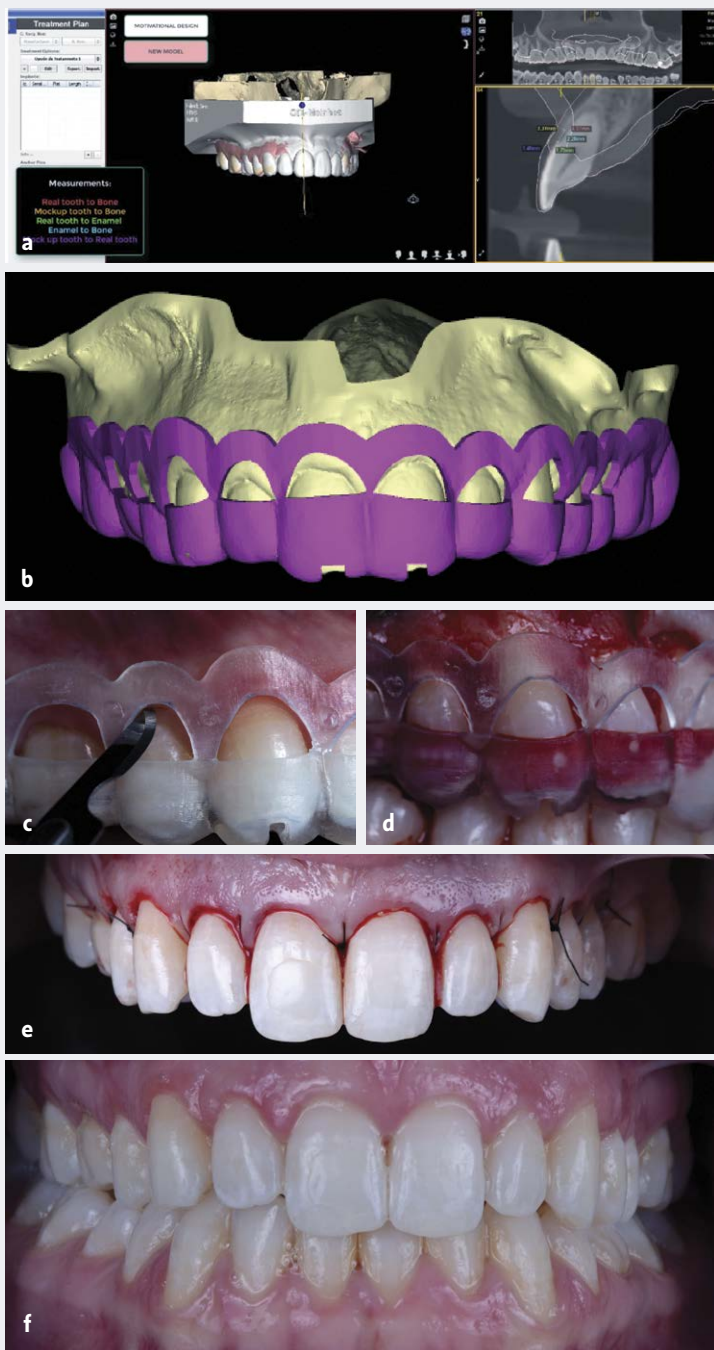
After orthodontic treatment, considering that the patient had good periodontal status with a maximum probing depth of 3 mm and no bleeding on probing, the periodontal treatment began. For crown lengthening, the planning center used the perio analysis tool of the NemoSmile Design software. The CBCT image was superimposed onto the STL file of the virtual wax-up model; thus, it was possible to define the ideal gingival level



Figures 5a-5c: Planning the result of orthodontic treatment with clear aligners via facially guided alignment and verifying with software. Patient placing the aligner in position. Intraoral view after orthodontic treatment.

because the wax-up was based on the facially guided digital design. The bone level was defined from the future gingival level for the purpose of maintaining the biological space; thus, a digital guide for the dual technique was created for use during surgery. This guide provided references for the gingival (bottom of the guide) and bone (top of the guide) levels and thus provided an acceptable reference for maintaining the biological space (Figs 6a-6f). The guide was printed with a 3D printer (Form 2), making the surgery more predictable. Gingivectomy and bone reduction for crown lengthening were performed. Even with the increase in the clinical crown length, the patient still presented a gingival smile, as foreseen in esthetic planning. The patient was presented with the possibility of using botulinum toxin (Botox, Allergan; Dublin, Ireland) to paralyze the muscles; however, the results of this treatment last for a maximum of six months, and the patient would need to have applications at least two times per year to maintain the results. The patient agreed to this treatment, and a controlled quantity was then used to minimize the mobility of the upper lip elevator muscles, consequently minimizing gingival exposure in the broad smile.²⁰

|| To accelerate the orthodontic movement and reduce the treatment time,^{16,17} a technique introduced by Murphy¹⁸ in 2006 was performed. ||



Figures 6a-6f: CBCT image for periodontal treatment planning superimposed onto the virtual model with virtual wax-up of tooth #8, with measurements for gingivectomy and osteotomy (demarcation levels denoted using the lower and upper part of the guide, respectively). Intraoral view immediately after crown lengthening surgery and of the crown lengthening result.

Restorative Steps

After the 90-day period of gingival stabilization after surgery,²¹ restorative treatment began. For precise and predictable execution, the planning center forwarded the motivational mock-up STL file and two other STL files for two different situations. One of these two files guided the dental preparations, called the ideal pretreatment STL, and the other guided the final rehabilitation, called the ideal posttreatment or technical STL, which could be used for the provisional and the final prostheses. Thus, a model was printed, and a silicone index was made from the ideal pretreatment STL. A mock-up was made of bis-acrylic resin to guide the dental wear. Thus, a minimally invasive preparation that preserved tooth enamel was performed (Figs 7a-7d).²²

After this, a digital scan (iTero, Align Technology) of the preparations was performed. The ideal posttreatment STL was superimposed onto the STL of the preparations to guide the CAD production of the laminated veneers (Zirkonzahn; Gais, Italy). Lithium disilicate HT BL1 blocks (IPS e.max CAD, Ivoclar Vivadent; Schaan, Liechtenstein) were milled on the Zirkonzahn M1 wet milling machine (Zirkonzahn). The parts and the teeth were prepared in accordance with the manufacturer's instructions, and cementation was performed with RelyX Veneer cement B 1/2 (3M ESPE; St. Paul, MN), controlling the moisture and avoiding contamination. The occlusion was evaluated, excess cement was removed, and polishing was performed.

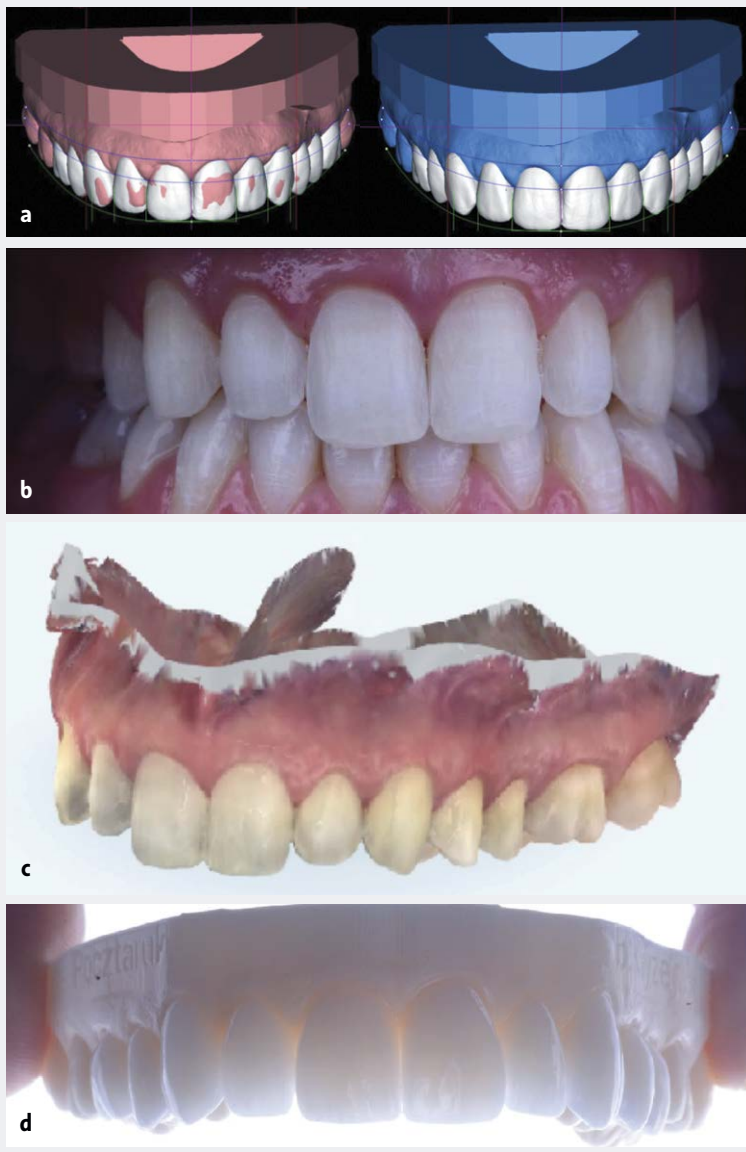
The case was completed, and the patient was satisfied with the result (Figs 8a & 8b). The patient received necessary postoperative instructions, and follow-up assessments were made the following week, the following month, and then at least once a year.

Discussion

Digital Technology

The implementation of digital technology is advancing in dentistry. The conventional workflow has been replaced by the digital workflow because the latter is more efficient.^{12,13} In addition, computers and a digital workflow make jobs easier, faster, cheaper, and more predictable.^{11,13}

Following the digital workflow concept, a DSD protocol was used to guide the plan digitally, integrating all facets of the treatment. Subsequently, the project was forwarded to a digital planning center (DSD Planning Center) to ensure accuracy and equivalence between planning and execution. Thus, the planning center transformed the 2D project created by the dentist using his software or app into a 3D format and created guides for the prosthetic, periodontal, and orthodontic treatments. Thus, all the necessary procedures throughout the treatment could be predictable.



Figures 7a-7d: Pretreatment STL for guiding the dental preparation and the ideal posttreatment STL. Intraoral view of the dental preparation after determining the end line and conservative preparation. Intraoral scan of the preparations. Ceramic-laminated veneers in the model.

|| The use of a double technique for crown lengthening allowed references for gingival and bone reduction during surgery, and this technique was able to reduce errors and create predictable gingival and alveolar margins.²⁴ ||

Integrated Plan

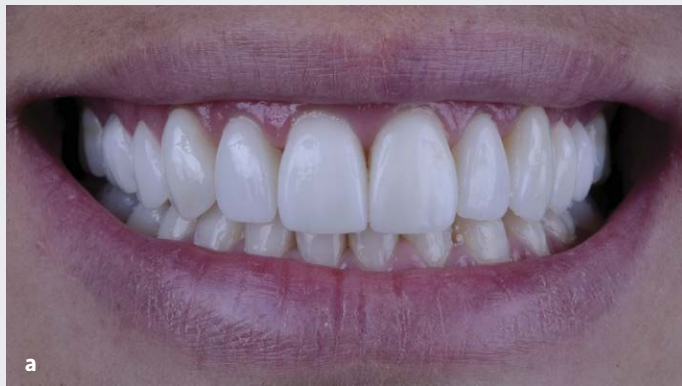The need for greater harmony and better dental esthetics in periodontal procedures commonly arises in esthetic rehabilitation.²³ The use of digital resources and planning guided by facial references and smile design were key factors in achieving this goal. The use of a double technique for crown lengthening allowed references for gingival and bone reduction during surgery, and this technique was able to reduce errors and create predictable gingival and alveolar margins.²⁴

In contrast to using only orthodontic aligners, in which the treatment is oriented only by the teeth in the arch, the integration of a DSD-Invisalign protocol allowed the orthodontist, by means of ClinCheck, to visualize the rehabilitator's esthetic planning in harmony with the patient's face. Thus, he was able to perform dental movements into ideal positions that resulted in minimally invasive preparations.

With the defined plan, a motivational mock-up could be performed to simulate the entire treatment outcome, which the patient could consider during the planning stage. This integration made it possible to predict the final result even before starting treatment. The two major technical impacts of DSD on orthodontic alignment were face-oriented orthodontic planning and interdisciplinary integration in planning. In this case, the aligners were able to safely correct the dental arches and perform movements equivalent to those that were planned. As a limitation, however, the patient had two deciduous teeth (#A and #K) that did not adequately respond to the orthodontic movement because they were ankylosed.

The entire treatment was based on DSD performed through facial analysis. Combining the technologies of DSD and ClinCheck, the orthodontic movements were performed with consideration to what the result of the treatment would be. This protocol was more predictable and led to a less invasive preparation for receiving veneers. Furthermore, using the STL model from the DSD and merging it with the DICOM file from the CBCT, it was possible to predict the crown lengthening so that the final restorations would not invade the biological space. Without these technologies, the treatment would not have been as predictable. In addition, the technologies allowed the dentists to feel more confident while performing the treatment because of the correct planning and all the guides it provided.

The favorable outcome of this treatment was directly related to the planning and execution that integrated all the specialties involved. In addition, the digital workflow was responsible for treatment predictability and accuracy.



Figures 8a & 8b: Final treatment result. Extraoral close-up frontal and full-face views of the enlarged smile resulting from the treatment.

Summary

This case report described an interdisciplinary approach using orthodontic, periodontal, and prosthetic treatment for an esthetic rehabilitation using a digital workflow. Through a fully digital, interdisciplinary, and facially guided plan integrating DSD and orthodontic aligners, it was possible to predictably obtain a final result equivalent to the planned one.

References

1. Nancarrow SA, Booth A, Ariss S, Smith T, Enderby P, Roots A. Ten principles of good interdisciplinary team work. *Hum Resour Health*. 2013 May 10;11:19.
2. Cohen M. *Interdisciplinary treatment planning, Volume II: comprehensive case studies*. Hanover Park (IL): Quintessence Pub.; 2008.
3. Hall P, Weaver L. Interdisciplinary education and teamwork: a long and winding road. *Med Educ*. 2001 Sep;35(9):867-75.
4. Jivraj S, Corrado P, Chee W. An interdisciplinary approach to treatment planning in implant dentistry. *Br Dent J*. 2007 Jan 13;202(1):11-7.
5. Coachman C, Van Dooren E, Gürel G, Landsberg CJ, Calamita MA, Bichacho N. Smile design: from digital treatment planning to clinical reality. In: Cohen M, editor. *Interdisciplinary treatment planning. Vol II. Comprehensive case studies*. Hanover Park (IL): Quintessence Pub.; 2012. p. 119-74.
6. Coachman C, Calamita MA. Digital smile design: a tool for treatment planning and communication in esthetic dentistry. *QDT* 2012. Hanover Park (IL): Quintessence Pub.; 2012. PP. 103-11.
7. Coachman C, Calamita MA, Sesma N. Dynamic documentation of the smile and the 2D/3D digital smile design process. *Int J Periodontics Restorative Dent*. 2017 Mar/Apr;37(2):183-93.
8. Gürel G. *The science and art of porcelain laminate veneers*. Hanover Park (IL): Quintessence Pub.; 2003.
9. Davis NC. Smile design. *Dent Clin North Am*. 2007 Apr;51(2):299-318, vii.
10. Spear FM, Kokich VG. A multidisciplinary approach to esthetic dentistry. *Dent Clin North Am*. 2007 Apr;51(2):487-505, x-xi.
11. Joda T, Brägger U. Digital vs. conventional implant prosthetic workflows: a cost/time analysis. *Clin Oral Implants Res*. 2015 Dec;26(12):1430-5.
12. Mühlemann S, Kraus RD, Hämmerle CHF, Thoma DS. Is the use of digital technologies for the fabrication of implant-supported reconstructions more efficient and/or more effective than conventional techniques: A systematic review. *Clin Oral Implants Res*. 2018 Oct;29 Suppl 18:184-95.
13. van Noort R. The future of dental devices is digital. *Dent Mater*. 2012 Jan;28(1):3-12.

14. Kravitz ND, Kusnoto B, BeGole E, Obrez A, Agran B. How well does Invisalign work? A prospective clinical study evaluating the efficacy of tooth movement with Invisalign. *Am J Orthod Dentofacial Orthop.* 2009 Jan;135(1):27-35.
15. Papadimitriou A, Mousoulea S, Gkantidis N, Kloukos D. Clinical effectiveness of Invisalign orthodontic treatment: a systematic review. *Prog Orthod.* 2018 Sep 28;19(1):37.
16. Sugimori T, Yamaguchi M, Shimizu M, Kikuta J, Hikida T, Hikida M, Murakami Y, Suemitsu M, Kuyama K, Kasai K. Micro-osteoperforations accelerate orthodontic tooth movement by stimulating periodontal ligament cell cycles. *Am J Orthod Dentofacial Orthop.* 2018 Dec;154(6):788-96.
17. Alikhani M, Raptis M, Zoldan B, Sangsuwon C, Lee YB, Alyami B, Corpodan C, Barrera LM, Alansari S, Khoo E, Teixeira C. Effect of micro-osteoperforations on the rate of tooth movement. *Am J Orthod Dentofacial Orthop.* 2013 Nov;144(5):639-48.
18. Murphy NC. In vivo tissue engineering for orthodontists: a modest first step. In: Davidovitch Z, Mah J, Suthanarak S, editors. *Biological mechanisms of tooth eruption, resorption, and movement: proceedings of the Eighth International Conference held at Hilton Phuket Arcadia Resort & Spa, Phuket, Thailand November 7-10, 2005.* Los Angeles (CA): University of Southern California; 2006. p.385-410.
19. Teixeira CC, Khoo E, Tran J, Chartres I, Liu Y, Thant LM, Khabensky I, Gart LP, Cisneros G, Alikhani M. Cytokine expression and accelerated tooth movement. *J Dent Res.* 2010 Oct;89(10):1135-41.
20. Polo M. Botulinum toxin type A (Botox) for the neuromuscular correction of excessive gingival display on smiling (gummy smile). *Am J Orthod Dentofacial Orthop.* 2008 Feb;133(2):195-203.
21. Lanning SK, Waldrop TC, Gunsolley JC, Maynard JG. Surgical crown lengthening: evaluation of the biological width. *J Periodontol.* 2003 Apr;74(4):468-74.
22. Coachman C, Gurel G, Calamita M, Morimoto S, Paolucci B, Sesma N. The influence of tooth color on preparation design for laminate veneers from a minimally invasive perspective: case report. *Int J Periodontics Restorative Dent.* 2014 Jul-Aug;34(4):453-9.
23. Garber DA, Salama MA. The aesthetic smile: diagnosis and treatment. *Periodontol 2000.* 1996 Jun;11:18-28.
24. Liu X, Yu J, Zhou J, Tan J. A digitally guided dual technique for both gingival and bone resection during crown lengthening surgery. *J Prosthet Dent.* 2018 Mar;119(3):345-9. **jCD**



Prof. Dr. de Liz Pocztaruk helps maintain a private practice in Porto Alegre, Brazil.



Prof. Sesma teaches at the University of São Paulo in São Paulo, Brazil.



Dr. Amorim is a master's student at the University of São Paulo, São Paulo, Brazil, and is Professor of the postgraduate program in Prosthodontics at IMED University. Dr. Amorim can be reached at karina@usp.br



Dr. Coachman is an adjunct professor at the University of Pennsylvania (Philadelphia, Pennsylvania) and coordinator of the digital dentistry postgraduate program at Avantis University in Balneario, Camboriu, Brazil. He maintains a private practice in São Paulo, Brazil, and is the founder and CEO of Digital Smile Design (Miami, Florida).

|| The bone level was defined from the future gingival level for the purpose of maintaining the biological space; thus, a digital guide for the dual technique was created for use during surgery. ||



3 Hours Credit

This Continuing Education (CE) self-instruction examination is based on the article *Interdisciplinary Treatment Planning and Digital Workflow Integrating Smile Design, and Orthodontic Aligners: A Case Report* by Professor Rafael de Liz Pocztaruk, Dr. Newton Sesma, Dr. Karina Pintaudi Amorim, and Dr. Christian Coachman. This article appears on pages 48-57. The exam is free of charge and available to AACD members only. AACD members must log onto www.aacd.com/jcdce to take the exam. Note that only Questions 1 through 5 appear in the printed and digital versions of the *JCD*; they are for readers' information only. This exercise was developed by members of the AACD's Written Examination Committee and *JCD*'s Contributing Editors.

1. What is the main advantage of using a digital smile design (DSD) protocol?

- a. Improved communication among the professional(s) involved in the treatment and the patient.
- b. Less need for radiographs during treatment.
- c. Decreased cost for the patient.
- d. Minimized need to include other dental specialists in the treatment.

2. DSD uses which of the following to guide the dental design?

- a. Study models mounted in centric relation.
- b. Radiographs combined with a full periodontal evaluation.
- c. Facial references.
- d. Evaluation of the bite and golden proportion of the anterior teeth.

3. ClinCheck software allows a dentist to predict which of the following?

- a. The magnitude of occlusal forces during chewing.
- b. Possible movement of the teeth with Invisalign aligners.
- c. The amount of preparation needed for successful restorations.
- d. The benefits of opening the bite through posterior tooth movement.

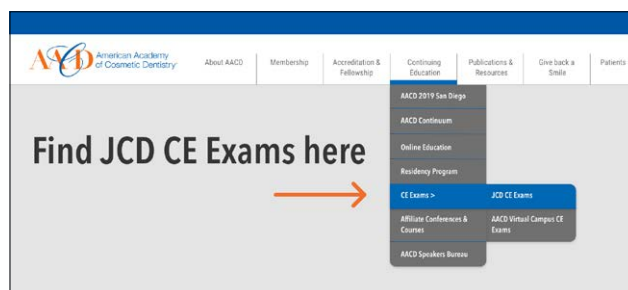
4. What is micro-osteoperforation?

- a. A sandblasting technique used during crown lengthening to soften the bone.
- b. Numerous small perforations that allow bone growth factors to be applied to thicken the bone.
- c. Bone perforations that induce inflammatory markers responsible for faster bone remodeling.
- d. When the alveolar bone is roughened during crown lengthening to improve the amount of attached tissue.

5. In the case presented, why was micro-osteoperforation completed?

- a. To improve blood flow for healthier gingival tissues after crown lengthening.
- b. To accelerate the orthodontic movement and reduce the treatment time.
- c. To thin the bone in the areas of crown lengthening.
- d. To avoid the need for crown lengthening.

To take the complete exam, log onto www.aacd.com/jcdce



AACD Self-Instruction Continuing Education Information

Exams will be available for 3 years from publication date for dentists, and 1 year from publication date for laboratory technicians.

Original release date: November 30, 2019. Expiration for dentists: November 30, 2022. Expiration for laboratory technicians: November 30, 2020.

To receive course credit, AACD members must answer at least 70% of the questions correctly.

Participants will receive test results immediately and can only take each exam once. A current web browser is necessary to complete the exam.

Verification of participation will be sent to AACD members via their MyAACD account. All participants are responsible for sending proof of earned CE credits to their state dental board or agency for licensure purposes.

For more information log onto www.aacd.com/jcdce.

Contact the AACD at email: info@aacd.com or phone: 800.543.9220 or 608.222.8583.



American Academy of Cosmetic Dentistry
Nationally Approved PACE Program
Provider for FAGD/MAGD credit.
Approval does not imply acceptance by any regulatory authority or AGD endorsement.
1/1/2019 to 12/31/2022
Provider ID# 216647



ADA CERP is a service of the American Dental Association to assist dental professionals in identifying quality providers of continuing dental education. ADA CERP does not approve or endorse individual courses or instructors, nor does it imply acceptance of credit hours by boards of dentistry. AACD designates this activity for 3 continuing education credits. Concerns or complaints about a CE provider may be directed to the provider or to ADA CERP at www.ada.org/goto/cerp.