

Case Report

The use of the digital smile design concept as an auxiliary tool in periodontal plastic surgery

Felipe Rychuv Santos^{1,2}, Stephanie Felice Kamarowski², Camilo Andres Villabona Lopez^{3,4}, Carmen Lucia Mueller Storrer^{1,2}, Alexandre Teixeira Neto¹, Tatiana Miranda Deliberador^{1,2}

¹Department of Dentistry, Positivo University, ²Department of Dentistry, SLMANDIC, Curitiba, PR, ⁴Department of Implant Dentistry, Federal University of Santa Catarina, Florianópolis, SC, Brazil, ³Department of Dentistry, Santo Tomás University, Bucaramanga, Santander, Colombia

ABSTRACT

Periodontal surgery associated with prior waxing, mock-up, and the use of digital tools to design the smile is the current trend of reverse planning in periodontal plastic surgery. The objective of this study is to report a surgical resolution of the gummy smile using a prior esthetic design with the use of digital tools. A digital smile design and mock-up were used for performing gingival recontouring surgery. The relationship between the facial and dental measures and the incisal plane with the horizontal facial plane of reference were evaluated. The relative dental height x width was measured, and the dental contour drawing was inserted. Complementary lines are drawn such as the gingival zenith, joining lines of the gingival and incisal battlements. The periodontal esthetic was improved according to the established design digital smile pattern. These results demonstrate the importance of surgical techniques and are well accepted by patients and are easy to perform for the professional. When properly planned, they provide the desired expectations. Periodontal Surgical procedures associated with the design digital smile facilitate the communication between the patient and the professional. It is, therefore, essential to demonstrate the reverse planning of the smile and periodontal parameters with approval by the patient to solve the esthetic problem.

Key Words: Dentist's practice patterns, gingiva, periodontics

Received: August 2016
Accepted: December 2016

Address for correspondence:
Dr. Tatiana Miranda
Deliberador,
Department of Dentistry,
R. Professor Pedro
Viriato Parigot de Souza,
5300 - Campo Comprido,
Curitiba, PR, Brazil.
E-mail: tdeliberador@gmail.
com

INTRODUCTION

Smile is considered essential for facial esthetics because the most important expressions of human beings are manifested through it.^[1] It is a result of the exposure of teeth and gums during the contraction of the muscle groups of the middle and lower thirds of the face and its harmony is not only determined by the shape, position and color of the teeth, but also the visible perception of the gingival tissue.^[2,3]

Digital smile design (DSD) is based on the use of high-quality digital tools, with a possible static and dynamic practice, promoting a more effective and customized treatment plan. Digital planning amplifies the diagnostic view and improves documentation and communication, both interdisciplinary as well as between the professional and patient, providing the development of a treatment plan that includes a smile

This is an open access article distributed under the terms of the Creative Commons Attribution-NonCommercial-ShareAlike 3.0 License, which allows others to remix, tweak, and build upon the work non-commercially, as long as the author is credited and the new creations are licensed under the identical terms.

For reprints contact: reprints@medknow.com

How to cite this article: Santos FR, Kamarowski SF, Lopez CA, Storrer CL, Neto AT, Deliberador TM. The use of the digital smile design concept as an auxiliary tool in periodontal plastic surgery. Dent Res J 2017;14:158-61.

Access this article online



Website: www.drj.ir
www.drjjournal.net
www.ncbi.nlm.nih.gov/pmc/journals/1480

which meets the functional, esthetic, and emotional requirements of the patient.^[4]

The aim of the present study is to report a case with a surgical resolution of a gummy smile, which had altered passive eruption of the upper arch, whose esthetic planning was carried out with the use of digital tools (DSD) and mock-up.

CASE REPORT

Female patient, 16 years of age, the American Society of Anesthesiologists I and orthodontic treatment for dental care complaining of gingival tissue upon smiling. The clinical examination revealed that, while smiling, the patient showed a visible range of gingiva contiguous with relatively small teeth [Figure 1a]. On probing the labial surface of the upper teeth, a clinical probing depth of 4 mm for the central incisors was found, 3 mm for the lateral incisors and canines and 2 mm for the first premolars.

For esthetic smile planning, the Keynote program (Apple) was used, and it took three photographs of the patient: facial photo with wide smile, facial photo at rest and intraoral photo. The interpupillary line was the first reference line used to establish the horizontal plane. After determining the horizontal line, the facial midline was designed according to the facial features such as the glabella, nose, and chin. These lines are placed in the center of the slide, forming a cross, and the photo face is

placed behind them in an esthetically harmonious position.

The goal of the digital facial arch is to find the best facial position relative to the horizon and at the same time determine the facial midline, without worrying about the position, inclination or dental midline. It takes as reference the bi-pupillary alignment, rotating the image, and having the horizontal white line as a guide. In verifying the lower face, the results of the various facial references are found [Figure 1b].

The cross is transferred to the smiling region and then to the intraoral image [Figure 1c]. Three lines are used to transfer the facial lines for the intraoral picture and calibrate: (1) from the tip of the canine to the contralateral tip of the canine; (2) the middle of the incisal edge of a central incisor to the middle of the incisal edge of the contralateral central incisor; (3) on the dental midline of the tip of the interdental papillae to the incisal.

The relationship between the facial and dental measures and the incisal plane with the horizontal facial plane of reference were evaluated [Figure 1d]. The relative dental height to width was measured, and the dental contour drawing was inserted [Figure 1e]. Complementary lines are drawn such as the gingival zenith, joining lines of the gingival and incisal battlements. Regarding the intraoral picture, the horizontal line must be moved above the gingival margin of the anterior teeth. The distance from the gingival margin of each tooth and the horizontal line is measured with a digital ruler. This sequence may be modified, decreased or adapted to different situations, depending on the individual needs of the patient.

Molding was performed with alginate of the upper arch to obtain the plaster model. These were used to conduct the wax diagnosis. There was a simulation of the smile with Bis-acrylic resin for the mock-up.

In the upper gingival recontouring surgery, the infiltrative submucosal and subperiosteal anesthesia technique was used with a 4% articaine local anesthetic base with epinephrine 1:100,000. The buccal surfaces of the teeth were probed and marked at three points, which were delineated [Figure 2a]. The incision was made with a Bard-Packer scalpel with a number 15c blade and internal bevel, directed apically. The total flap was detached with a molt peeler and dissector

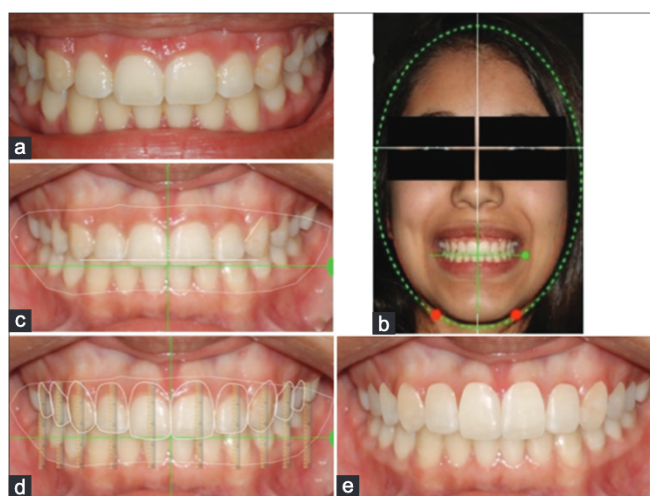


Figure 1: (a) Initial image of the smile; (b) results of diverse facial references: interpupillary line, horizontal; (c) line, facial midline and digital facial arc; (d) transfer lines and calibration; (e) dental contouring design and measures.

beyond the mucogingival junction [Figure 2b]. Intrasulcular incision with number 15 scalpel blade and removal of the gingiva band were performed, preserving the palatal papillae [Figure 2c]. There was no need for an osteotomy. The flap was repositioned and sutured with 4-0 polyglactin multifilament absorbable synthetic thread with continuous suspensory suture [Figure 2d]. The patient was treated with 500 mg amoxicillin and 2 mg betamethasone.

In the surgical procedure, the patient is oriented regarding postsurgical care and the use of mouthwash with 0.12% chlorhexidine solution - 15 ml for 60 s every 12 h for 14 days. The case monitoring was carried out for 108 days [Figure 3] after surgery.

DISCUSSION

In dentistry, esthetics is related to the harmony of the smile. Regarding the principles of the esthetic smile, in addition to factors related to the teeth, gingival factors are also considered such as color, symmetry of the gingival contour, the highest point of the marginal gingiva and the triangle papillary.^[5,6]

Proportionality between the teeth is an important factor in the appearance of the smile, and it relies on the relationship between the length and width of the teeth, as well as their position, the shape of the arch and smile configuration. Changes in the values of the width/height ratio of the teeth can even rejuvenate the look. It is also important to establish an adequate gingival contour before determining the dental proportion. On completion of the periodontal surgery, there was an improvement in the smile conformation, which improved the esthetics and dental proportion, maintaining a regular and continuous gingival contour.^[7]

Studies have reported the use of the golden ratio to establish the optimal dental composition, assisting in esthetic smile planning and establishing harmony. On the other hand, there is evidence that the use of the golden ratio between the mesial-distal widths of the upper anterior teeth should not be considered as a valid method to ensure a beautiful smile, and the dental esthetics should not be based mathematically. Esthetics are subjective and depend, in addition to the proportion of factors, the cultural characteristics, gender, body type, and age of the patient. Therefore, a personalized treatment plan and the esthetic planning of the smile are important.^[5]

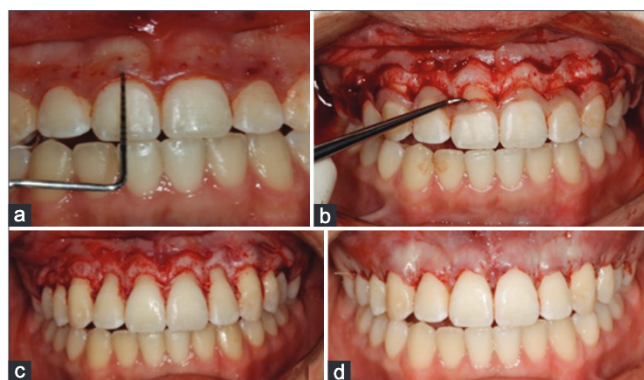

Figure 2: (a) Digital smile simulation; (b) probing and marking of points; (c) flap detachment beyond the mucogingival junction; (d) removal of the gingival band and observation of the relationship between the bone crest and cemento-enamel junction.

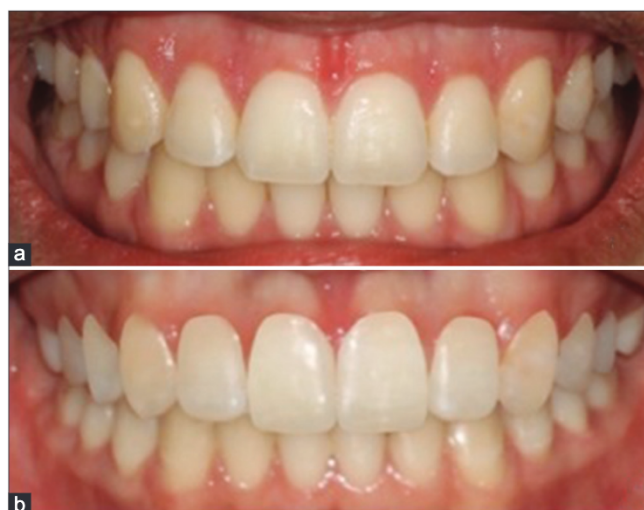

Figure 3: (a) One hundred and eight days postsurgical; (b) digital smile simulation.

The DSD enables a more complete treatment plan and concentrates on the development of the anatomical features within the given parameters. It makes it possible to view the results of the patient, demonstrating the severity of the case, treatment strategies, prognosis and recommendations, facilitating acceptance or modification. The aim of this strategy is the discussion of the case with the patient, which must be carried out according to their expectations and the feasibility of implementation. The treatment plan was shown to the patient, which met their wishes, was approved and did not require modifications.^[4,8]

Esthetic crown augmentation surgical techniques should be established according to the amount of attached gingiva and the relationship between the bone crest and cemento-enamel junction. The

gingivectomy with external bezel without a flap is used when there is an adequate quantity of attached gingiva and enough biological space between the alveolar crest and the cemento-enamel junction. When there is a narrow band of attached gingiva or the space between the bone crest is closer than 2 mm of the cemento-enamel junction, gingival flap surgery is indicated.^[9,10]

CONCLUSION

Surgical techniques are well accepted by patients and are easy to perform for the professional. When properly planned, they supply the desired expectations. The DSD was efficient, facilitating communication between the patient and professional, providing easy handling and precision. Therefore, it is essential to demonstrate the planning while containing the smile analysis and periodontal parameters, with approval by the patient to solve the esthetic problem.

Declaration of patient consent

The authors certify that they have obtained all appropriate patient consent forms. In the form the patients have given their consent for their images and other clinical information to be reported in the journal. The patients understand that their names and initials will not be published and due efforts will be made to conceal their identity, but anonymity cannot be guaranteed.

Financial support and sponsorship

Nil.

Conflicts of interest

The authors of this manuscript declare that they have no conflicts of interest, real or perceived, financial or nonfinancial in this article.

REFERENCES

1. Ishida LH, Ishida LC, Ishida J, Grynglas J, Alonso N, Ferreira MC. Myotomy of the levator labii superioris muscle and lip repositioning: A combined approach for the correction of gummy smile. *Plast Reconstr Surg* 2010;126:1014-9.
2. Gracco A, Tracey S. Botox and the gummy smile. *Prog Orthod* 2010;11:76-82.
3. Mazzuco R, Hexsel D. Gummy smile and botulinum toxin: A new approach based on the gingival exposure area. *J Am Acad Dermatol* 2010;63:1042-51.
4. Coachman C, Paravina RD. Digitally enhanced esthetic dentistry – From treatment planning to quality control. *J Esthet Restor Dent* 2016;28 Suppl 1:S3-4.
5. Mahshid M, Khoshvaghti A, Varshosaz M, Vallaei N. Evaluation of “golden proportion” in individuals with an esthetic smile. *J Esthet Restor Dent* 2004;16:185-92.
6. Levin EI. Dental esthetics and the golden proportion. *J Prosthet Dent* 1978;40:244-52.
7. Magne P, Gallucci GO, Belser UC. Anatomic crown width/length ratios of unworn and worn maxillary teeth in white subjects. *J Prosthet Dent* 2003;89:453-61.
8. Zanardi PR, Laia Rocha Zanardi R, Chaib Stegun R, Sesma N, Costa BN, Cruz Laganá D. The use of the digital smile design concept as an auxiliary tool in aesthetic rehabilitation: A case report. *Open Dent J* 2016;10:28-34.
9. Dolt AH 3rd, Robbins JW. Altered passive eruption: An etiology of short clinical crowns. *Quintessence Int* 1997;28:363-72.
10. Hopper RA, Al-Mufarrej F. Gingivoperiosteoplasty. *Clin Plast Surg* 2014;41:233-40.