

# An integrated cosmetic treatment plan: soft tissue management and metal-free restoration

Christian Coachman,<sup>1</sup> Eric Van Dooren<sup>2</sup>

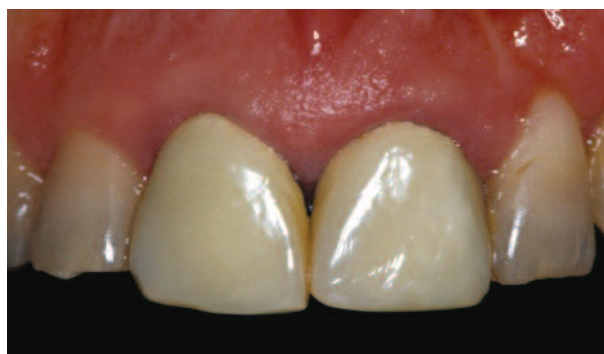Development of aesthetic restorations requires a careful, thorough, and concise team approach. The correct design of the gingival margin will significantly affect the overall appearance of the restorations, and the development of scalloped interdental papillae is equally paramount to restorative success. Tooth morphology can only be re-established in a natural way when the soft tissue is compatible with aesthetic principles.

Additional considerations that must be addressed during restorative fabrication include incisal edge position and development of an accurate shade match with the surrounding dentition. Thorough communication is, therefore, critical between the laboratory technician and the clinician in order to ensure development of a concise treatment plan that includes proper material selection, laboratory design, and clinical execution.

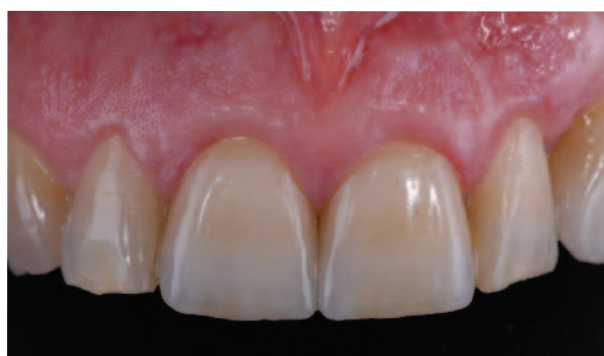## Case Presentation

A 46-year-old male patient desired an improved tooth proportion in the anterior region. The treatment plan consisted of surgical repositioning of the gingival margin and the zenith of each anterior crown, followed by crown lengthening on the teeth that required apical movement of the zenith (ie, teeth #12, #11 and #21). A connective tissue graft was required for tooth #23 to cover the root exposure and improve the length-to-width ratio.

Metal-free restorations were selected to enhance the light dynamics of the crown, but also of the gingival margin area. By providing ideal light circulation among the cervical of the



*Figure 1a: Preoperative view. Note the incorrect width-to-length ration and unaesthetic soft tissue integration.*

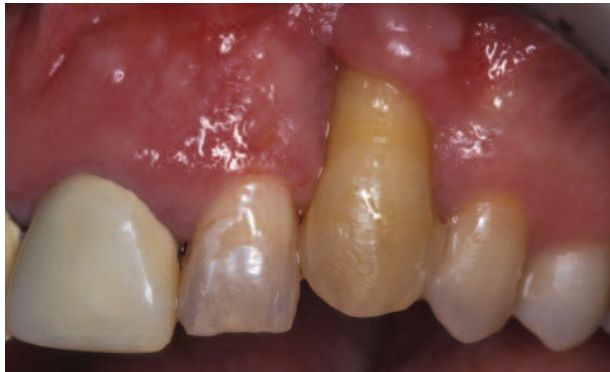

*Figure 1b: Postoperative appearance demonstrates optimal emergence profiles and significantly improved aesthetic ratios.*

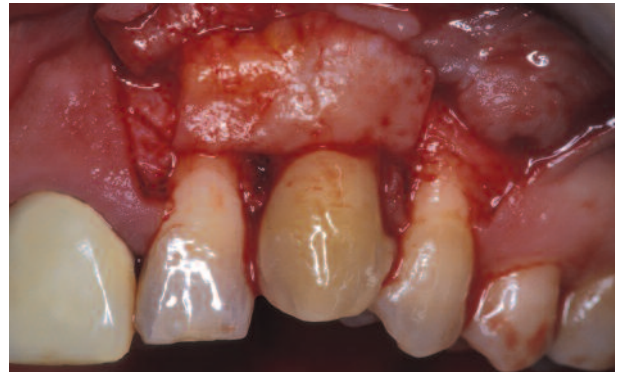crown, the underlying dentin, the root, and the gingival margin, all-ceramic restorations would allow natural shade transmission to the gingiva in this key area for the final aesthetic outcome.

<sup>1</sup> DMD. Private Practice, São Paulo-SP, Brazil

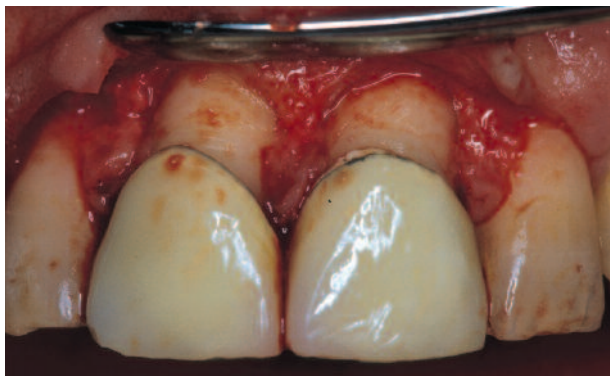<sup>2</sup> DMD. Private practice, Antwerpen, Belgium



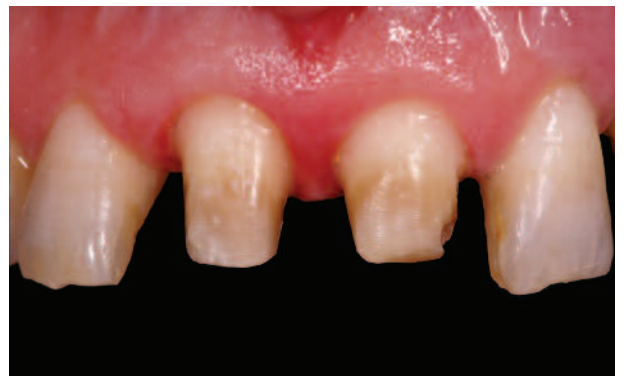2a



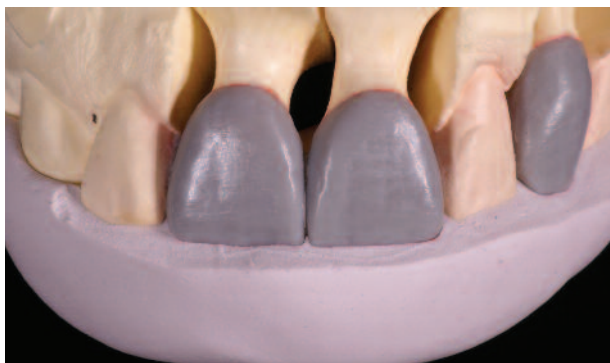2b



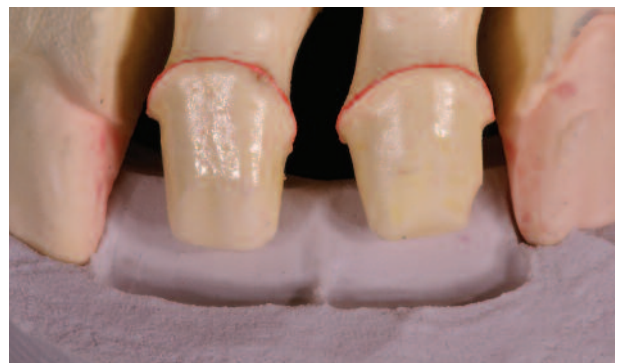3a



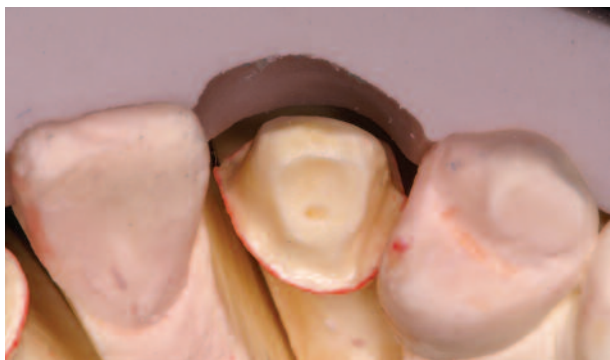3b



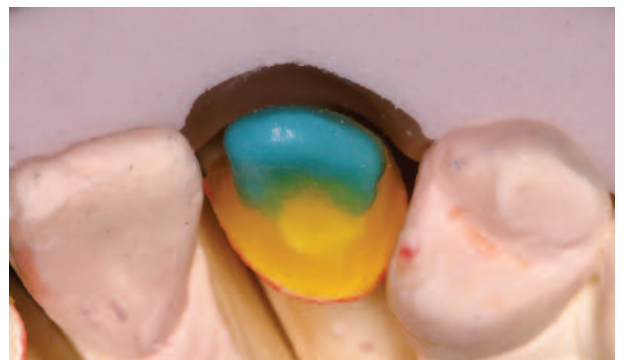4a



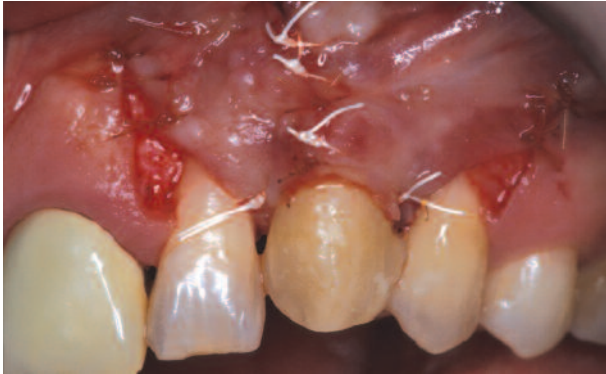4b



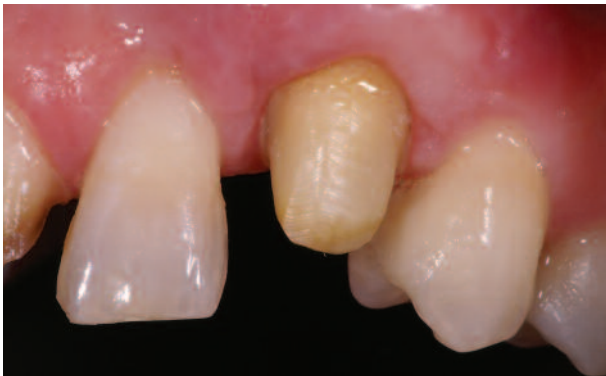5a



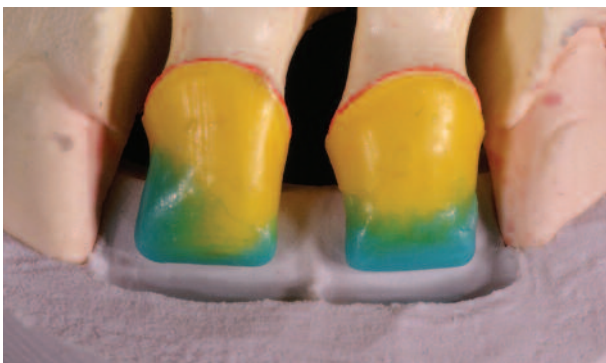5b



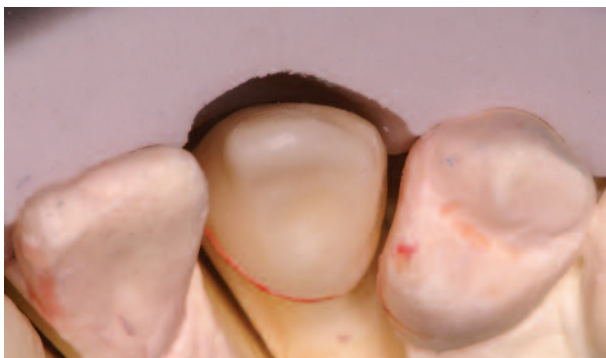2c



3c



4c



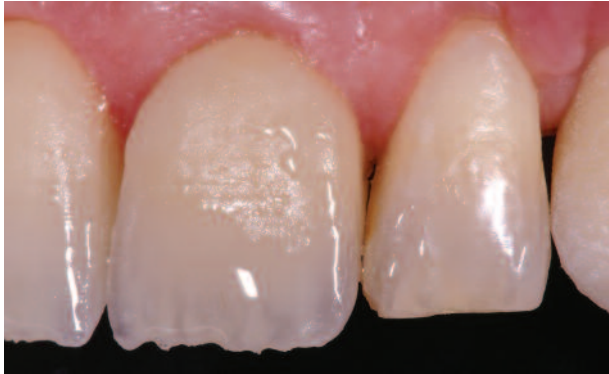5c

**Figures 2A,B,C.** Initial evaluation demonstrated that the patient's dentition were incorrectly aligned, and an unaesthetic width-to-length ratio was evidenced on teeth #12, #11, and #21. Although an improved proportion was evident on tooth #22, extensive buccal recession was present on tooth #23. Periodontal plastic surgery was, therefore, required for tooth #23 to provide improved gingival harmony. The root surface was conditioned using a scaling and citric acid material, and a split-thickness incision was placed, combined with a distal and mesial releasing incision. A connective tissue graft was harvested from the palatal area and secured to the receptor bed. Coverage of the grafted area was obtained by approximating the mesial and distal pedicle.

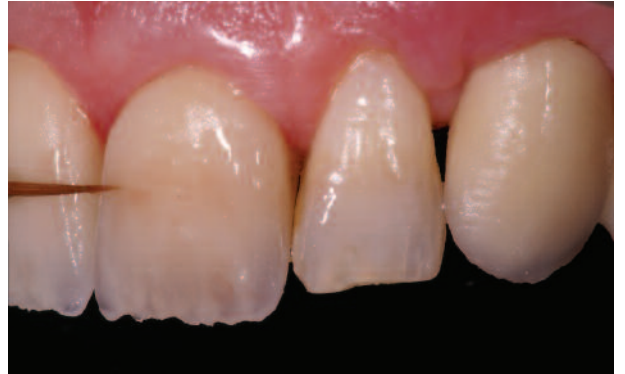**Figures 3A,B,C.** Crown lengthening procedures were subsequently initiated on teeth #21, #11, and #12 to ensure optimal gingival resection in the anterior region. Osseous recontouring was also required to facilitate development of a natural emergence profile. Once the surgical procedures were completed, the gingival region was allowed to heal for 6 weeks in order to ensure optimal gingival design. Tooth proportions were reevaluated at this time and tooth preparation was performed once soft tissue healing was confirmed.

**Figures 4A,B,C.** A diagnostic waxup was created to evaluate the desired crown length and contours, and a silicone index was fabricated based on the waxup to guide the production of the alumina frameworks and the ceramic build-up. The silicone index was used to evaluate the tooth preparation on the working model; the framework waxup and the final alumina copings were also evaluated. The coping design was completed using a CAD/CAM System (Nobel Procera Forte, Nobel Biocare, Yorba Linda, CA) to support the overlying ceramic correctly.

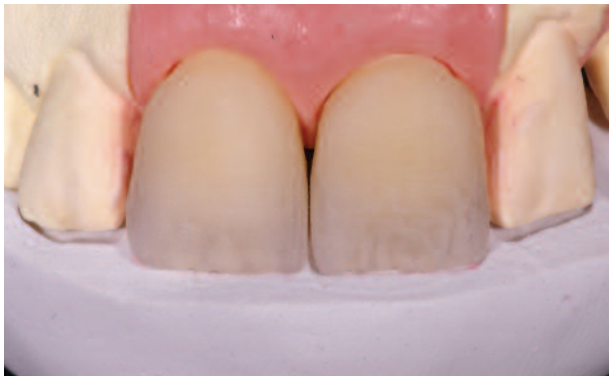**Figures 5A,B,C.** An interproximal and palatal collar was placed to improve ceramic support and avoid crack formation and chipping of the definitive restoration. The copings were evaluated from the occlusal aspect to ensure development of the precise marginal fit for the CAD/CAM restorations. Subsequent porcelain layering was commenced when the fit of the copings was verified by the laboratory technician.



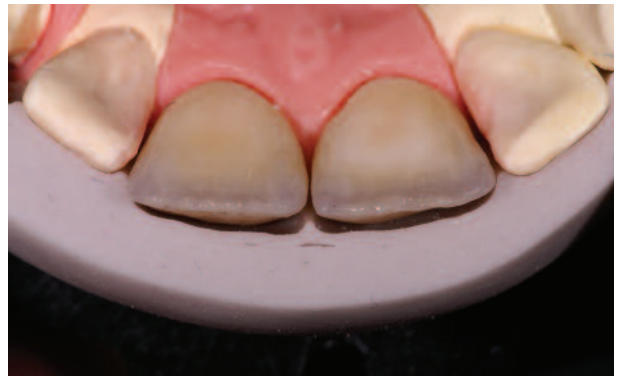6a



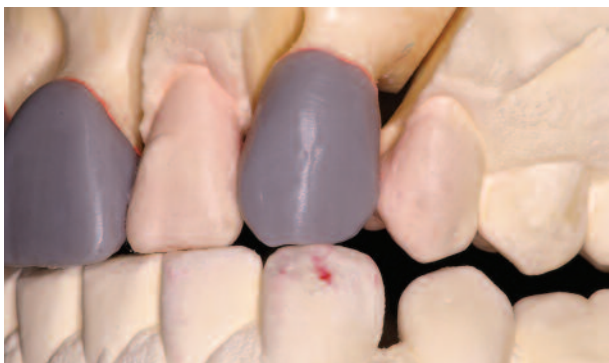6b



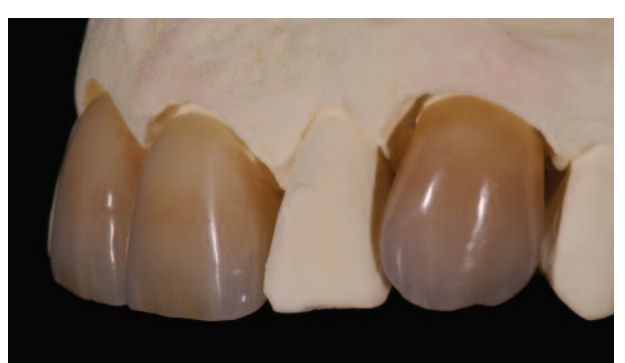7a



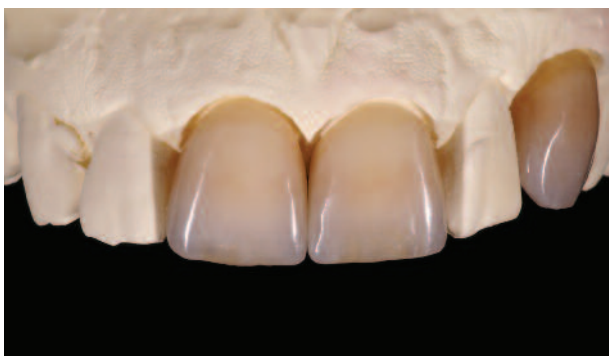7b



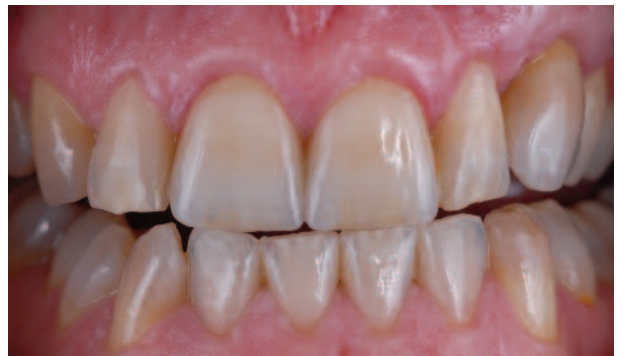8a



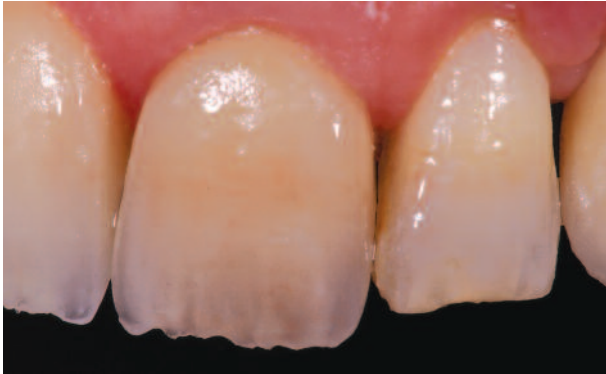8b



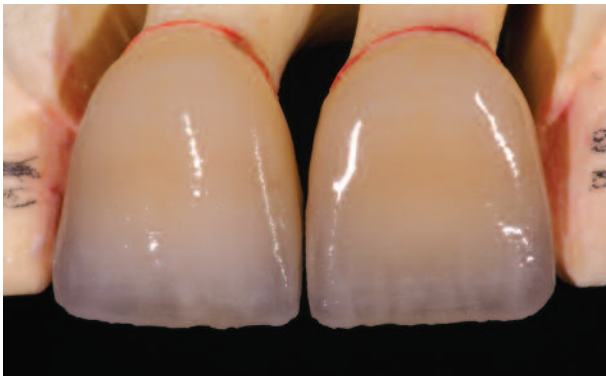
9a



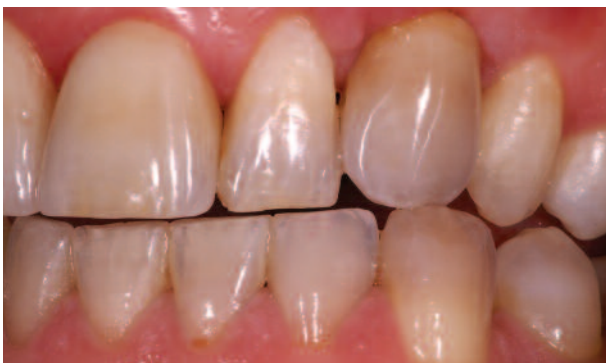9b



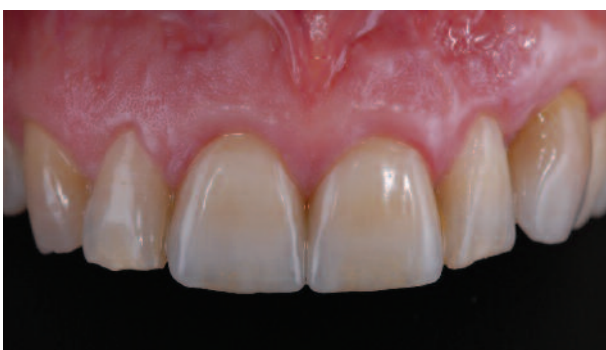6c



7c



8c



9c

**Figures 6A,B,C.** Initial shade mapping was performed and accompanied by a full photographic series to ensure precise shade communication. The ceramics were layered and fired prior to initial try-in. The restoration was evaluated adjacent to the natural dentition to determine what shade nuances were required to ensure seamless integration and match with the surrounding dentition prior to the second bake. Intraoral staining was performed to enable precise characterization that matched the adjacent structures. In this case, a brown strip was required in the center of the buccal surface and caramel stain was applied on the incisal edge.

**Figures 7A,B,C.** Care was taken by the laboratory technician to control the shrinkage of the first bake to allow the internal staining to be covered by the ideal thickness of the second bake. The incisal edges were maintained slightly longer than the final length and the buccal surface was 0.5 mm smaller than the final shape. The stains were baked 100°C lower than the dentin bake, which was sufficient temperature to stabilize it before adding the second ceramic build up.

**Figures 8A,B,C.** The try-in of the second bake demonstrated an aesthetic shade match and a nice blend of the internal staining. Functional occlusal adjustments were made and centric relation and excursion movements were evaluated. Care was taken to ensure that the lateral, lateral-protrusive, and protrusive movements were in accordance with functional guidelines. The shape of the canine was first planned on the waxup to create a canine guidance without interference of the posteriors and anterior teeth. The lateral-protrusive movement demonstrated simultaneous canine, lateral, and central contact. The shape of the incisal of the canine ceramic crown was designed to engage the incisal of the mandibular canine when they were in contact during canine guidance, giving the ceramic crown a natural wear facet appearance.

**Figures 9A,B,C.** The crowns were glazed and hand polished to ensure development of a natural lustre and texture. The soft tissue integration around the canine was evaluated to ensure success of the grafting procedure. Soft tissue long-term health and stability was confirmed by the aesthetic emergence profile of the crowns, giving the gingival margin and papillae the ideal support. A considerable improvement was evident in the aesthetics of the soft tissue and gingival margin design. The improved proportion and color matching of the crowns were also visible.

*Address correspondence to: Eric Van Dooren, DDS, Tandartsenpraktijk Tavernierkaai Tavernierkaai, 2, 2000 Antwerpen, Belgium*

*Tel: + 32-3-830-1221 • E-mail: vandoorendent@skynet.be*